



SUMATRAN RHINOCEROS
Reproductive Data
1991-1999

Report to Asian Rhino Specialist Group and the
Taxon Advisory Group, Fall 1999

Nan Schaffer, DVM

Author Note:

The original document "Sumatran Rhinoceros Reproductive Data 1991-- 1999" was presented to a meeting of the Asian Rhino Specialist Group (ARSG) in the fall of 1999 and distributed to members in 2000. In the following years copies were provided to several researchers involved in analysis of reproductive problems in the Sumatran rhino. The information has been periodically updated with new information (Addenda) and the author encourages any additions or clarifications to be contributed. To make the information readily accessible it is available on the Rhinoceros Resource Center (www.rhinoresourcecenter.com).

CONTENTS

I. Report to Asian Rhino Specialist Group and the Taxon Advisory Group, Fall 1999 Nan Schaffer	5
II. Reproductive analyses, reports and ultrasound images	8
A. Sungai Dusun, Peninsular Malaysia	8
1. Jeram, female, St. 1, Sungai Dusun (N.Schaffer,1991)	9
2. Panjang, female, St. 13, Sungai Dusun (N.Schaffer,1991,.1992)	10
3. Mas Merah, female, St. 19, Sungai Dusun (N.Schaffer,1991,.1992,.1998)	12
4. Seputih, female, St. 23, Sungai Dusun (N.Schaffer,1992,.1998)	14
5. Shah, male, St. 20, Sungai Dusun (N.Schaffer,1992)	16
B. Sepilok, Sabah, Malaysia	18
1. Gologob, female, St.40, Sepilok (N.Schaffer,1998)	19
2. Lun Parai, female, St.26, Sepilok (N.Schaffer,1998)	21
3. Tanjung, male, St.38, Sepilok (N.Schaffer,1998)	23
4. Postmortems (Addenda post 1999)	
a. Postmortem of Lun Parai (N.Schaffer,2000)	26
b. Postmortem of Tanjung (N.Schaffer,2006)	27
C. Sumatran Rhino Sanctuary, Way Kambas, Sumatra, Indonesia	33
1. Bina, female, St.32, Way Kambas (N.Schaffer,1999)	34
2. Dusun, female, St.12, Way Kambas (N.Schaffer,1999)	36
Addenda to Dusun exam:	
a. Dusun Diagnostic Plan and Report to Nico van Strien, Way Kambas (Nan Schaffer and Annelisa Kilbourn, 2000)	38
b. Prolactin levels (J.Brown,1999)	40
c. Serology (N.Schaffer,1999)	40
d. Fecal E2 and Progestin (M. Agil, 1999)	40
e. Necropsy of Dusun (Bambang Pontio Priosoeryanto, 2001)	41
3. Torgamba, male, St.4, Way Kambas (N.Schaffer,1999)	42
D. Taman Safari, Bogor, Indonesia (examinations 1999)	43
1. Dalu, female, St.22, Taman Safari (N.Schaffer,1995)	
a. Postmortem (Nan Schaffer,1999)	43
b. Histology report (J.Kinsel,1999)	46
2. Romi, male, St.30, Taman Safari (N.Schaffer,1995)	48
E. Cincinnati Zoo	48
1. Rapunzel, female, St.27, Cincinnati Zoo.(N.Schaffer,1995)	48
2. Bagus / Ipuh, male, St. 28, Cincinnati Zoo.(N.Schaffer,1995)	50
3. Ultrasound and penile massage procedures	51

CONTENTS,
continued

III. Addenda Reports 2000-2006	59
1. Sabah: Poached Female Rhino (N. Schaffer, A. Kilborne, 2001)	60
2. San Diego Zoo Necropsies:	
a. Barakas, female, St. 25, San Diego Zoo (L. Lowenstine, 1995)	62
b. Rami, female, St.33,	
i. Necropsy, San Diego Zoo (B.Rideout, 1992)	72
ii. ART (R. Pope, 1992)	78
3. Treatment bases for Leiomyoma (J.C.M. Tisbris, 2000)	79
4. Necropsy for Dusun (Priosoeryanto and Agungpriyono, 2001)	80

Key: (examiner, year of exam)

I. REPORT TO ASRSG & TAG (FALL 1999)

Report to Asian Rhino Specialist Group and the Taxon Advisory Group, Fall 1999

Nan Schaffer, DVM

Sumatran rhinoceros reproductive biology is complicated and has contributed to the failure of this species to flourish in standard captive breeding facilities. The inability to identify estrus has led to aggressive confrontations between males and females. Breeding proficiency has been compromised. Since the Sumatran rhinoceros entered captivity in the 1980's, only attempts at breeding were reported (Zainal et al. 1990) and successful copulations remained non-productive (Bosi et al. 1995). A few years later, after a more detailed monitoring of breeding of their captive animals, the Cincinnati Zoo confirmed a pregnancy.

Defining the unique reproductive biology of this species has been protracted. Early studies were limited by lack of reproductively active representatives of the species and useful methodologies. This author first demonstrated the effectiveness of ultrasonography in this species in the early 1990's, but it was not used extensively until recently (Schaffer, et al. 1994). Since then several researchers have pursued endocrine investigations, but the reproductive cycle of this species was not reported until last year (Heistermann, et al. 1998). Research at the Cincinnati Zoo has recently characterized early pregnancy and has indicated that this female is ovulating in response to breeding (induced ovulation) (Roth et al, 1998). These few recent studies are just beginning to unravel the unique biology of this poorly understood species.

Other recent findings demonstrate how little is known about Sumatran rhinoceros biology. These include the chronic, 8-year-long lactation of one female and the unusual occurrence of the multiple corpora lutea (CL) on the ovaries of a preserved reproductive tract. Our lack of knowledge about this species prevents us from determining whether multiple CL are a normal occurrence, or are related to an unusual hormonal imbalance. Clearly, defining their unique biology will take extensive investigation. Unfortunately, many individuals in the captive population appear to be reproductively compromised. The breedings in 1995 and the subsequent quadruple pregnancies in the female at the Cincinnati Zoo failed to produce offspring. This author has observed with ultrasonography or on postmortem reports sixteen of the twenty-two animals entering captivity since 1984, of these sixteen more than 50% exhibited uterine pathology (Table 1 below). Such pathology appears to begin after 10 years of age, assuming these animals were mature when captured, and becomes quite prevalent in animals over 15 years old. Distressingly, most remaining captive animals are representatives of this older age group. Of these sixteen females, seven are copulating. Three of these have no pathology, but are not conceiving. The other four are breeding with mild to significant pathology, which will contribute to conception difficulties. Treating these apparently chronic conditions will be challenging. Potentially, like the mare, they may be able to maintain pregnancy in mild cases of uterine pathology given optimal conditions.

The captive males present a more viable prognosis. Though only one of four breeding males is, known to produce pregnancies, all but one have demonstrated the production of sperm (Table 2 below). One male is experiencing problems with intromission, possibly due to capture at a young age, which may correct over time. Another is persistently violent toward

other Sumatran rhinos, which may also be attributable to age at capture. These behavioral hurdles may be resolved by increasing appropriate breeding opportunities. Reports of successful copulations have increased in animals intensely monitored and among animals in range states that have been moved to large fenced sanctuaries. For this reproductively challenged population, optimizing the environment and increasing the breeding opportunity will be a necessity.

References:

- Bosi, E.J. 1995. Breeding programmed of Sumatran rhinoceros (*Dicerorhinus sumatrensis*) at Sepilok Rhino Breeding Centre. Proceedings of Malaysian Rhino PHVA Sandakan Sabah, Malaysia. 7pp.
- Heistermann, M., Agil, M., Buthe, A., and J.K. Hodges. 1998. Metabolism and excretion of oestradiol-17B and progesterone in the Sumatran rhinoceros (*Dicerorhinus sumatrensis*). *Animal Reproduction Science* 53: 157-172.
- Roth, T.L., M.A. McRae, J.L. Brown, J.L., Kroll, A.C. Bellem, J.K. O'Brien and J.S. Romo. 1998. The reproductive physiology of a living fossil-the Sumatran rhinoceros (*Dicerorhinus sumatrensis*). *Biology of Reproduction* 58 (Suppl. 1): 176.
- Schaffer, N.E., Zainuddin, Z.Z., Suri, M.S.M., Jainudeen, M.R., and R. S. Jeyendran. 1994. Ultrasonography of the reproductive anatomy in the Sumatran rhinoceros (*Dicerorhinus sumatrensis*). *Journal of Zoo and Wildlife Medicine* 25 (3): 337-348.
- Zainuddin, Z.Z., Abdullah, Mohd. T. and Suri, M.S.M. 1990. The husbandry and veterinary care of captive Sumatran rhinoceros at Zoo Melaka, Malaysia. *Malayan Nature Journal* 44: 1-19.

*Studbook #	Name	Location	Country	^^Years in Captivity	Copulation	Pathology	Comments
10	Subur	Lympne	UK	1	No	Yes	**Uterine Leiomyoma
33	Rami	San Diego	USA	1	—	—	Histology Pending / San Diego Zoo
24	Mahato	Cincinnati	USA	4	—	—	Histology Pending / UI Foley
23	Seputih	Sungai Dusun	Malaysia	4	Yes	Yes	1992 Ultrasound: Uterine Cysts
22	Dalu	Taman Safari	Indonesia	5	—	Yes	Multiple Corpus Luteum, Large Uterus
13	Panjang	Sungai Dusun	Malaysia	5	Yes	No	1992 Ultrasound
40	Gologob	Sepilok	Malaysia	5	Yes	Yes	1998 Ultrasound: Few Uterine Cysts
19	Mas Merah	Sungai Dusun	Malaysia	5	No	Yes	1992 Ultrasound: Uterine Tumors, Cysts
25	Barakas	San Diego	USA	6	—	Yes	Cystic Endometrial Hyperplasia
18	Meranti	Lympne	UK	7	No	Yes	***Uterine Leiomyoma
1	Jeram	Sungai Dusun	Malaysia	7	No	Yes	1992 Ultrasound: Uterine Tumors, Cysts
29	Emi	Cincinnati	USA	8	No	Yes	1995 Ultrasound
32	Bina	Way Kambas	Indonesia	8	Yes	No	1999 Ultrasound
26	Lun Parai	Sepilok	Malaysia	10	Yes	Yes	1998 Ultrasound: Uterine Tumors, Cysts
27	Rapunzel	Cincinnati	USA	10	No	Yes	1994 Ultrasound: Uterine Tumors, Cysts
12	Dusun	Way Kambas	Indonesia	14	Yes	Yes	1998 Ultrasound: Chronic Lactation

* Foose, T. Sumatran Rhino Studbook 1999

** Furely, C. W., 1993. The clinical history of the adult female Sumatran rhinoceros called "Subur" in captivity in Sumatra and at Port Lympne Zoo, Kent, Great Britain. In Ryder, O. Rhinoceros Biology and Conservation: Proceedings of an international conference, San Diego, San Diego Zoological Society. 357-366.

*** Luff, A., 1995. Rhinos and hoof stock. Newsletter, Port 1995:29-30.

*Studbook #	Name	Location	Country	Volume	Motility	Total Sperm Count	Abnormal Sperm
20	Shah	Sungai Dusun	Malaysia	0.25 ml	50%	475,000	71%
28	^ Ipuh	Cincinnati	USA	1.1 ml	0%	3	—
38	^^ Tanjung	Sepilok	Malaysia	35 ml	—	—	—
4	Torgamba	Way Kambas	Indonesia	9	0%	4	—

* Foose, T. Sumatran Rhino Studbook 1999

^ Three semen samples were obtained via 25 attempts over a period of 42 days. The value reflects the sample with the highest quality.

^^ Three semen samples were obtained via 3 attempts over a period of 4 days. The value reflects the sample with the highest quality.

II. REPRODUCTIVE ANALYSES, REPORTS & ULTRASOUND IMAGES

The following reports include ultrasound images, descriptions of the use of ultrasonography of individuals and if available, histopathology reports and images of gross pathology of Sumatran rhinos held in captive breeding centers located in Indonesia, Malaysia, the United Kingdom and the United States. The myriad of symptoms presented require further definition and epidemiological analysis:

Terms:

Copulation Failure: Male fails to mount or fails at intromission

Pregnancy Failure: Female breeds, but fails to produce offspring, pregnancy is unknown

Pregnancy Loss: Female becomes pregnant, but fails to maintain pregnancy

Reproductive Pathology: Mild to severe lesions associated with reproductive tract

A. Sungai Dusun, Peninsular Malaysia (Examined: 1991—1992) Report to Malaysia Wildlife Department (PERHILITAN)

Nan Schaffer, DVM

Name Sex Studbook	Sex	Studbook #	Exam Years	Alternate IDs*
Mas Merah	Female	19	1991, 1992, 1998	F1, ZM11
Seputih	Female	23	1991, 1992, 1998	F3, ZM13
Panjang	Female	13	1991, 1992	F4, ZM8
Jeram	Female	1	1991, 1992	F2, ZM1
Shah	Male	20	1992	ZM12

*Note: In addition to Studbook Numbers, the authors and the Malaysian Wildlife Department used additional unique codes to identify individual animals throughout their research. Such "Alternate IDs" are presented here for reference: F = Schaffer, N.E., et. al (1994); ZM = Zainuddin, Z.Z., Thesis (1995).

Analyses

Ultrasound Images:

Methods: ALOKA 210 Scanner, 5.0 MHz Probe

Personnel: Schaffer, N.E; Zainuddin, Z.Z.; Adi, Muhammad

1991-1992 Exams: presented in Schaffer, N.E., et al (1994) referenced below.

1998 Exams: Assessment based on review of VHS tapes recorded by Adi, M. Select images are presented below for Mas Merah and Seputih.

Summary Report: Published as: Schaffer, N.E., Zainuddin, Z.Z., Suri, M.S.M., Jainudeen, M.R., and R. S. Jeyendran. 1994. Ultrasonography of the reproductive anatomy in the Sumatran Rhinoceros (*Dicerorhinus sumatrensis*). *Journal of Wildlife Medicine* 25 (3): 337-348.

Unfortunately prints for publication from 1991 and 1992 exams had to be made from a VHS copy of the original record, because the original record was not provided for publication.

Images

1. Jeram (1992)
2. Panjang (1991,1992)
3. Mas Merah (1991,1992, 1998)
4. Seputih (1992, 1998)
5. Shah (1992)

1. Jeram: 1992 - had several tumors (Figs.1,2 arrows), one centrally anechoic (Fig. 2), and many endometrial cysts (Figs.1,3). Her right ovary had only 1 intermediate follicle and the other had a large follicle (31mm) with smaller one alongside (Fig. 4).

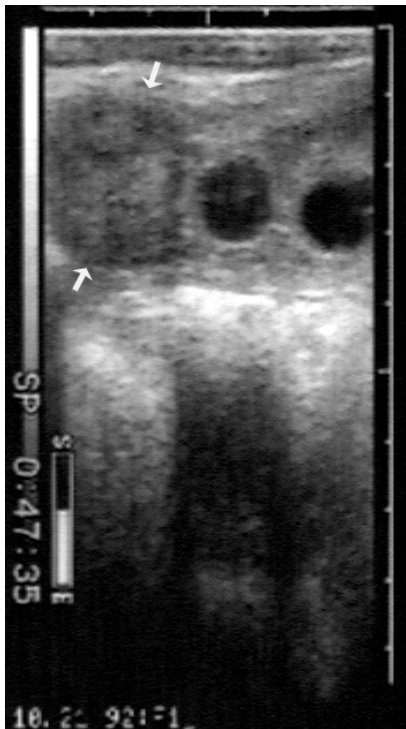


Figure 1 Oct. 1992

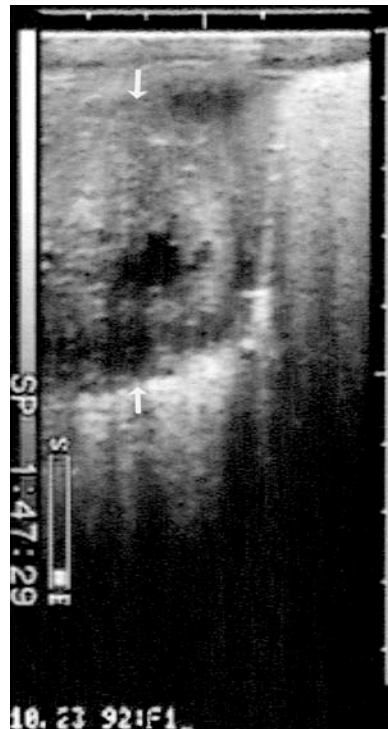


Figure 2 Oct. 1992

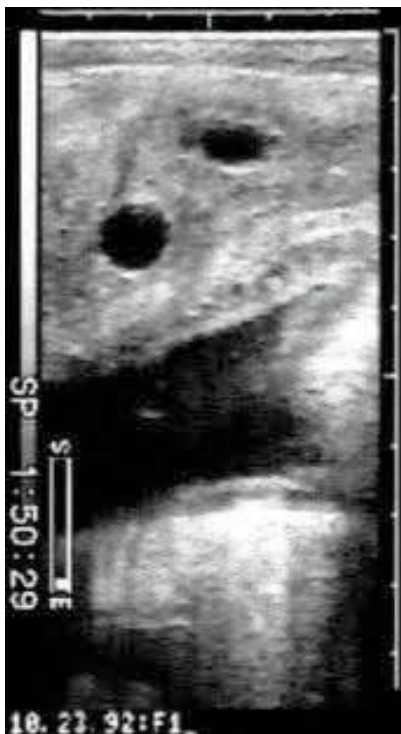

Figure 3 Oct. 1992

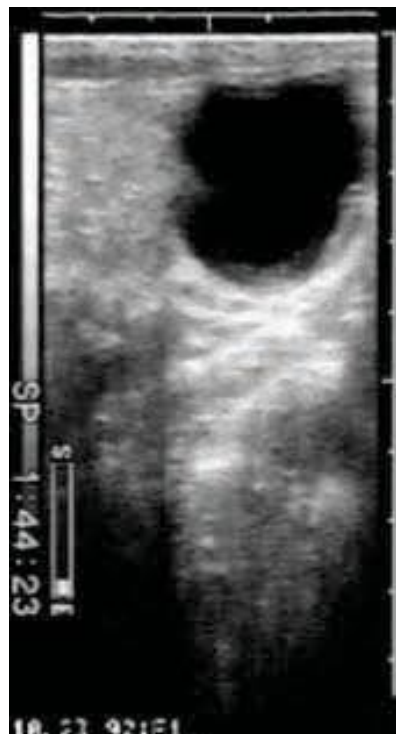

Figure 4 Large Follicle Oct. 1992

2. Panjang: Examinations were in 1991 and 1992. Figs. 1 and 2 show caudal and cranial uterine cross-sections (arrows). The uterine body cross-section (Fig. 3) appeared to have small tumors, cysts and some fluid (arrows).

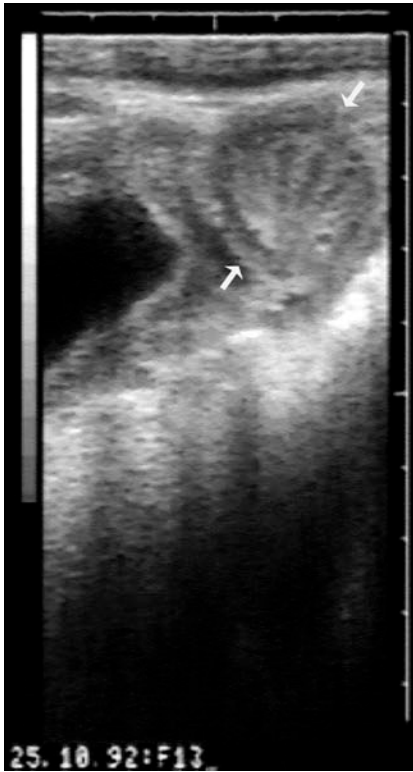


Figure 1 Caudal uterus Oct. 25, 1992

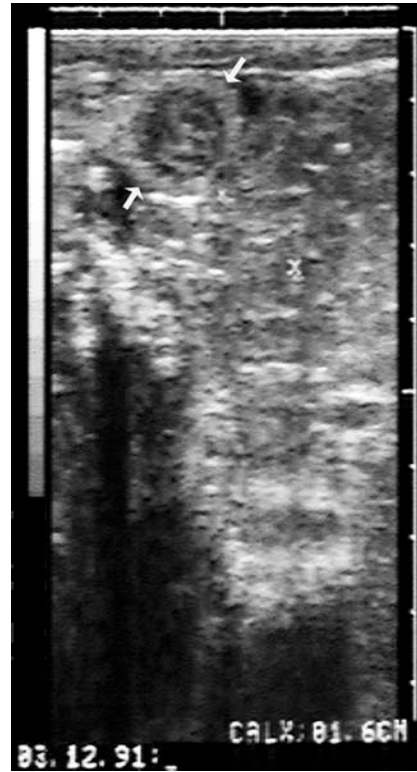


Figure 2 Cranial uterus Nov.3, 1992

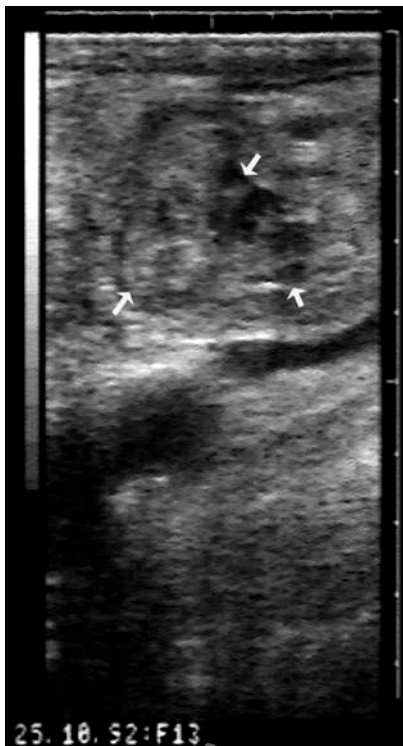

Figure 3 Body Oct. 25, 1992

Panjang (con't) Her ovaries appeared normal with variously sized numerous follicles in 1991 and 1992 (Figs. 4, 5, 7) and corpus luteum (Fig. 6 arrows).

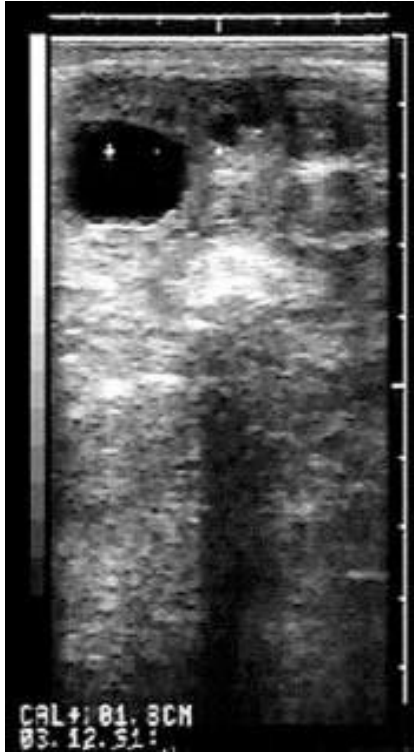


Figure 4 Rt. Ovary Nov. 3, 1991

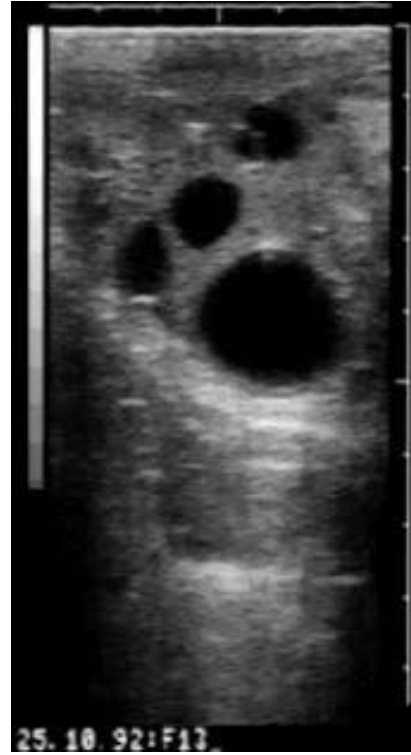

Figure 5 Lt. Ovary Oct. 25, 1992

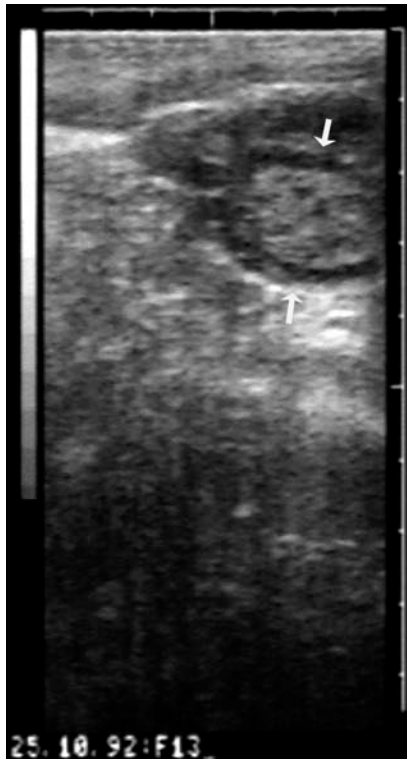

Figure 6 Rt. Ovary CL Oct, 25, 1992

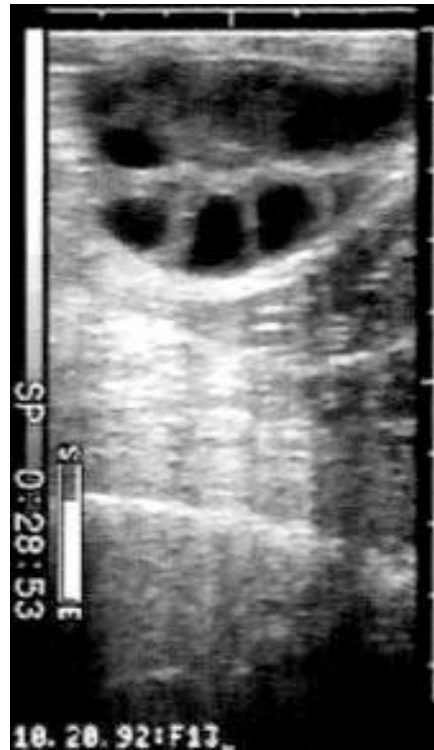

Figure 7 Rt. Ovary Oct. 20, 1992

3. Mas Merah: From observations in 1991 and 1992, she had an endometrial cysts (Fig. 1). Cysts became more numerous and enlarged by 1998 (Fig. 2 via VHS tape). Two small endometrial tumors (Figs. 3, 4 arrows) in 1991 and 1992 had changed very little by 1998.

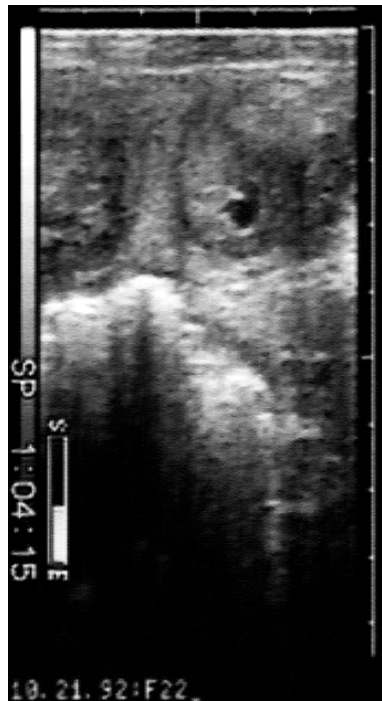


Figure 1 Oct. 21, 1992

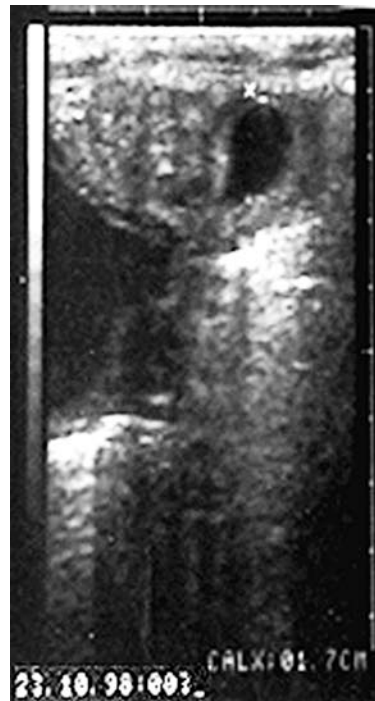

Figure 2 VHS 1998

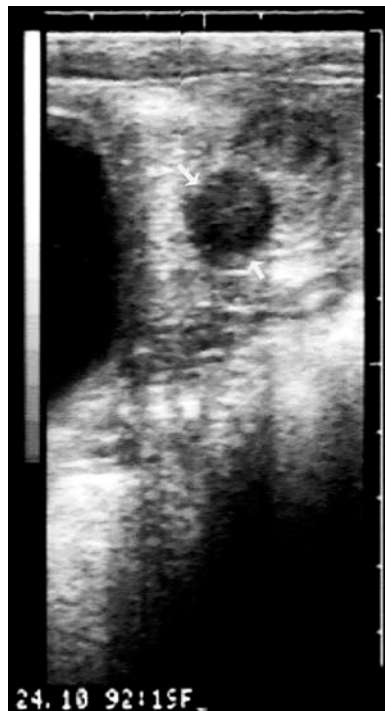

Figure 3 Oct. 24, 1992

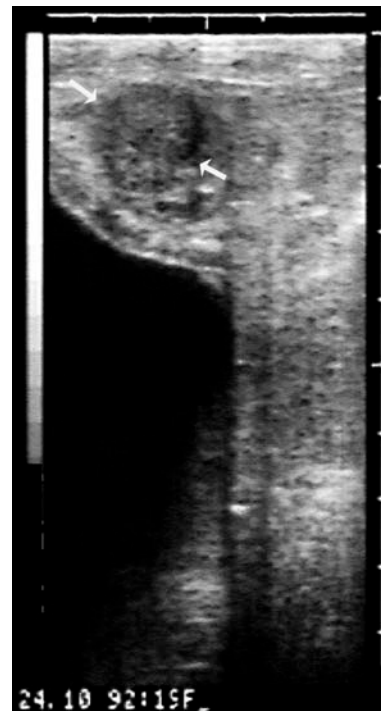


Figure 4 Oct. 24, 1992

F1 Mas Merah (con't): She had some large and intermediate follicles in 1991 and 1992 (Figs. 5, 7) and possible corpus luteum (Fig. 6 arrows) on her right ovary. No ovaries were noted on 1998 VHS tapes.

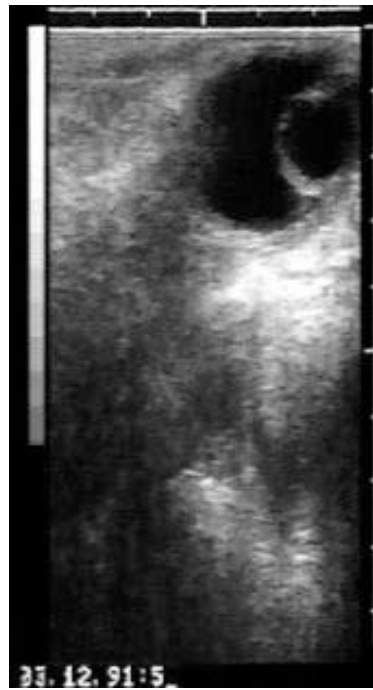

Figure 5. Lt O Nov. 3, 1991

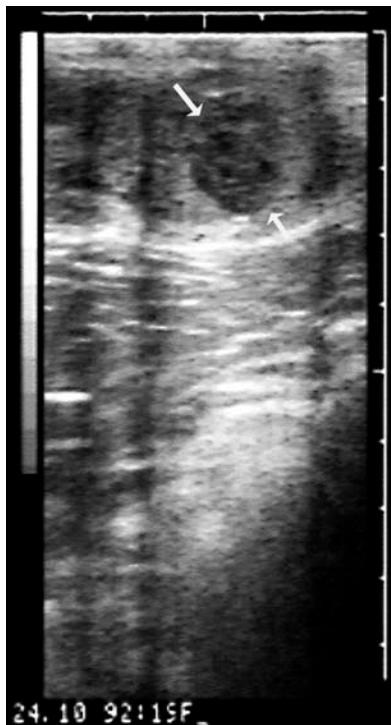


Figure 6. CL Rt Oct. 24,1992

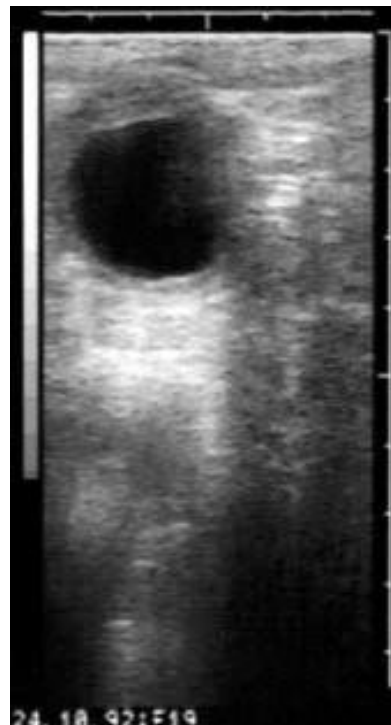


Figure 7. Lt O Oct. 24,1992

4. Seputih: In 1992, she had a few small endometrial tumors and cysts (Fig. 1, 2, arrows). By 1998, she had several large tumors, in the pelvic area of vagina and uterus (Fig. 3, 4, arrows).

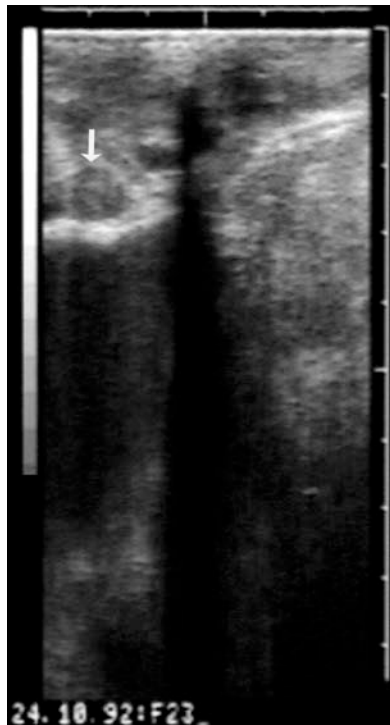


Figure 1 Oct. 24, 1992

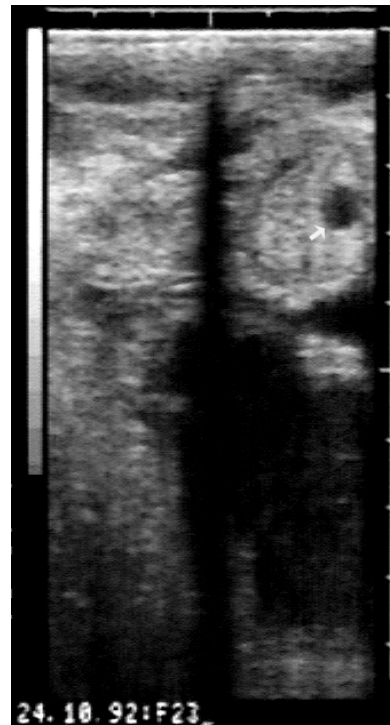


Figure 2 Oct. 24, 1992

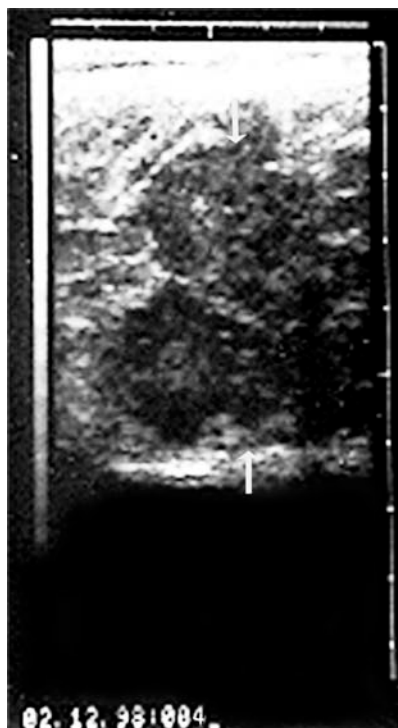

Figure 3 Dec. 2, 1998

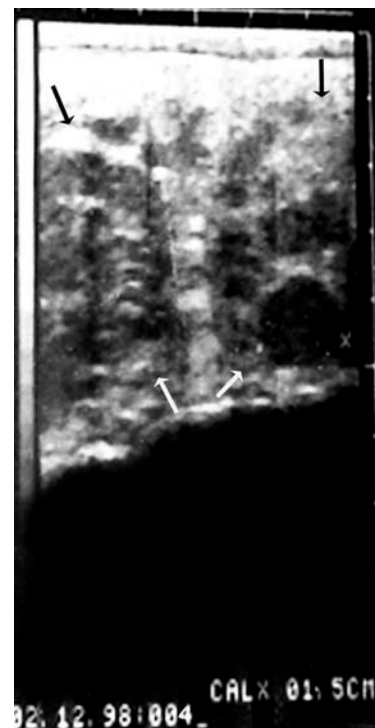

Figure 4 Dec. 2, 1998

Seputih (con't) Some follicle development on her right ovary one at 29 mm (Fig. 5, 6), left ovary was very quiet (Fig. 7). Her ovaries did not appear on VSH tape from 1998.

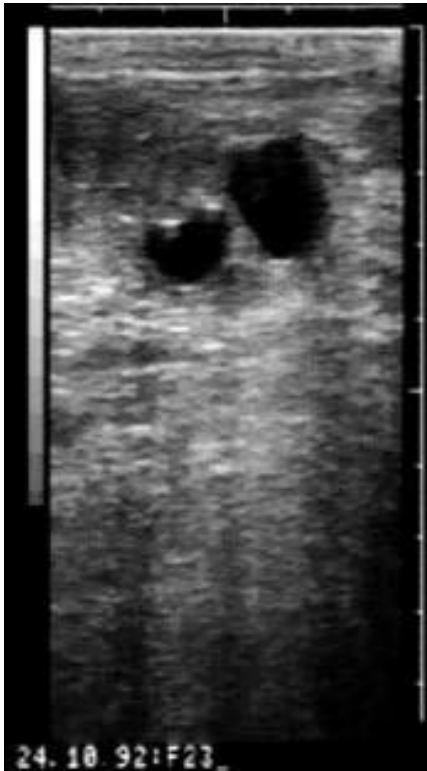

Figure 5 Rt. Ovary Oct. 24,1992

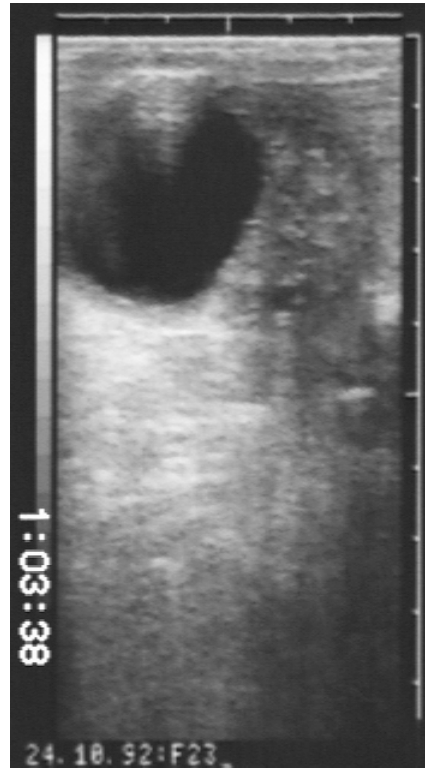


Figure 6 Rt. Ovary Oct. 24,1992

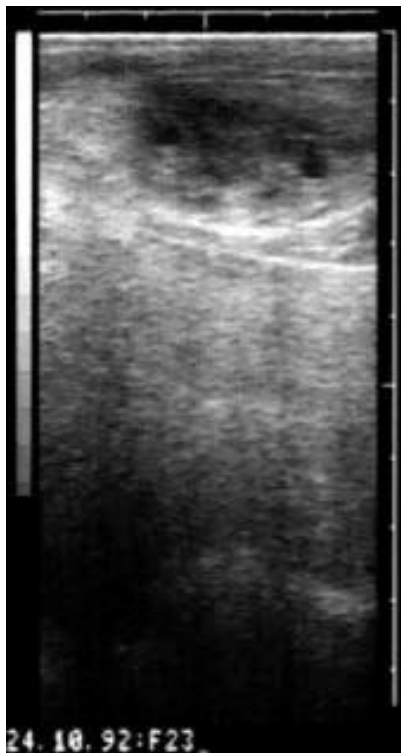

Figure 7 Lt. Ovary Oct. 24, 1992

5. Shah

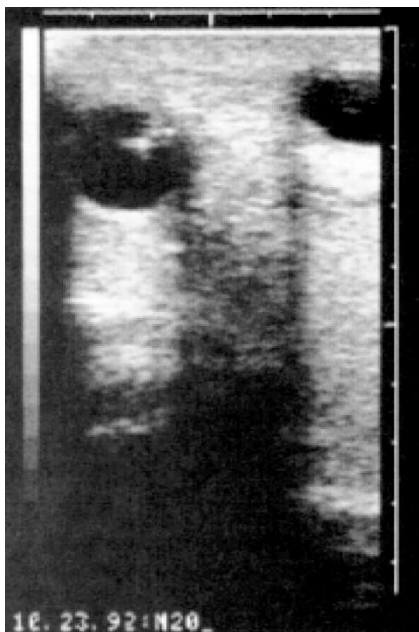
Shah was captured 1988 as young male and treated at the time for phimosis. He also had penile tags (Pictures 1, see next page). Both had resolved by first exam in December, 1991. By October, 1992 he had reached full size and maturity. At this second exam bilateral horizontal swellings (4x8 cm) on either size of the scrotum were noted dorso-lateral to each testicle. They were fluctuate. The testicle was not displaced. On ultrasound non-echoic areas appeared to be between tunics around head and body of epididymis (Fig.1-2), not the tail. Ultrasound of caudal end of both epididymides were non-echogenic areas (Fig. 3)(Schaffer et al. 1994) similar to those seen in other animals. Seminal parameters Table 3 (see next page).

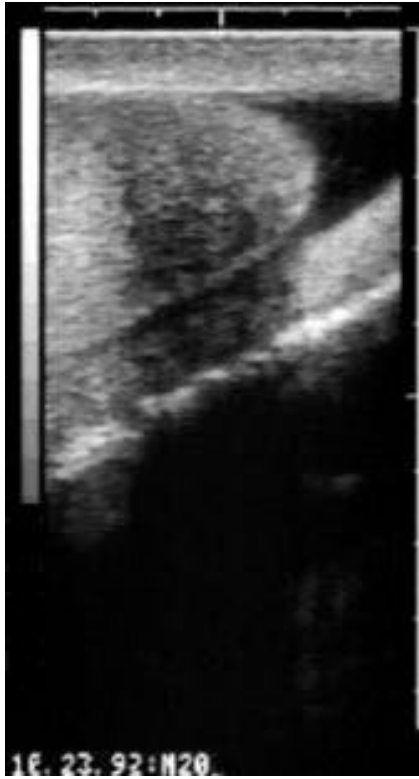

Figure 1 Head of Epididymis

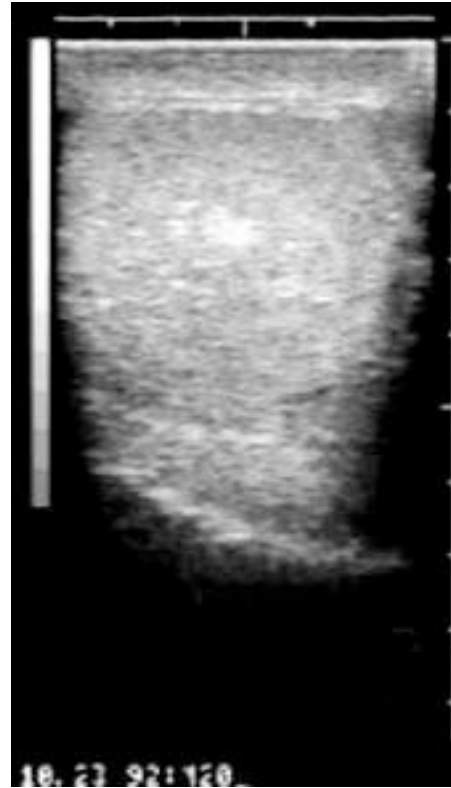

Figure 2 Mid cross-section testicle



**Figure 3 Vertical cross section
of left and right epididymides at
caudal end of scrotum**

(Addendum provided in 2017 Zainal Zahari Zainuddin): Pictures 1. Pictures of tags attaching to various areas of penis. He was 3 years old and condition resolved in a few months. They caused phimosis of the penis seen in top left picture. In top right prepuce is attached to cranial penis. Bottom left picture the lateral projection are attached to each other. (Photos by Zainal Zahari Zainuddin)

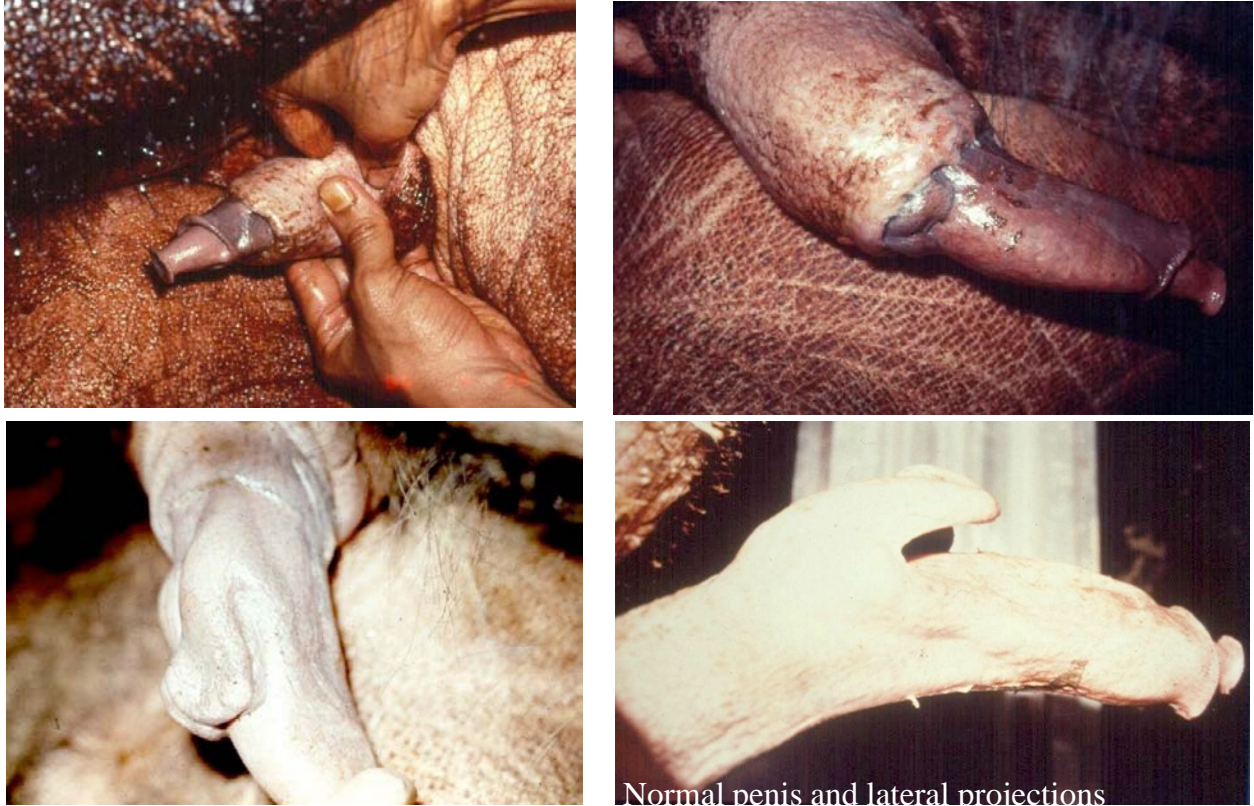

Table 3 Morphology of Sumatran Rhinoceros "Shah" Sperm

Morphology of Sumatran Rhinoceros "Shah" Sperm - SD Sanctuary, Malaysia 1991 - Nan			
Normal:	Normal		29 %
Abnormalities:	Detached heads		4 %
	Cytoplasmic droplets	Proximal	17 %
		Distal	3 %
	Tail abnormalities	Bent	4 %
		Kinked	7 %
		Folded	2 %
		Curled	34 %
	Total abnormal		71 %

B. Sepilok, Sabah Malaysia (1998)

Summary Report of Examination of Sumatran Rhinoceros
Report to Sabah Wildlife Department (JHL) November 17-22, 1998
Nan Schaffer, DVM

Name	Sex	Studbook	Exam Years
Gologob	Female	40	1998
Lun Parai	Female	26	1998
Tanjung	Male	38	1998

Analyzes

ULTRASOUND

Personnel: Nan Schaffer, DVM and Edwin Bosi, DVM

Methods: Hitachi EUB 905 scanner, variable 5.0 and 7.5 MHz probe. Probe was hand held to sonograph female reproductive tracts and male accessory glands per rectum. The testis were imaged through the skin of the scrotum.

History: The nulliparous females have bred in the past, but not produced offspring. The last signs of estrus were only in Gologob in July 1998 when copulation was successful. Both females' records indicated copulation in 1995 with another male Sidom Sb# 36. Tanjung is currently being medicated for sores on his feet.

Summary Report:

Based on breeding history and ultrasound images, these females appear to be cycling. Copulation by the male has been completed, but production of offspring has not occurred.

During several days of examination of the females and semen collection from the male, several problems were identified. First, the females have developed cysts in their uteri and one female (Lun Parai) has several tumors. While uterine cysts are benign in equines causing occasional mechanical loss of pregnancy, in bovids they represent an underlying pathological condition. In other species of rhinoceros, small tumors or a few cysts have been tolerated during pregnancy. In other species, these structures reduce conception rate. Increasing the number of successful breedings of these females would improve their chances of becoming pregnant.

Ultrasound Images:

1. Gologob (1998)
2. Lun Parai (1998)
3. Tanjung (1998)

1. Gologob SB# 40 Examination:

November 17, 1998 - Gologob entered the chute and tolerated palpation. Her uterus was firm, the ovaries were at 54 cm from vulva. They were round and follicles could be felt on both ovaries. The cranial uterine horn measured 10 x 14 mm (Fig. 1). Her left ovary had a corpora hemorrhagica (23 x 27 mm) and a small follicle (8mm) (Fig. 2).

November 18, 1998 - Gologob's rectum was filled with feces, so she was released into her boma until she defecated. After defecating, Gologob went back into the chute, but only the left ovary (31D x 30W) could be ultrasound before she was too upset to continue. The uterus had two cysts (3mm and 3 mm) in the cranial horn. The caudal uterus had two cysts (3mm and 6mm) (Fig. 3). Right ovary had a large follicle (25 x 21mm) (Fig. 4). Left had possible corpus luteum (Fig. 5 arrows).

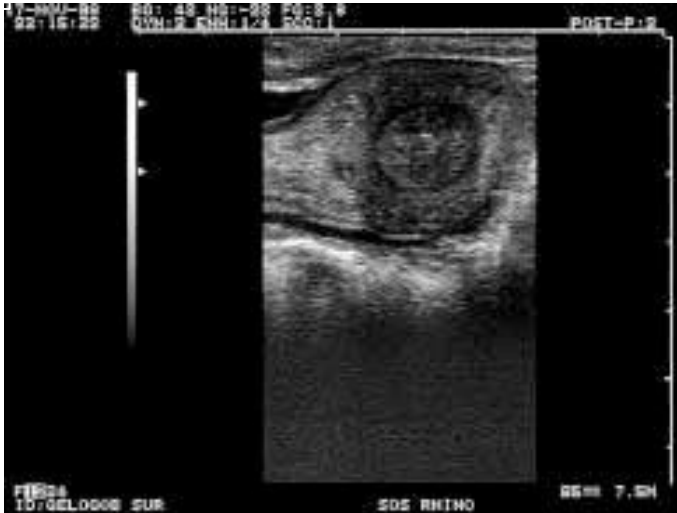


Fig. 1 Nov. 17 Uterus

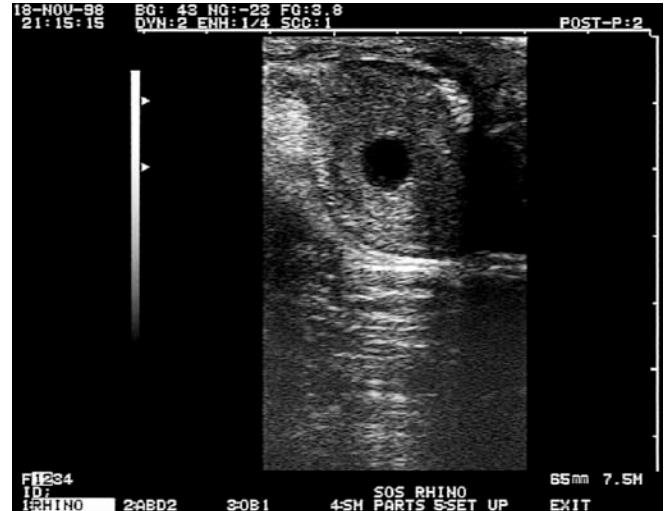

Fig. 3 Nov. 18 Uterine Cyst

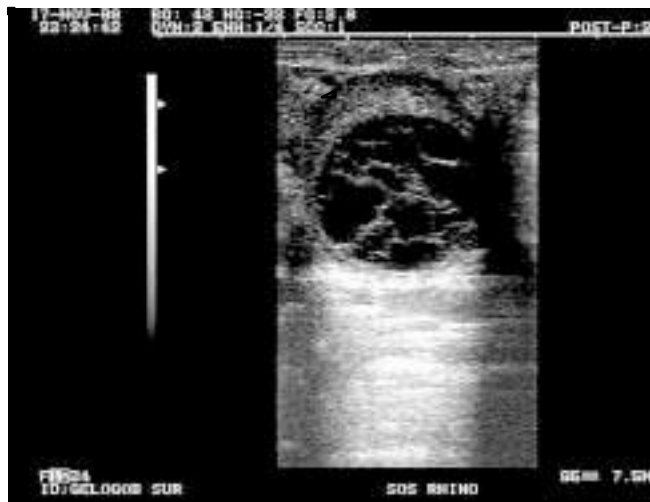

Fig. 2 Nov. 17 Left Ovary Corpora Hemorrhagica

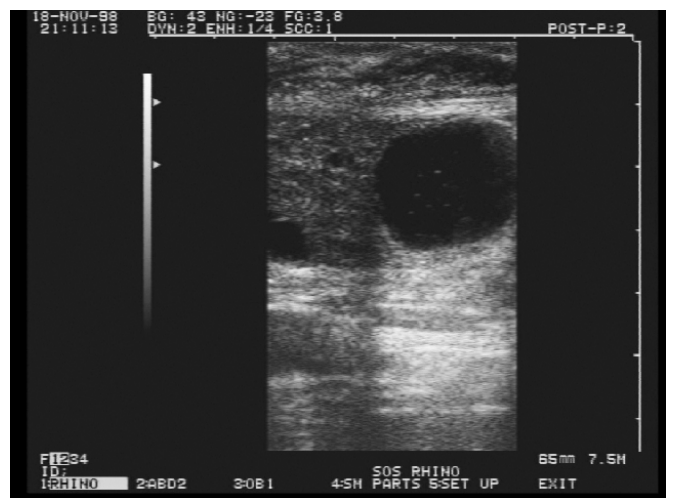


Fig. 4 Nov. 18 Right Ovary Follicle

Gologob Exam (continued):

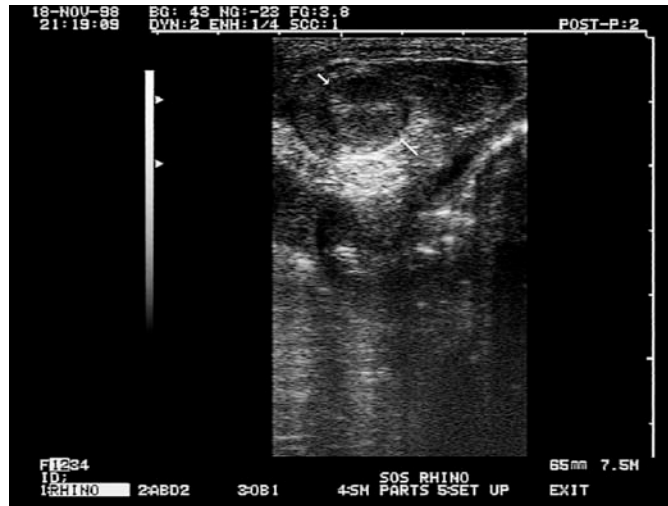

Fig. 5 Nov. 18 Left Ovary CL

November 19, 1998 (con't) – uterus diameter caudal was 26 mm and cranial was 22 mm. The cervix depth was 48 mm. I followed the right uterine horn down to about the middle of the uterus. At this point a cyst (8mm) occurred in the endometrium. Left ovary's corpora hemorrhagica (28x20 mm), a follicle (10 mm).

November 22, 1998 The right ovary (35W x 25D) had one large follicle (18 mm) and a small follicle (10mm) (Fig. 6). Corpora hemorrhagica (20 x 21mm) on the left was shrinking. The other follicle measured 12mm. A uterine cyst measured 7mm. The right ovary (57L x 28D) had a large follicle that was not holding its shape along with a small follicle (12 mm) (Fig. 7).

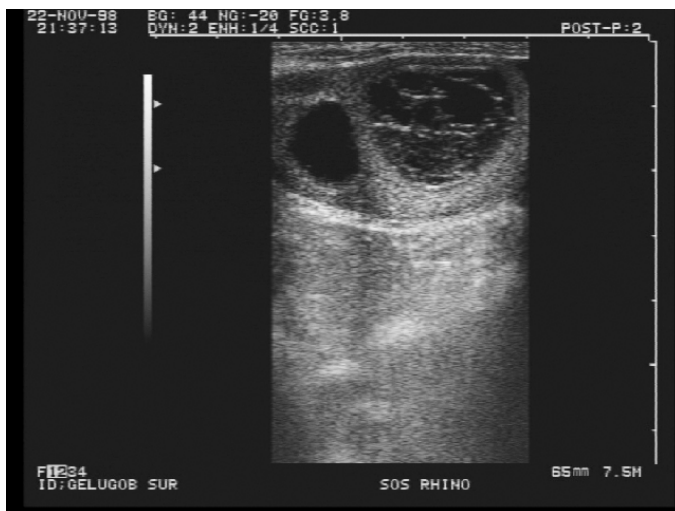


Fig. 6 Nov. 22 Left Ovary Corpora Hemorrhagica

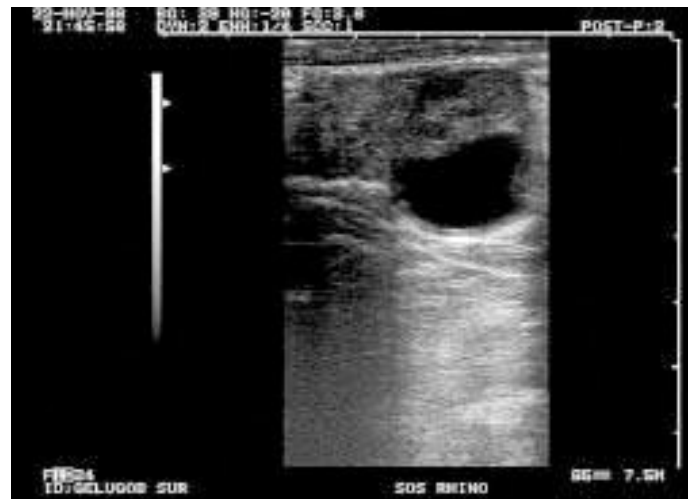


Fig. 7 Nov. 22 Right Ovary Follicle

2. Lun Parai (SB# 26) Examination:

November 16, 1998 - There were four (4) follicles (17mm, 12mm, 11mm and 5mm) on the right ovary (58D x 22W mm) (Fig. 1). Several cysts (5mm and 14 mm) occurred in the endometrium (Fig. 2). She had several masses in left uterine horn 4 -6 cm.

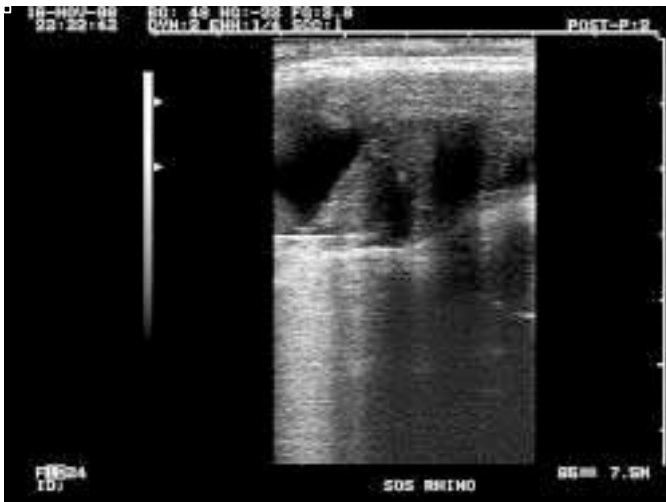


Figure 1 Right Ovary Nov. 16th

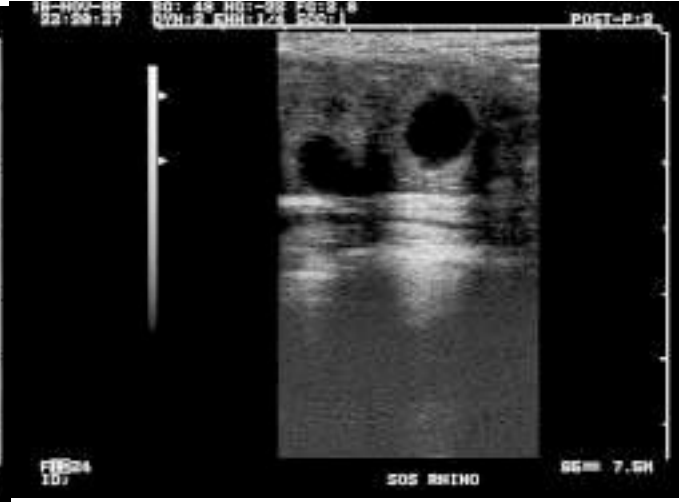


Figure 2 Uterine cysts Nov. 16th

November 18, 1998 - Lun Parai would not come back from the open area.

November 19, 1998 - Lun Parai refused to enter the chute.

November 22, 1998 - She urinated. Once the bladder emptied, it was easier to find the ovaries, but more difficult to find the uterine horns. The right horn had two to three cysts (7mm and 10mm) and a few in body uterus (Fig. 4 arrow) in the endometrium. Ovaries were at approximately 51 cm from vulva.

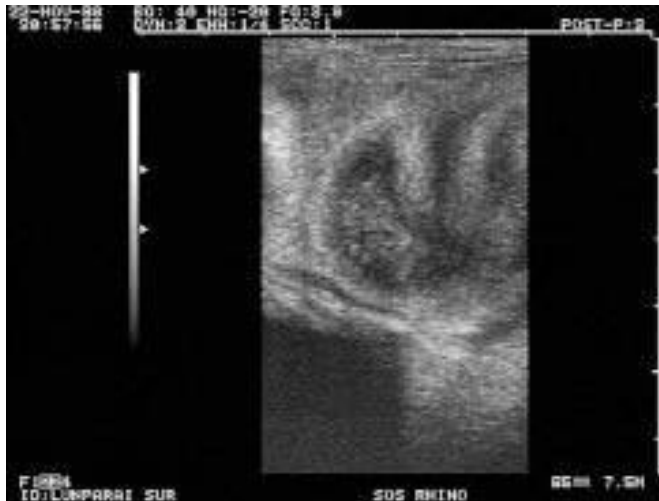


Figure 3 Cervix

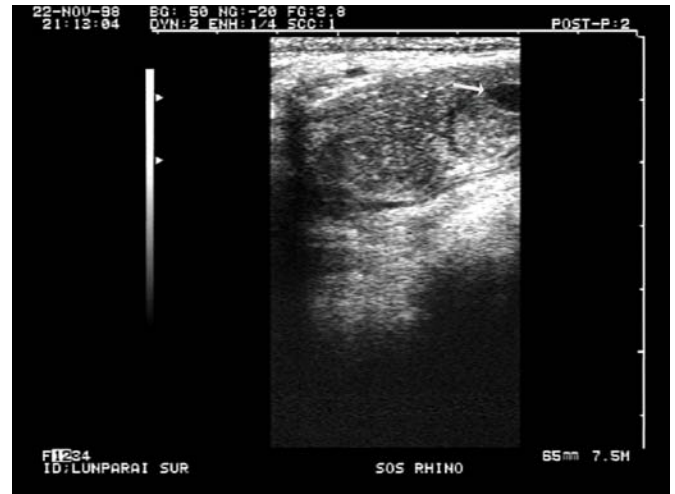


Figure 4 Uterine Cysts

Lun Parai Exam (con't):

November 22, 1998

Lun Parai left ovary (50L x 22D x 30W mm) had several follicles along the ventral border (10mm, 20mm and 12mm) (Fig. 5) and possible corpus luteum (Fig. 6 arrows). Mid-uterine horn was 28 x 20 mm (Fig. 7). A tumor (22 x 32mm) occurred between the right ovary and the uterus (Fig. 8 arrows). Otherwise right had 1 (10 mm) follicle.

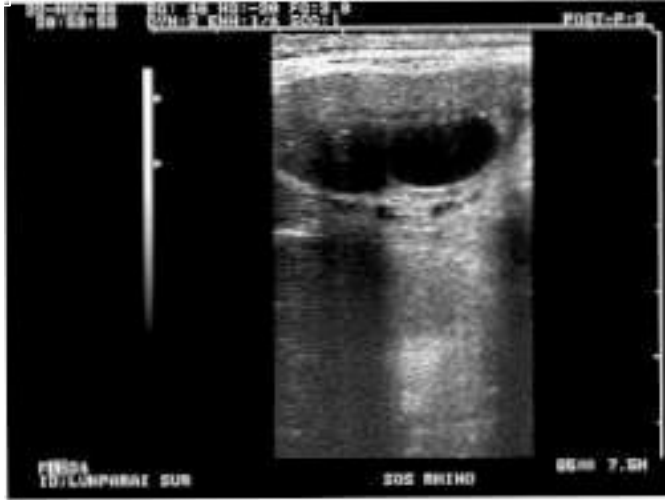


Fig. 5 Left Ovary

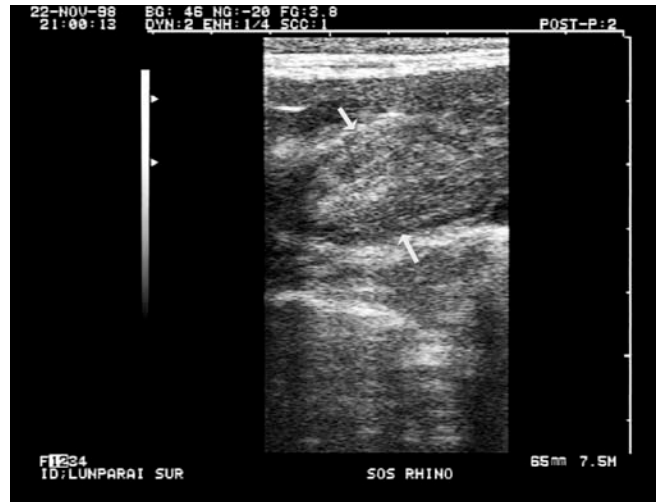

Fig. 6 Left Ovary Corpus Luteum (arrows)

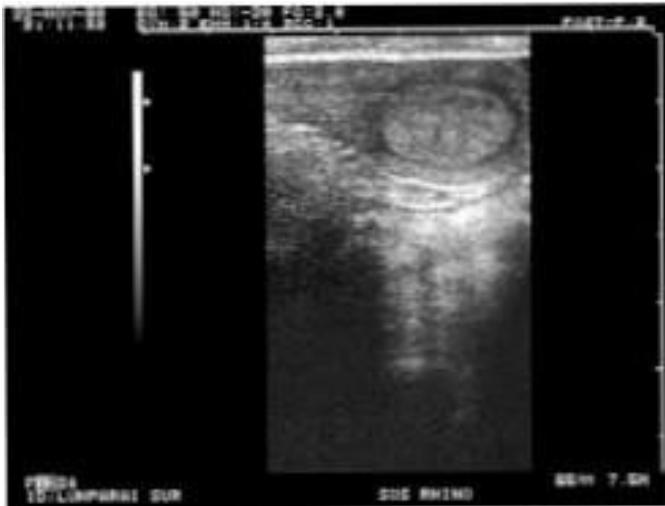


Fig. 7 Uterus

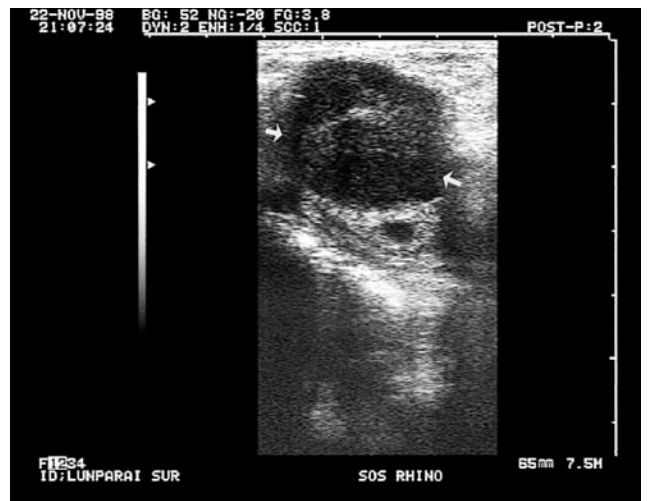

Fig. 8 Tumor between Uterus and Right Ovary (arrows)

3. Tanjung (SB# 38) Examination

Sepilok Sanctuary, Sabah, Borneo, 1998 - Nan Schaffer DVM

November 18, 1998 -Tanjung was standing in his cage, nosing Gologob through the bars. I covered the penis with a plastic sleeve and stroked the sheath. He immediately became erect. He dribbled some yellow fluid (0.5 ml) into the bag. I changed bags. More fluid came with more massage. Keepers coaxed him into the chute. His tail was raised. I began rectal palpation, which he responded to with a full erection, thrusting and ejaculation. This resulted in a large volume (35-40 ml) of thick, opaque fluid, with some tan clumps. The ranger rubbed the penis while I was massaging the rectum. He then lost his erection. Yellow fluid contained calcium carbonate crystals (CaCO₃) and debris. The thick opaque fluid was spun at maximum gs for 10 minutes. A pellet contained some cells (WBC and epithelial), no sperm, and no crystals. Footage by Chen.

November 19, 1998 - Tanjung was in his cage (boma) following James. I put a plastic sleeve over the sheath. With minimal massage, he became fully erect and thrusting forward. The bag collected some yellow fluid (1cm). No sperm were recovered. Ten minutes later, a second attempt resulted in an erection with projections fully extended (seen on video), approximately 12W x 17D x 15L cm. I followed the rhino around his cage, massaging the penis, but he lost full erection. He lay down, rolled over onto his side, but this did not help increase his response. He was on his side only briefly, then stood back up. He began to flick his ears and stomp, so I ended my session. An eight (8) minute session (Tape 2).

November 22, 1998 – Tanjung was collected by penile massage for 10 minutes, but no sperm were produced. He briefly lay down during the procedure. He was enclosed in chute to examine his testicles and accessory glands with ultrasonography. The testicles were down in the sheath. The left was more ventral than the right. With ultrasonography, the mid cross-sectional right testicle (dia.36 mm) and left testicle (dia.42 mm) (Fig. 1) were examined. Epididymal tail diameters were right 19 mm and left 18 mm (Fig. 3 and 4). The fluid that occurred around the tail of the epididymis has also occurred in all other Sumatran males I have examined, except Shah who had fluid around the head. No fluid occurred around either head of Tanjung's epididymides (Fig. 2). The accessory glands were examined. The bulbourethral gland, just inside the anus, has a large vessel running through it (normal). The prostate appeared as a triangular structure, close to the bladder. The vesicular gland is thin, flat and long; a dark structure just lateral-cranial to prostate (Tape 4 and 6).

Summary:

Based on breeding history and ultrasound images, these females appear to be cycling. Copulation by the male has been completed, but production of offspring has not occurred. After three attempts to collect sperm from this male, in which <35cc of fluid was collected from the first attempt, no sperm were evident. I have successfully collected sperm from two other males using the same methods. Sperm was collected from one male after two attempts and 1 cc of fluid. The other male produced a few sperm in three out of 28 attempts in 50 days, producing 14cc of fluid. Both males' sperm were collected during the North American seasons of fall and winter. Most males of other species have at least a few residual sperm in their urethra, which can be retrieved by this method. Testicles and accessory glands appeared normal on ultrasonography. Some factors that may be affecting recovery of sperm include health, age of the animal and/or the method of collection.

Further examinations needed:

1. Semen collection – while it is probable that the male is producing sperm, this should be confirmed.
 - a. continue penile massage
 - b. collect urine and check for sperm as early as possible in the morning, as soon as the animal gets up.
 - c. collect fluid from the female after breeding

Tanjung, Male Sumatran Rhinoceros
Sepilok, Borneo, November 1998

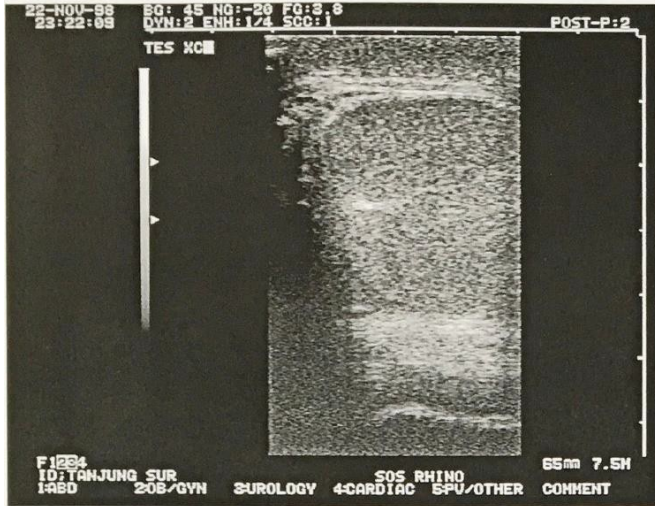


Figure 1 "Tanjung"
Testicle cross section

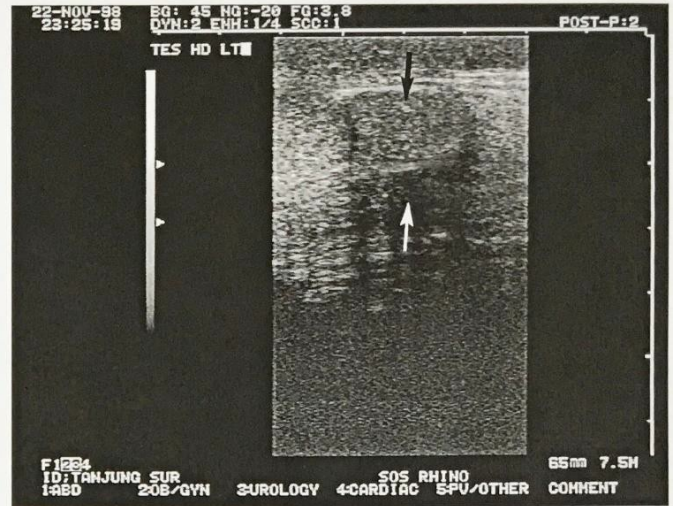


Figure 2 "Tanjung"
Head Epididymis (arrows)

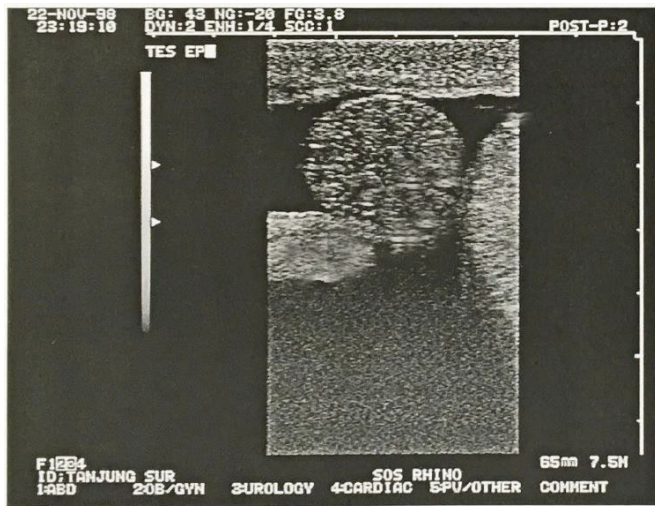

Figure 3 "Tanjung"
Tail Epididymis

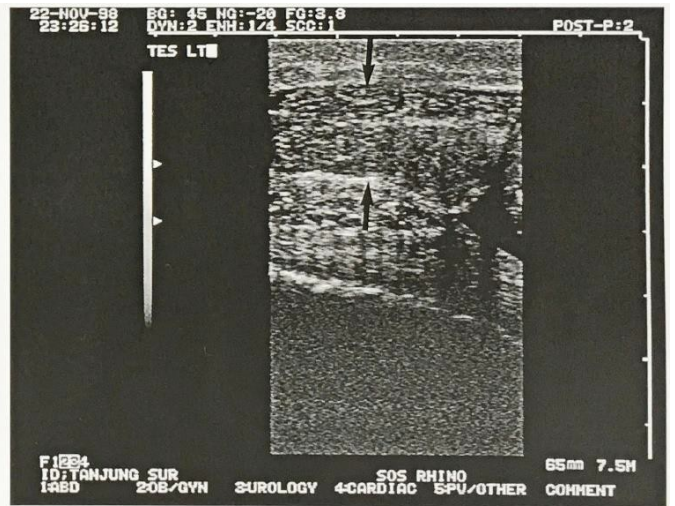
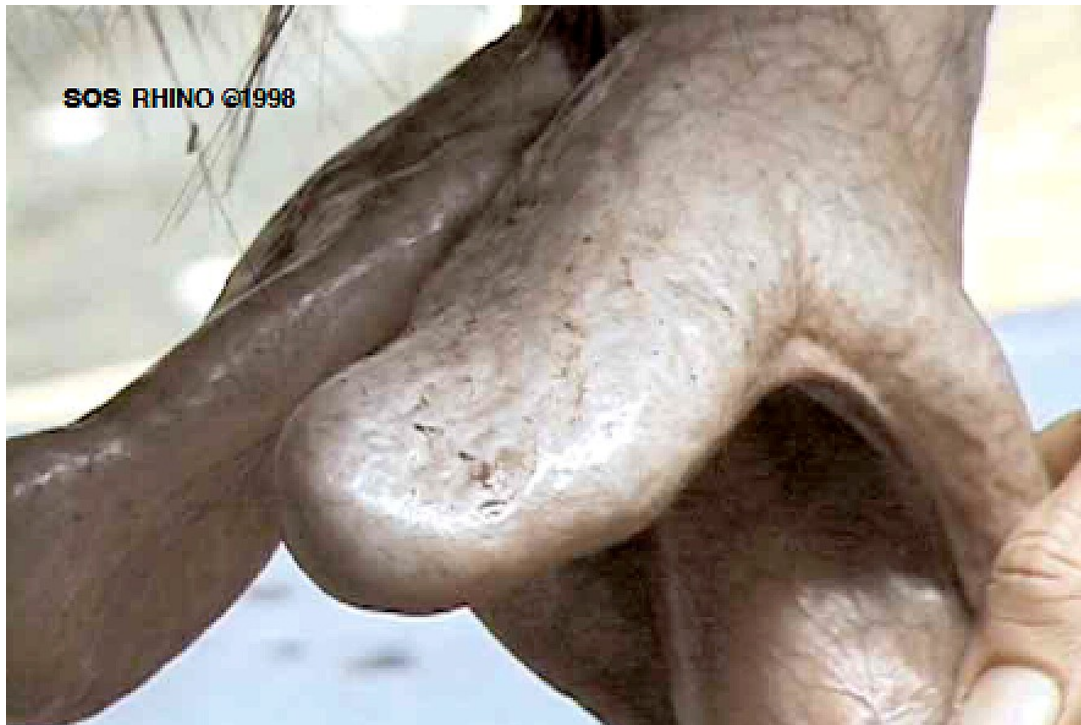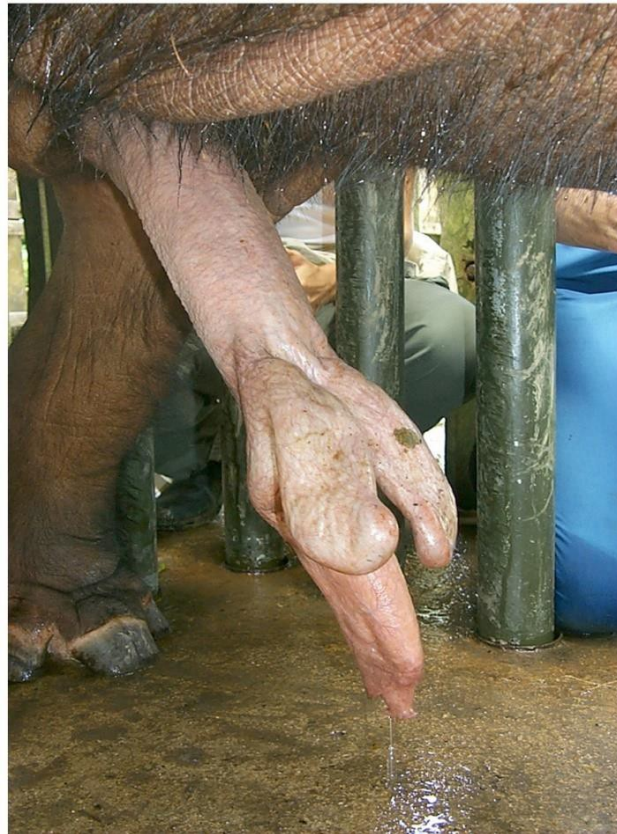


Figure 4 "Tanjung"
Tail Epididymis (arrows)



Tanjung, Sepilok November, 1998
Close-up of lateral projections of erect penis.



Tanjung, Sepilok November, 1998
Cranial end of erect penis.

4. Postmortems (Addenda post 1999)

a. Postmortem of Lun Parai(2000)

A SUMMARY REPORT: POSTMORTEM EVALUATION OF FEMALE SUMATRAN RHINOCEROS “LUN PARAI” REPRODUCTIVE TRACT AT SEPILOK, SABAH, MALAYSIA. N. Schaffer

Lun Parai, a female Sumatran Rhino (*Dicerorhinus sumatrensis harrissoni*) housed in Sepilok Breeding Center, died on August 23, 2000. The cause of death has yet to be confirmed, but salmonella and severe lung pathology were noted on gross post-mortem. The previous ultrasound evaluation of her reproductive tract correlated with findings of gross pathology.

Uterus:

Left Uterine horn.

1. A solid/ firm/ uniform in texture white mass (3x4 cm) was present within the wall at the tip of the left uterine horn — suspect a myofibroma.
2. Two additional “myometrial” masses were located near the bifurcation of the uterus. The first was white, firm, and uniform in texture with in the uterine wall and measured 7x7.5x7cm. The second mass was similar in texture and color and egg shaped and measured 3.5x5.3x3.5cm. (Fig. 1: middle arrow)

Right Uterine Horn

1. Length tip to body 26 cm.
2. No masses noted

Uterine Body

1. 4.5cm in length - no abnormal findings
2. Cervix 7x6 cm in length - no abnormal findings

Ovary

1. Right- 6 x 3.2 x2.2cm (Fig. 1: right arrow)
2. Left- Solid CL tissue 6.5 x1.3 x3.5cm (Fig. 1: left arrow) and (Fig. 2 cut surface)

In summary:

Pathology was reported in 1998 using ultrasonography. The pathology noted on post mortem compared with images at that time. These tumors could interfered with successful pregnancy and implantation. Myofibromas are suspected and are not uncommon in other species of older, non-breeding cycling females.

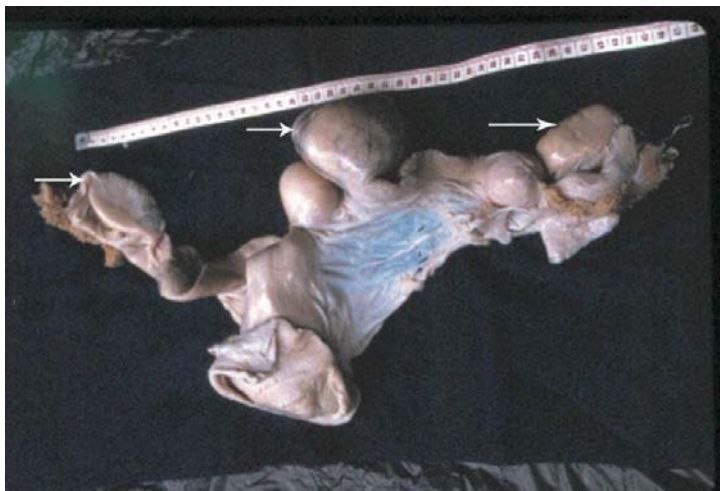

Figure 1 Lun Parai: Left Ovary, Tumor, Right Ovary

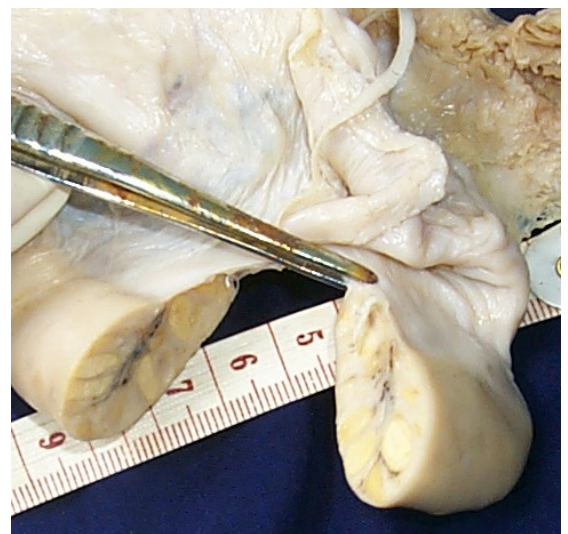

Figure 2 Left Ovary Multiple CLs

b. Post Mortem of Tanjung (2006)

Tanjung Post Mortem Reproductive Reports (Addendum provided 2006)

“Tanjung” Male, Sumatran rhinoceros (*Dicerorhinus sumatrensis harrissoni*)

Date of Death: July 12, 2006

Cause of death: Broken back from tree fall. (Picture 1)

Post mortem findings: Broken spine and internal injuries. (Thaya, Rosa)

Reproductive analyses:

August 21, 2006: reproductive post frozen testicles (Dr. Schaffer, Zoo Hospital Kota Kinabalu)

Feb 2005: electroejaculation (Hermes and Hildebrandt, Tabin Wildlife Reserve); histology testicular biopsy (Mueller, Institute for Zoo and Wildlife Research, Germany)

In the night from 11 to 12 July 2006 there was a heavy thunderstorm in Sepilok. Due to this storm, a large tree standing next to the rhino enclosure fell down and landed on Tanjung’s night stall. The next morning, the dead male rhino was found in his enclosure. The tree broke his back and Tanjung was killed instantly (see Picture 1). Penis and testicles were removed intact from the ventral abdomen and frozen until exam could be made of gross structures. Accessory glands were not included.

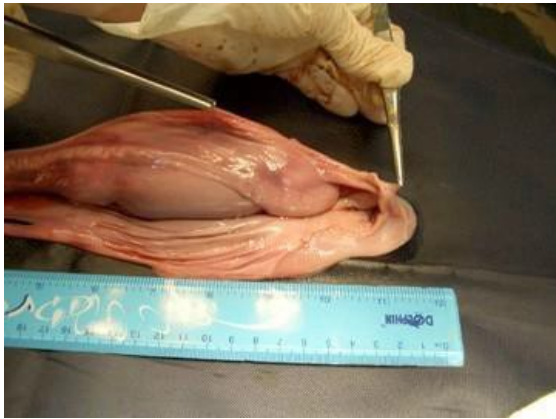

Picture 1: Tanjung was killed instantly when a tree broke his back

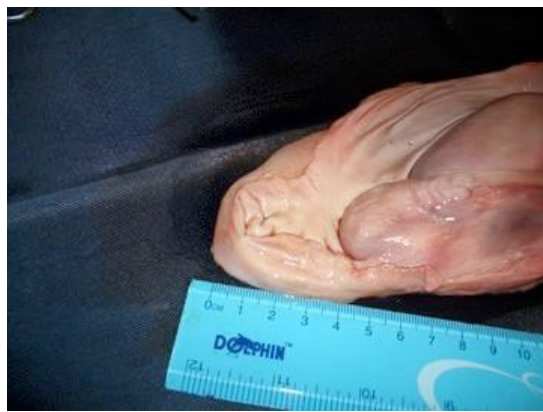Examiners were particularly interested in analyzing whether evidence of cyst or blockage of the epididymis would be evident. A previous testicular biopsy conducted by Dr. Hermes and his colleagues from Berlin, Germany had demonstrated arrested spermatogenesis at the spermatid stage (Hermes et al 2006). The team conducted two electroejaculations, on the 19th of April 2005 and on the 9th of October 2005, but no sperm were produced. An ultrasound investigation of a visible longitudinal swelling just dorsal to the testicle revealed a fluid-filled area. Straw-colored clear fluid was removed. The swelling appeared to be independent of the testicle and extended from the tail of the epididymis to half the length of the testicle. Upon his death, bloat pressure was evident since the penis was protruding which obliterated possible observation of swelling at the time of posting of the animal.

Results of post mortem exam of frozen testicles:

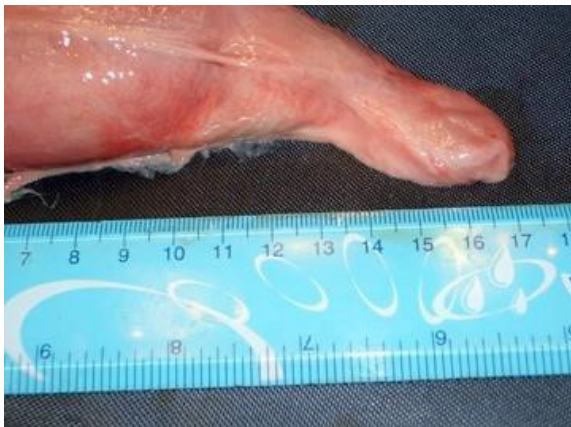Both testicles in their tunics had been dissected from skin and connective tissue of scrotum. Connective tissue of scrotum was edematous. No cysts were noted within connective tissue. Vaginal tunic was cut from inguinal to distal end vaginal tunic. All tissue was red from soaking in blood. Red fluid was in tunic cavity. No grossly visible sacs or cysts were associated with vaginal tunic or along vas, within or associated with epididymis or on parietal tunic or within testicle or epididymis of either right or left side. On both sides there appeared to be a constriction of the vaginal tunic about two cm from the distal end creating a sac similar in shape to the shape of the tail of the epididymis (pictures 2,3) The epididymis was at the opening of the sac, but not in it, and would not reduce into it under pressure due to this constriction (picture 4). The tunic around the testicle was wrinkled longitudinally suggesting excessive expansion of the tunic. Surface of testicle was smooth throughout. Both left and right vas deferens coursed from tail of epididymis across caudal surface of testicle. Both sides demonstrated a brief section of coiling at level of spermatic plexus (picture 2). Picture 2 and 5 also demonstrate the epididymis- scrotal ligament (gubernaculum) extending from distal end of the epididymis to the distal end of the sac. This was evident both left and right.



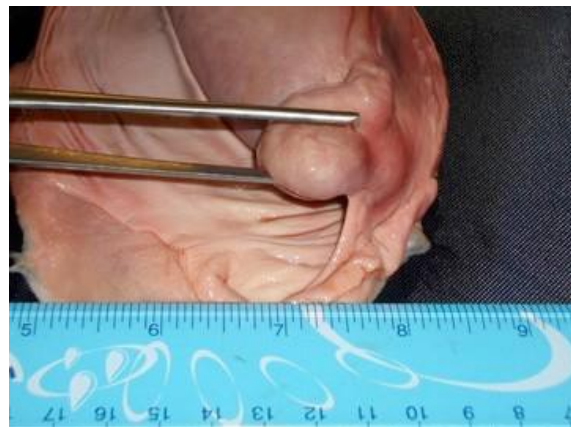
Picture 2: Entrance to unopened distal tunic sac is visible at 3cm of ruler



Picture 3: Opened tunic reveals testicle and sac at distal end – about 2 cm in length



Picture 4 Unopened tunic with distal sac. epididymis would not reduce into sac. The constriction was too narrow.



Picture 5 Gubernaculum attached to epididymal tail.

Measurements:

Right

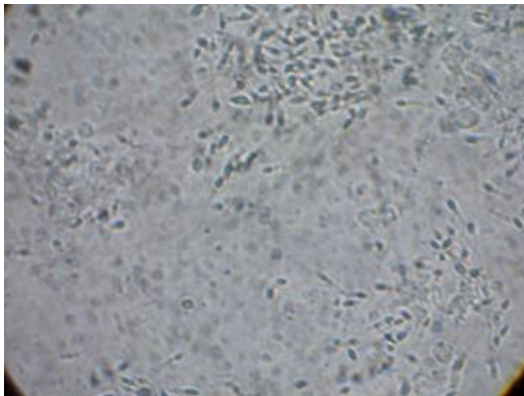
Tunica Vaginalis, distal sac L 3.0 cm x W 2.0 cm
Tail of the epididymis L 3.4 cm x W 1.5 cm Body
epididymis L 9.0 cm x W 2.0 cm Head epididymis
L 3.0 cm x W 2.0 cm Testicle L 8.0 cm x W
4.4 cm

Left

Tunica Vaginalis, distal sac L 3.5 cm x W 2.5 cm
Tail of the epididymis L 3.5 cm x W 1.5 cm Head
epididymis L 3.0 cm x W 2.0 cm Body
epididymis L 8.5 cm x W 1.5 cm Testicles
L 8.3 cm x W 4.6 cm

Both testicles and epididymides were cross-sectioned and impression smears were made.

Normal sperm were present on all impression smears taken of testicle, head and tail of epididymis. (picture 6), but the density of sperm is not comparable with the normal breeding bull. The density of sperm shown on the picture equals a density of around ~20 million sperms per ml, and the picture was taken from a smear of the epididymis, not from an ejaculate. The ejaculate of a breeding white rhino bull with ejaculatory fluids e.g. contained 150-200 million sperms/ml.



Picture 6: 90% images are normal sperm

In the histological investigation of the tissue, only some stages of spermatogenesis were found. The last stage of the sperm was not present while elongated spermatids were present in the few cross sections of the tubuli. The concentration of sperm in the epididymis was low. The flow cytometry of the testicular tissue revealed that only 35 % of the nuclei were haploid suggesting that the spermatogenesis was still arrested at time of death. These post mortem findings in 2006 confirm results obtained from two electroejaculations in April and October 2005 and one testicular biopsy in October 2005 when Tanjung was first suspected of subfertility.

The cytology of the testicular biopsy showed that the tubuli seminiferi contained spermatogonia, spermatozoetes type 1 and only very few spermatids. Elongated spermatids were not present in neither the germinative epithelium nor in the lumen of the tubuli. We concluded that the spermatogenesis in Tanjung is arrested. The presence of elongated spermatids in the epidymidis is therefore not likely. The determined cystic lesions may derive from degenerated epidydimal or duct deferens epithelium. It is difficult to determine origin of the cystic lesions in situ. Epidydimal cysts are reported to cause primary infertility in bucks. A differential etiology is a dermoid cysts. - (R.Hermes, per com. 2005)

Discussion:

Within the tissue provided from Tanjung's reproductive system, no gross anatomical evidence indicated pathology. All structures were bilaterally symmetrical and having characteristics similar to other species of rhino. The vaginal tunic distal sacs were also symmetrical and may be a character of the Sumatran rhino. The fluid accumulation around the tail of the epididymis has been noted in other Sumatran rhino males and in one male around the head (Picture 8). One of these males, Shah at Sungai Dusun, Malaysia had the same swelling above the testicles similar to Tanjung when he came into captivity. Shah's penis was swollen at the time and had to be treated. His ultrasound image also demonstrated the little tag floating in the fluid of the distal sac (Picture 11), which on post of Tanjung appeared to be the gubernaculum ligament (Picture 5). Tanjung also had some accumulation on ultrasound in 1998 epididymal tail (Picture 10). Another male Ipuh, the now breeding male at Cincinnati Zoo, had some accumulation just around the epididymal tail (Picture 9). He was not eating at the time and losing weight. The fluid observed in these animals is outside the reproductive organ and not encapsulated. It is fluid accumulation between connective membranes. Since it also occurred in a breeding male, it maybe a normal occurrence. Further examination of remaining males may reveal more information.

Evidence indicates that it is a hydrocele developed in the tunica vaginalis. Hydrocele can be symptomatic of conditions that can reduce fertility and/or arrest sperm production. They can be associated with an elevation in temperature in the testicle and with problems such as trauma, infection, tumor. Tanjung was vigorously after a stump in the year of question and then stopped (Picture 7). He may have caused the trauma that induced the hydrocele. In pigs and rhinos the testicles are sitting horizontally so the swelling is dorsal to the testicle and caudal in the scrotum. Hydroceles can be seen on ultrasound in boars and stallions and occur from a myriad of causes trauma, stress and orchitis.

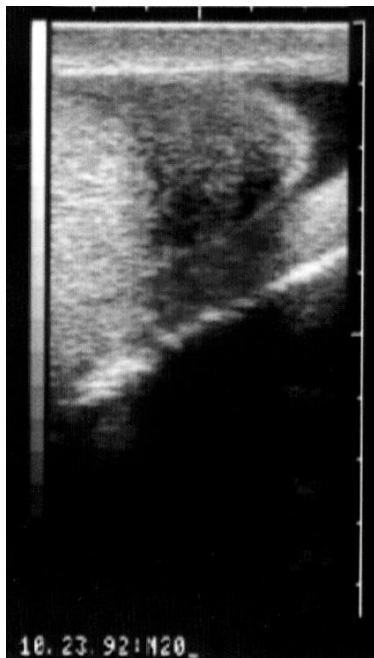The cause for Tanjung's presumed subfertility did not become apparent. Further investigated is needed of fertility of males.



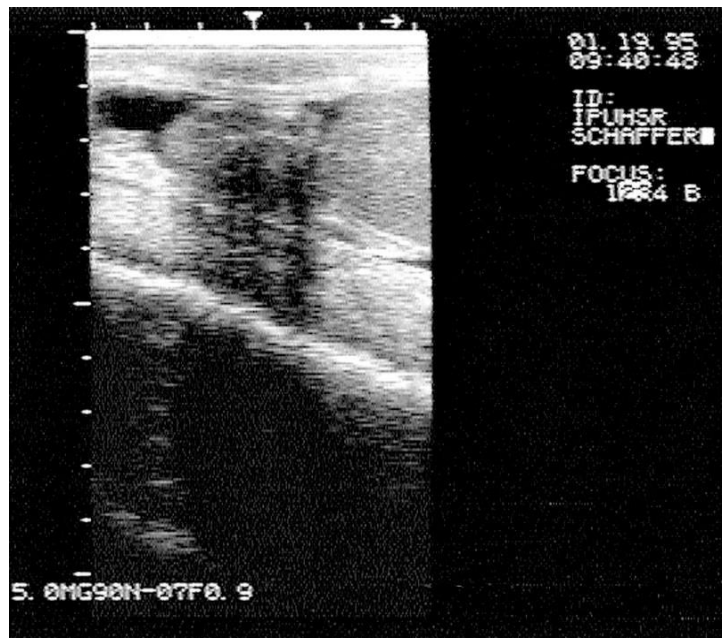
Picture 7: Tanjung and his stump

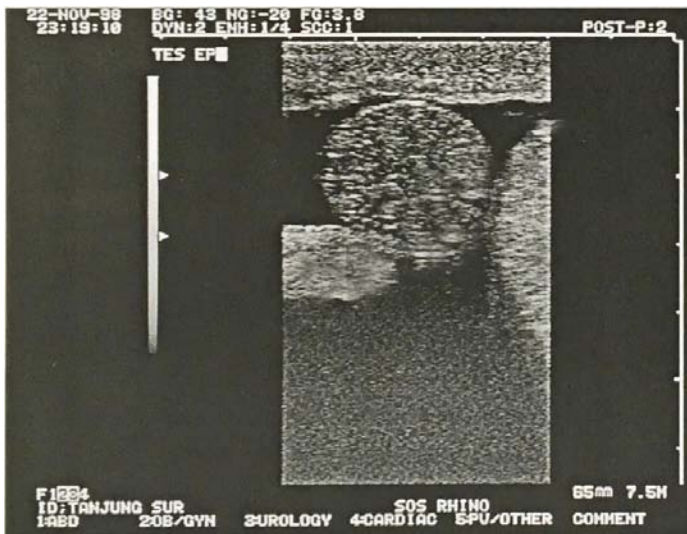Interesting to note that the fluid was associated with the head and body in Shah, not the tail. In the other males it was only associated with the tail, Ipuh and Tanjung.

Picture 8: Ultrasound of Shah, 1991 Sungai Dusun, fluid around the head of the epididymis



Picture 9: Ipuh Cincinnati male, 1994 fluid around the tail of the epididymis





Picture 10: Ultrasound of Tanjung Nov 19 98, fluid around tail epididymis

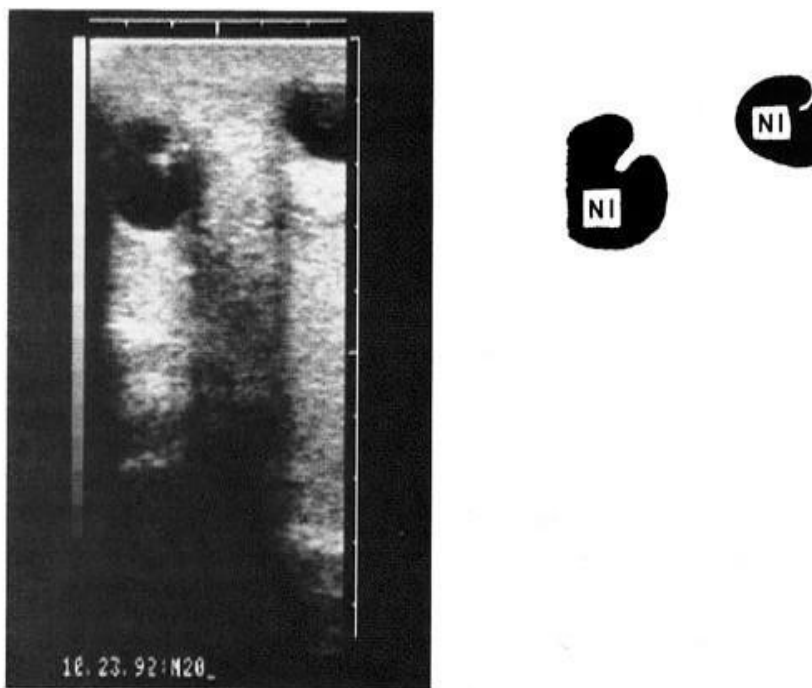


Figure 5. Epididymides of a Sumatran rhinoceros. **Left.** Bilateral nonechoic cross-sectional ultrasound images in association with the body of each epididymis. **Right.** Line drawing: NI = nonechoic image

Picture 11: Shah Reprinted from Schaffer et al 1994.

This cross section is of both testicles at the caudal end of scrotum, possibly gubernaculum in fluid sac.

Hermes et al., 2006 Testis and epididymis ultrasonography and fine-needle biopsy in the rhinoceros for tumor and fertility diagnosis European Association of Zoo- and Wildlife Veterinarians (EAZWV) 6th Scientific meeting, May 24 - 28 - 2006. Budapest, Hungary.

Schaffer et al., 1994 Ultrasound of the reproductive anatomy in the Sumatran Rhinoceros. Journal Zoo and Wildlife Medicine 25(3): 337-348

C. Sumatran Rhino Sanctuary, Way Kambas National Park, Sumatra Indonesia (1999)

**Sumatran Rhinoceros Report to SRS Way Kambas, Sumatra, Indonesia,
February 12-18, 1999**

Nan Schaffer, DVM

Name	Sex	Studbook	Exam Years
Bina	Female	32	1999
Dusun	Female	12	1999
Torgamba	Male	4	1999

Analyses

Ultrasound

Personnel: Schaffer, N.E., Agil, M., Bambang, Roth, T.

Methods:

Ultrasonography: Hitachi EUB 905 scanner, variable 5.0 and 7.5 MHz probe. Probe was hand held to sonograph female reproductive tracts and male accessory glands per rectum.

The testes were imaged through the skin of the scrotum.

Semen collection: Penile and rectal massage.

Ultrasound images:

1. Bina
2. Dusun
3. Torgamba

1. "Bina" Studbook #32 – Exam Report:
February 14 and 15, 1999, Way Kambas, Sumatra
Nan Schaffer, DVM

History:

Bina was wild caught in 1981. She was moved from Taman Safari on Jan. 8, 1998. A tail infection at SRS caused her to lose half of her tail.

Feb. - Mar. 1998: She appears to demonstrate clear mucus and tail - rising every 20 days.

During these periods, the male and female were introduced into the smaller central area of the compound for 4-5 days. She was separated after estrus.

March – December 1998: the male, Torgamba, was not fully fit. They were introduced for the first time in May and June 1998. In December, mounting occurred. Male had full erection, but the occurrence of copulation is unknown. The animals vocalized and were active all day and night. They were separated next day. Two weeks prior to exam at expected estrus female would not stand for male though she was raising tail. In July 1999, animals were again mounting, but overt estrus occurred 2-3 days later.

Exam:

Bina was disagreeable the first day but tolerant the second day. She seemed to rest easier after bamboo poles were placed in the vertical position to contact her rump on either side. The uterine diameter range averaged 25 mm at mid section left uterine horn and 20 mm for right horn. The left uterine horn was less echogenic as compared to the right horn (Fig. 1, 2). The endometrium to myometrium ratio was high.

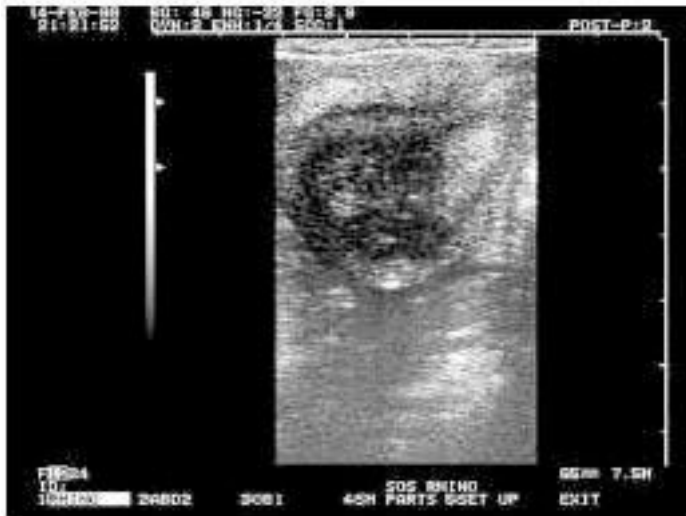

Figure 1 Left Uterine Horn

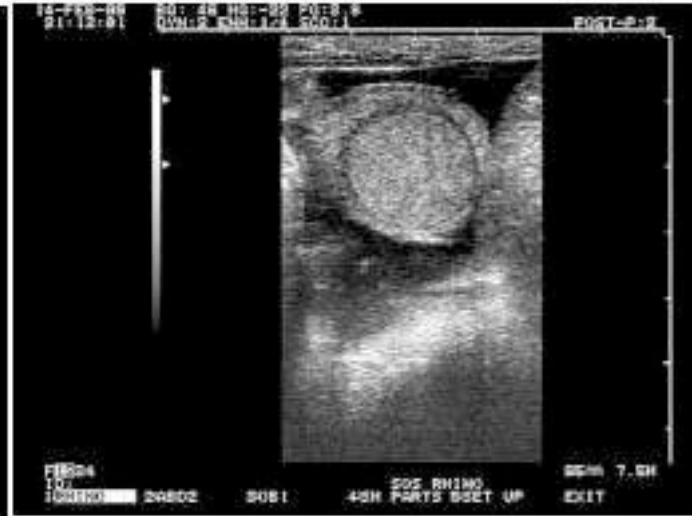


Figure 2 Right Uterine Horn

Bina Exam (con't) February 1999

Ovaries were at 50-55 cm from vulva. Diameters right ovary (35x45mm), left ovary (24x25 mm). Both ovaries had many small densities that were only a few millimeters (Fig. 3). The left ovary appeared to have a corpus luteum (20 x 20 mm) (Fig. 5 arrow) that also appears in Fig. 4 next to a circumscribed mass (23 x 20 mm) (Fig. 4 arrow). Left ovary had a few 10 mm follicles (Fig. 6).

Comments:

Bina appeared to be morphologically normal other than changes in uterus. Thickening of the uterus can occur in response to estrogen, but large estrus follicles were not evident. The mass on the left ovary could not be characterized.

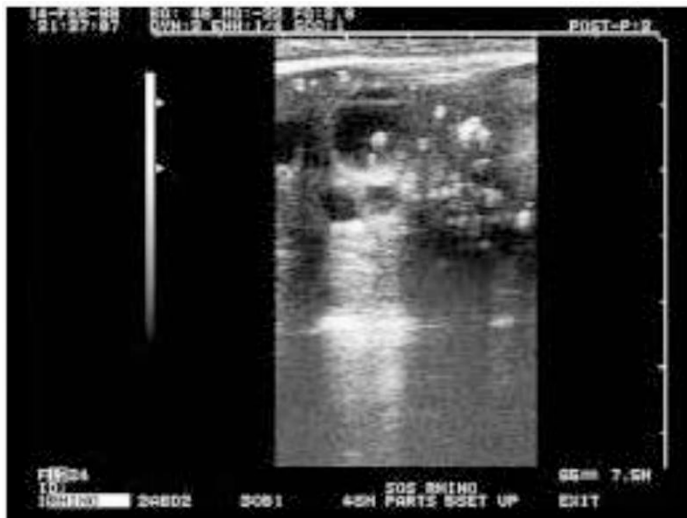


Figure 3 Right Ovary Follicles and densities

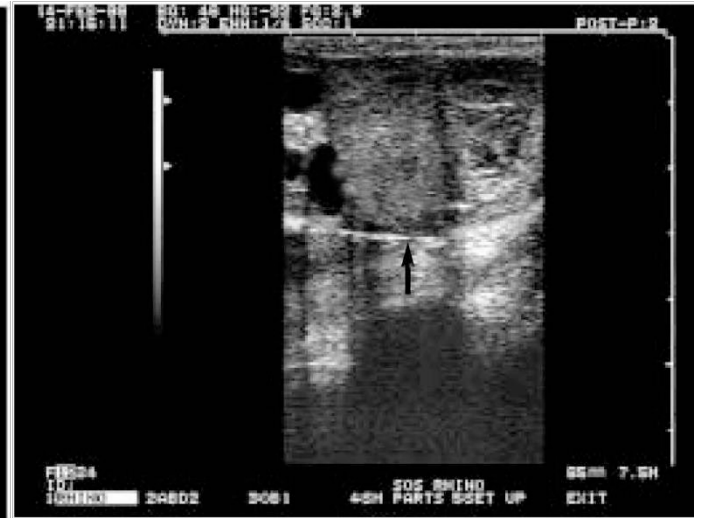

Figure 4 Left Ovary Mass (arrow)

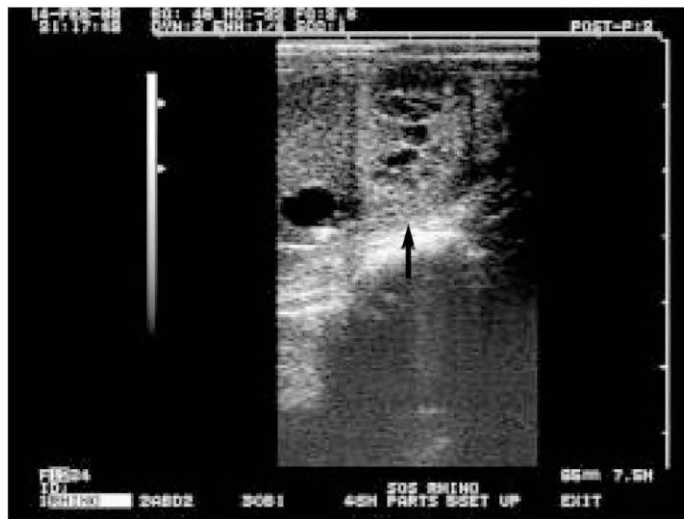

Figure 5 Left Ovary Corpus Luteum (arrow)

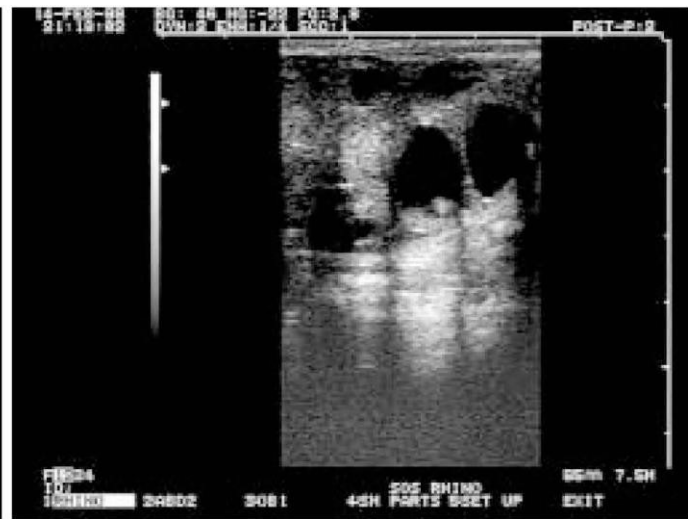

Figure 6 Left Ovary Follicles

2. Dusun, Studbook #12, Exam Report:
February 12, 1999, Way Kambas, Sumatra
Nan Schaffer, DVM

History:

Wild female caught in West Malaysia 1986. She was at the Ragunan Zoo, Jakarta with a male Jalu #8 from 1987-1994. She “mated several times in January 1991,” seemed to stop cycling and later began to produce milk. Personnel assumed she was pregnant, since there was no more mating. The male died in 1994. She was moved to Way Kambas 1998. She is presently still producing milk and there are no signs of cycling.

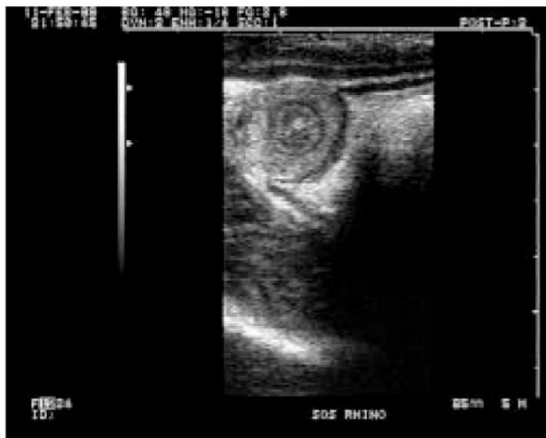Exam:

Dusun was tolerant of ultrasound. The small uterine horn diameter was 1-1.5cm and the ratio of endometrium to myometrium was about equal through its entire length (Fig. 1 & 2). Though no large cysts or tumors were evident, at least one echogenic density occurred mid-uterine horn (Fig. 1). The left uterine body demonstrated some loss of architecture. Ovaries were at 50 cm. The right ovary appeared to have a regressing corpus luteum (15 mm) (Fig. 4) and a few follicles (Fig. 3). The left ovary was difficult to locate. Two structures that varied in echolucency were located just over the brim of the pelvis and in the 70-80 degree position from horizontal. One was flat with multiple small cysts (2mm) and several echogenic densities (Fig. 5), presume left ovary. Other structure could not be identified.

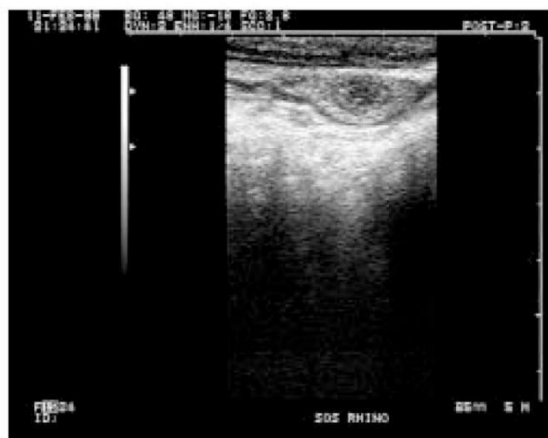
The 20cc of milk expressed from one teat was not exhaustive. The milk was a translucent white. The mammary glands were reported to be smaller than when they first developed in 1991. Personnel suggested that she was presently overweight.

Comments:

Further examination is needed to confirm the morphology of the ovaries of this female. The left ovarian inactivity should be confirmed and the potential corpus luteum on the right needs to be distinguished by examining its development. The thinning, as compared to other rhinos, of the endometrium could indicate prolonged quiescence.



**Figure 1 “Dusun”
Uterine Horn w/ Echogenic Densities
Cross section**



**Figure 2 “Dusun”
Uterine Horn
Cross section**

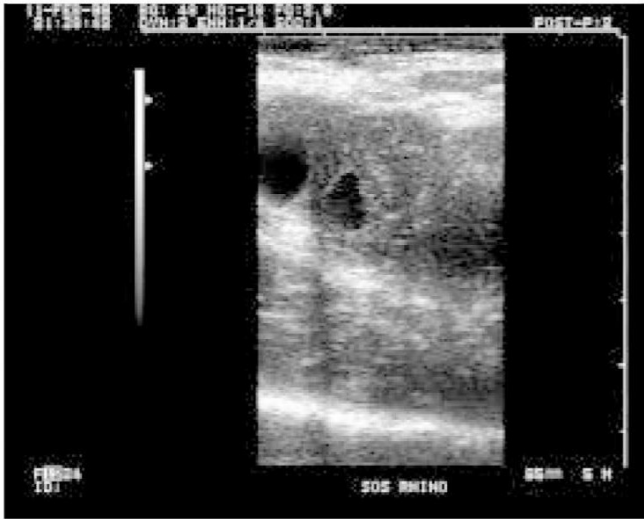


Figure 3 "Dusun"
Right Ovary
Follicles

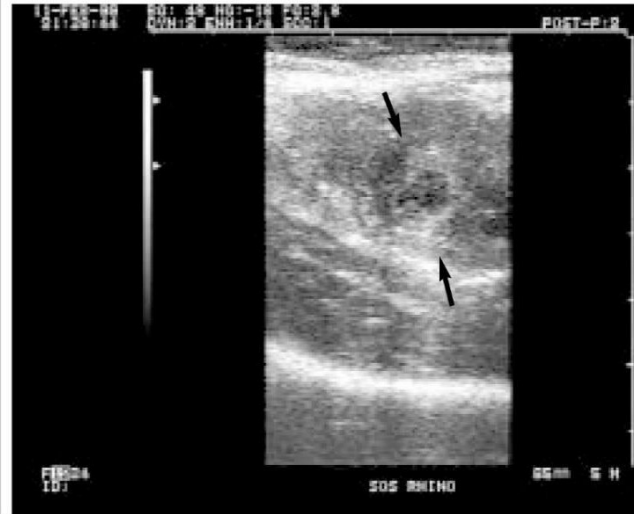

Figure 4 "Dusun"
Right Ovary
Possible Corpus Luteum (arrows)

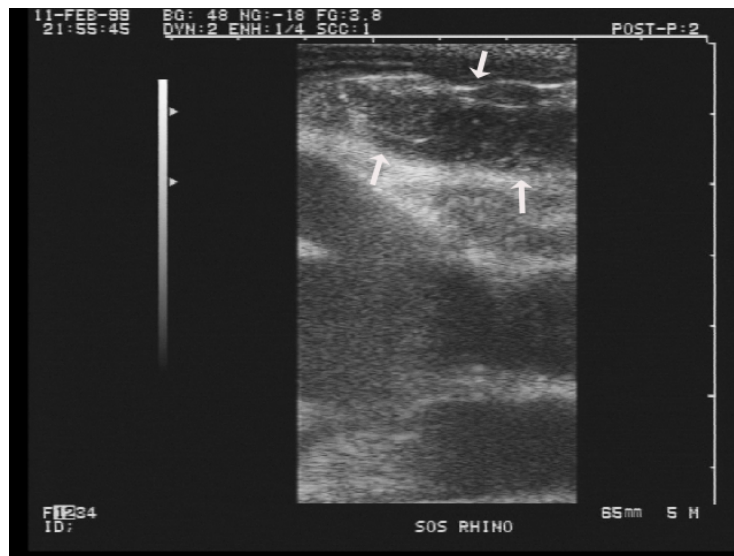


Figure 5 "Dusun" Left Ovary ? (arrows)

The following Addenda a. - d. "Dusun" were added in 2000 and necropsy in 2001.

a Dusun Diagnostic Plan and Report to Nico van Strien, SRS, Way Kambas (2000)

Report Sepilok, Sabah and SRS, Way Kambas, Indonesia May, 2000

SOS RHINO: Nan Schaffer & Annelisa Kilborne

- Progress has been slow in preparing Sepilok for its intensive work-up.
- One of the animals that had lost weight is stable, based on several reports. For additional diagnostics refer to Dr. Sen Nathan and JHL.
- Supplies (currently unavailable in Sabah) to help Lun Parai have been sent and additional supplies will follow (including medical supplies). Other supplies needed will be located and supplied.
- Chute design has been passed to a Malaysian engineer for suggestions.
- Papers in order for Ultrasound, which will go out to Way Kambas, US probe has potentially been located for Sungai Dusun.
- Diagnostic flow chart for further diagnostics on Dusun follows this report.
- Proposed Diagnostic Flow Chart for Dusun. Case Summary.

○
Dusun#12, wild caught in West Malaysia in 1986, is estimated to be over 17 years of age. She bred in 1991 after being with a male for 8 years. She stopped cycling after this and later began producing a milky discharge. She also appears heavier for her height than other captive rhinos. Her skin is darker than other rhinos. Presents with chronic (9 years in duration) bilateral fluid discharge, "lactation" from mammary glands. No behavioral or hormonal cycling observed (further details provided by multiple participants involved in previous evaluations). The desired outcome is the resolution of amenorrhea and galactorrhea in order for Dusun to return to healthy state and potentially breed successfully.

Further diagnostic to determine the cause of her galactorrhea and amenorrhea (chronic lactation and non-cycling condition). Potential diagnoses: DDX for Galactorrhea.

Prolactin secreting tumor

Hypothalamic / hypothyroidism

Pituitary disease / tumor

Microadenomas-loss of diurnal rhythms-constant light exposure?

Macro-incl. visual loss, loss of libido, hypogonadism, impotence (male)

Neoplasia (Ovarian, other)

Idiopathic

Other (nutritional, other...)

Diagnostics and Work-Up include:

Chronological history- w/ exact dates etc.

Evaluation of discharge for color & consistency (repeat), strip/ bilateral equivalent/ fat droplets/

Visual exam: Menace, extra-ocular eye movement, ocular fundi

Neuro-exam

Thyroid size? Via US of healthy and individual w/ Dz

Skin texture, pigmentation, hirsutism

Rule out acromegaly

Rule out Cushing's syndrome

Rule out Hypo and hyper-thyroidism

Rule out ingestion of galactagogues.

The following is the work-up for Dusun. Dr. Roth is preparing some of the diagnostics for normal comparison. It would be beneficial to also have Bina run for normal.

To determine the cause, the following tests will help elucidate the diagnosis. These tests include:

Dusun: Differential Diagnostic Testing					
WHEN POSSIBLE: ALL SAMPLES SHOULD BE COMPARED WITH >1 "HEALTHY" INDIVIDUAL					
WHEN POSSIBLE: ALL SAMPLES SHOULD BE ANALYZED AT THE SAME TIME BY THE SAME LAB					
Note: Consider sending samples to Germany for evaluation					
Organ/System Evaluated	Test	Sample	Storage	Analysis	Diagnosis
Discharge/Milk	Protein/Casein	Discharge	Frozen	Sent to Terri Roth	
	Fat				
Thyroid	Ultrasound			Compare w/ Healthy Ind.	R/O Hyper- & Hypothyroidism
	T4	Blood	Frozen		R/O Hyper- & Hypothyroidism
	T3	Blood	Frozen		R/O Hyper- & Hypothyroidism
	TSH	Blood	Frozen		R/O Hyper- & Hypothyroidism
	Prolactin Levels	Blood	Frozen	3 Samples q/1hr	R/O Pituitary Tumor
Reproductive System	FSH				R/O Reproductive Tract Path
	LH				R/O Reproductive Tract Path
	Estrogen				R/O Ovarian Tumor
	Ultrasound			Evaluate L & R Ovaries	R/O Ovarian Tumor
Other Hormones	GH				R/O Neoplasia
	Serum Osmolality				R/O Neoplasia
Food Composition	Nutritional Analysis	Dried Samples			R/O Ingestion of Galactagogues
Bone	X-ray			Evaluate Growth	
Hirsutism	Photos				
Hyper-pigmentation	Photos				

b Prolactin Levels

Sumatran Rhino Prolactin Results Janine Brown, National Zoo, USA 1999

Dusun and Emi Sumatran rhino

Recovery

Tube #	Amount Added	Amount Expected	Amount Measured	% Recovery
	0			
1	0	0.324	0.324	100
2	2.5	2.824	2.285	80.9
3	5	5.324	6.16	115.7
4	10	10.324	12.568	121.7
5	20	20.324	18.391	90.5

Linearity

Dilution	Conc. Ng/ml
1	.325
2	.253
4	.285
8	.266
16	.187

Emi PRL concentrations on 2 different samples: 12.96 ng/ml 11.4 ng/ml

Dusun PRL concentrations on 1 sample: 15.6 ng/ml

c Serology

Nan Schaffer October 1999 comments to Tom Foose

Her serum for basic elements (K, P, Cu, Zn, Ca, etc.) as well as vitamin A, E and selenium appeared to be in line when compared to the blood of four other females.

d Hormone Dusun - Fecal E2 and Progestin - M. Agil 1999

Dusun May 12-August 9 1999

In general, Dusun has some ovarian activity, although it seems in irregular pattern. E2 concentration remained very low and almost below base line of that seen in Bina and Gologob (less than 100ng/mg Cr) but after mid. July until end of the month there was an increase of E2 for short period followed by a return to baseline levels. Interestingly, there were several increases of progestin metabolites, although these were unlikely to represent the luteal phase because of their short duration.

e. Dusun - Necropsy, SRS, Way Kambas

LABORATORIUM PATOLOGI VETERINER

Jurusan Parasitologi dan Patologi, Fakultas Kedokteran Hewan – Institute Pertanian Bogor Jalan Taman Kencana No. 3 BOGOR – 16151

Tel dan Fax: (0251) 329539; Email : patolpb@Indo.net.id

No.: P/04/01

Anamnesis:

Sumatran Rhinoceros, 35 year old, Female, died on February 07th, 2001 at 01.50 local time.

Clinical history:

Paralysis for 10 days, appetite was normal.

Necropsy Findings:

February 07th, 2001

There were decubitus lesions at hind leg and mammary skin, inflammation of mammary gland, subcutaneous edema with serous atrophy of the fat. Tracheal mucosa was hemorrhagic with mucous exudate. The lungs were congested with multifocal calcification; a bullet was found attached to the inner site of bronchi; there was an adhesion of the pleura and diaphragm. The heart showed serous atrophy of the depo of fatty tissue, dilation of the left ventricle with thickened valves, and the myocardium was pale. There were multifocal raised plaques over the surface of aorta and left atrium. The stomach was full of normal ingesta, the mucosa was reddish and ecchymotic. Inflammation with catarrhal exudate was found in the intestines. The liver lobulations were accentuated and there was one white cyst 0.5 cm in diameter. Nodular hyperplasia (1cm in diameter) were found in the spleen. Both kidneys have multiple brown cysts (0.5---1 cm in diameter); the cysts contain black and gritty like materials. The urinary bladder contain deposit of greyish white sandy materials, with some ecchymotic hemorrhage on the mucosa. Pancreas was red and diffusely nodulated. The wall of the uterus has a focal thickened nodule of 2 cm in diameter.

Diagnosis:

Decubitus, Mastitis, Oedema, Tracheitis, Pneumonia, Corpus alienum, Pleuritis, Dilatatio cordis sinistra, Artherosclerosis, Gastroenteritis catharalis et hemorrhagica, Spleen hyperplasia and kidney cyst.

Histopathological examination of all organs is in progress.

Pathologist Bambang Pontio Priosoeryanto, DVM, MSc, Ph.D.

Nlp. 131 578 839

3. Torgamba, Studbook # 4

SRS, Way Kambas, Sumatra - February, 1999

Nan Schaffer, DVM

History

Wild caught in Sumatra in November 1985. He was not full-grown. Resided Port Lympne, UK, 4 April 1986-1998. He mounted Meranti a few times in the first few years, but no intromission. She died in 1994. He recently (Nov.1998, Aug. 1999) mounted Bina, but interest was minimal and no intromission to date.

Exam

Mohd Agil removed feces. Torgamba seemed to be tolerant. He was walking around cage. He would not go into chute so Agil and I followed him around cage. He would not stop walking even for food. It was his normal feeding time. The keeper and I rubbed his inside leg, but he was not stimulated so I massaged the penis directly through the sheath. He dropped his penis but reacted slowly. I directly massaged and pulled down on penis. The mud was washed off and massage continued as walked with him around cage. It was difficult to walk and massage. He was becoming disinterested after about ten minutes. I asked Agil to start massaging the rectum. Torgamba responded with erection forward but did not maintain. Five more minutes of walking around cage was not effective. I took over the massaging of the rectum. I firmly stroked and squeezed the isthmus of the prostate. I moved across the isthmus applying pressure down with my hand and stroked different areas. Also sometimes moving in and out of the rectum. The erection became full. The lateral extensions of the penis seemed to be at their furthest extent. They could have stretched the vagina as much as 20 cm in diameter. From lateral projection to lateral projection was 12 cm and the projections were 8cm long and directed cranially. Some drops of fluid resulted when initially performing penile massage (no sperm), but it did not flow until rectal massage was included. Rectal massage increased erection and his back legs began to shake. The penis straightened out. He was also able to hold his penis up and forward. He thrust forward particularly when massaging tip of the penis and squeezing it in back of projections. They were positioned together at the dorsal aspect of penis. The projections formed a concave sloping together toward end of penis. I could not flatten them forward or back. Fluid that was in the plastic bag at that point was reddish, viscous and foaming. He became fully erect, the penis was straight and the flaps were fully erect. His back legs were shaking and a few thrusts occurred. His projections were getting abrasions from rubbing against his skin. With one thrust his back legs almost went out from under him. He came close to being on his stomach. He relaxed. Penis was almost back in sheath. At this point twenty minutes had expired. I massaged again to get pictures (Karen shot). Clear fluid flowed from the penis. Ultrasound was not possible but the testicles were firm and morphology appeared normal. Also, accessory glands were just inside the anus and felt normal. He became partially erect, but not fully.

Lab: 9.5cc of reddish cloudy viscous fluid in tubes was taken to the lab. Under microscope there was a lot of debris epithelial cells with some red and white blood cells. After spinning the sample at 17500RPM, the sediment was examined. After an extensive search, four deteriorating sperm were found. Smears were made and stained at university.

Comments

Similar to other Sumatran rhinos I have collected, this male responded to penile and rectal massage. Rectal stimulation appeared to enhance stimulation. As with other animals volumes have resulted from a few drops to several cc's and usually contain very few sperm. When the projection of the penis became fully erect they could not be flatted and pointed forward. The significant diameter and shape of the fully erect penis would prevent penetration into the vagina.

The seminal fluid was reddish tan compared to other samples from other Sumatran rhinos. Glands on the penis of rhinos produce a brown exudate. This exudate may have entered the sample due to prolonged rubbing. Since the sample became red over time and clear fluid was flowing at the end of collection. Rubbing also probably produced the significant debris. Clear viscous fluid is generally associated with seminal vesicles. The lack of sperm is not unusual with this method. The sperm were probably residual in urethra and therefore degenerating.

D. Taman Safari, Bogor, Indonesia

1. Dalu – Studbook #22
 - a. post-mortem measurements and images
 - b. histology report
2. Romi Studbook #30
 - a. post-mortem measurements

1. Dalu Studbook # 22 - February 18, 1999

a. Postmortem Nan Schaffer, M. Agil

History

No breeding; suspect cycling; died of hemorrhagic enteritis and twisted gut.

Pathology of Reproductive Tract: On plastic cover: formalin tissues Sumatran Rhino (Dalu) Female 1993 died twisted gut. Kidney failure. Preserved in formalin. Ovaries and uterus were intact, but the cervix could not be identified. Some of the vagina was present.

Ovaries were firm and consisted of several firm round nodules that appeared to be corpora lutea (Figs. 1 and 2). The cut surface of these structures consisted of pale yellow tissue inside a thin capsule (Fig. 3). The cut surface of the ovaries also revealed a connective tissue cortex that was surrounded by the nodules. Very little ovarian parenchymal tissue was evident. The diameter of the uterus was significantly enlarged (Fig. 4). Bilateral unknown structures were both hanging by a serosal tag from adnexa (Top of Fig. 1). They were bean shaped and covered by a peritoneum capsule. Inside was yellow inspissated material. Sections: ovary, infundibulum, endometrium, vagina and unknown structure (See Histopathology by Kinsel 1999; Page 46)

Measurements: Sumatran Rhino "Dalu" -- Tamin Safari -- February 1998

OVARY	Right	Left
Length	9.0 cm	7.5 cm
Width	6.5 cm	4.0 cm
Depth	3.0 cm	3.4 cm

CORPUS LUTEA	Right Ovary	Left Ovary
	3.2 x 3.0 cm	2.5 cm
	2.0 x 2.0 cm	2.5 cm
	1.2 x 1.2 cm	2.0 cm
	1.8 cm	1.0 cm
	1.6 cm	1.0 cm
	2.5 cm	1.4 cm
	1.0 cm	0.5 cm

UTERUS	Left	Right
Length	46 cm	36 cm
Mid-uterine Dia.	6.0 x 6.0 cm	5.0 x 5.5 cm

UNKNOWN STRUCTURE	Right	Left
	6.0 x 3.0 x 2.0 cm	6.0 x 3.0 x 2.0 cm

“Dalu”, Female Sumatran Rhinoceros
Bogor, Java – February 18, 1999

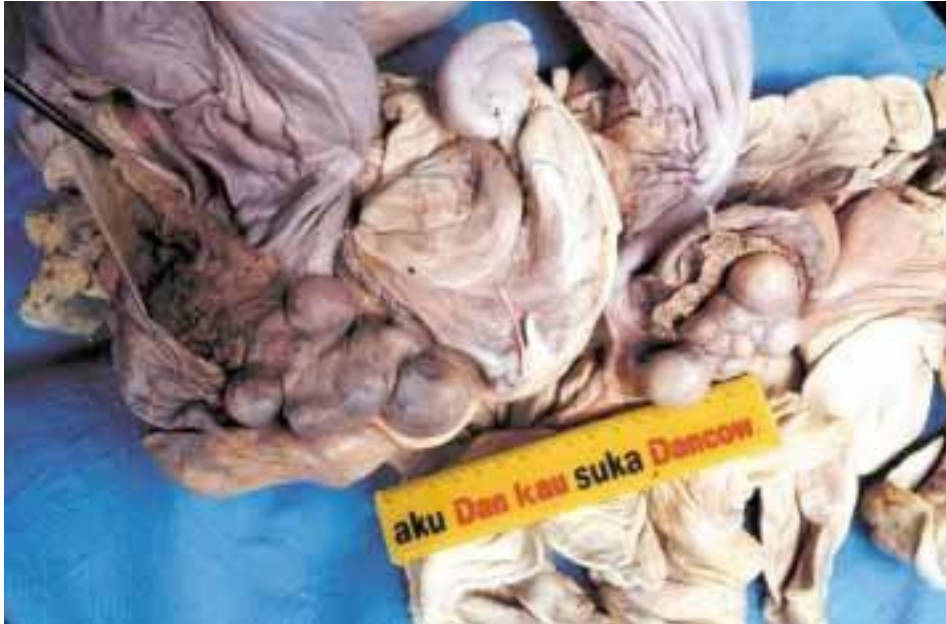

Fig. 1. “Dalu” – Both ovaries

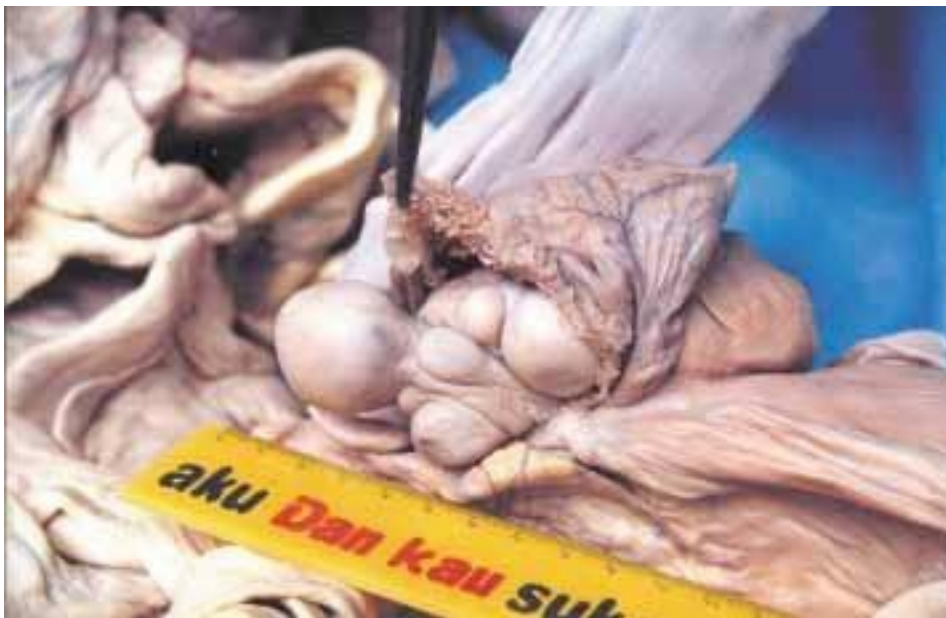

Fig. 2 “Dalu” – Ovary in Bursa

“Dalu”, Female Sumatran Rhinoceros
Bogor, Java – February 18, 1999

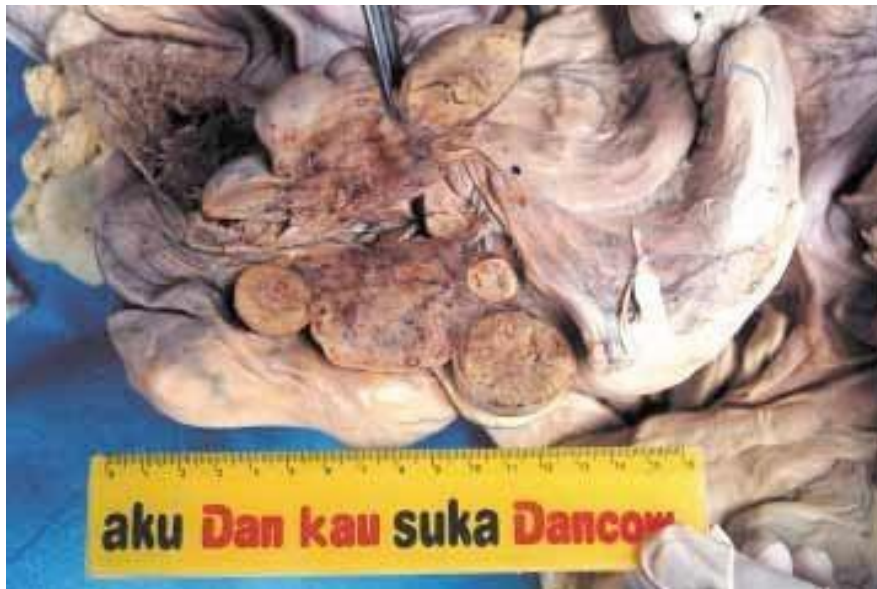

Fig. 3 “Dalu” – Numerous corpora lutea, cross section



Fig. 4 “Dalu” – Enlarged Uterine horn, cross section

b. Dalu Histology Report: J. Kinsel

COLLEGE OF VETERINARY MEDICINE
LABORATORIES OF VETERINARY DIAGNOSTIC MEDICINE
2001 S LINCOLN AVE, PO BOX U
URBANA, IL 61802-6199
Telephone : (217) 333-1620
Fax: (217) 244-2439

FINAL RESULTS REPORT

BROOKFIELD ZOO
3300 GOLF R.D
BROOKFIELD IL 60513

Caset: 99-1296 Submitted: 04/05/99
Owner: BROOKFIELD ZOO RerenDate: 04/21/99
Species: Rhinoceros Case Coordinator: J. KINSEL
Age: 4 Sex: Female

Histopathology, KINSEL, 04/21/99

Tissues from an adult, female, Sumatran Rhino are presented for histologic evaluation.

Slide 1: The grossly noted para-uterine mass is composed of a large region of necrotic adipocytes with few robust intervening fibrous tissue bands which are also necrotic, surrounded by a robust capsule of dense mature fibrous connective tissue.

Slide 2: Sections of (presumed) ovary/ovarian mass contain a large, compressive and expansile, well encapsulated mass composed of cords and nests of luteal cells with a fine reticular supporting. The stroma is well vascularized. Adjacent to this region is a small somewhat attenuated luminal structure consistent with uterine tube which has few irregular glands with one moderately dilated gland containing scant eosinophilic debris laminal and surrounded by moderate quantities of dense collagenous stroma with the (presumed) endometrium. The mesovarium/mesometrium adjacent to the mass and presumptive uterine tube has large quantities pale eosinophilic to amphophilic proteinic material between widely separated collagen fibers, and similar material is also contained within moderately dilated lymphatics (edema).

Slide 3: section of infundibulum has widely scattered small numbers of lymphocytes and plasma cells within the stroma.

Slide 4: Section of uterus has widely scattered small foci of hemorrhage within the endometrial stroma and adjacent to and also randomly distributed throughout the endometrial stroma are single or small clusters of macrophages gold/brown intracytoplasmic pigment. Occasional glands deep within the endometrium are somewhat dilated and contain small amounts of basophilic mucinous material lamina.

Slide 5: Second section of uterus has a markedly diffusely edematous endometrial stroma with wide separation of glandular elements. Occasional glands are mildly to moderately dilated and infrequently contain small quantities of lacy eosinophilic to basophilic material laminal. Widely scattered small numbers of Phocytes and rare plasma cells are noted within the endometrial edema.

Test Results Report for Case id

99-1296

histopathology: KINSEL, 04/21/99

COMMENTS:

Significant histologic lesions included endometrial edema and para-uterine adipose necrosis with mineralization.

The region of fat necrosis was well encapsulated, and not of clinical significance. Possibly this was a pedunculated lipoma with subsequent strangulation, mineralization, and fibrous encapsulation, though this could have also been simply a focal region of adipose necrosis/saponification with subsequent organization. The endometrial and mesovarium/mesometrial edema, while was of unknown cause.

The port on regularly arranged corpus luteum, though the grossly recorded presence of numerous such structures in both ovaries suggested a potential aberrant hormonal influence allowing for persistence of CLs or possibly for development of multiple CLs, though this was speculative.

MORPHOLOGIC DIAGNOSES:

1. Moderate, focal, chronic, para-uterine adipose necrosis
2. Moderately extensive endometrial and mesometrial edema ????

Pathology (Chicago Zoo)

Histopath single spec - zoo - Verified on: 04/21/99

Completed

2. Romi, Male Studbook # 30
February 18, 1999, Tamin Safari, Indonesia
Nan Schaffer, DVM

Note on Tag: Frozen thawed tissue: Died of chronic intestinal problem. Hemorrhagic gut.

Measurements of Testicles

Epididymis Tail: 4.5 x 2.0 cm
Testicle body: 11.5 x 5.0 cm
Epididymis Head: 5.0 x 3.0 cm
Anterior penis:
2 Extensions: 8.0 cm x 1.5 cm
Extensions to end of penis: 16.0 cm x 6.0 cm diameter
Tip(from fold to end of penis): 4.0 cm length x 2.0 cm diameter

E. Cincinnati Zoo, USA (1994-1995)

Summary Report of the Cincinnati Zoo Sumatran Rhinoceros Reproductive Study with
Reference to 1992 Study of Animals at Sungai Dusun Reserve, Malaysia
Report to Cincinnati Zoo, January 19, 1995
Nan Schaffer, D.V.M.

1. Rapunzel, Studbook #27

SUMATRAN RHINO FEMALE "RAPUNZEL"

Rapunzel was previously acclimated to the chute and quickly tolerated rectal palpation. A total of 12 rectals were performed in 42 days with ultrasound performed on the last four rectals. The cervix, uterus, and ovaries could be palpated, as well as sonographed. A 10cm round, firm mass was associated with the left caudal uterus (Fig. 4). It was mobile along with the uterus and could be retracted into the pelvic area. The left ovary was small, firm, and nodular on the surface. The cross-sectional ultrasound image was mottled, and one flat cyst occurred on the cranial pole (Fig. 3). The right cranial uterus had a small, hyperechoic mass (1x1cm). The right ovary was firm with several central hyperechoic densities (Figs. 1 and 2).

COMMENTS

Rapunzel did not have a dynamic follicular population that is characteristic of other cycling domestic animals. This follicular pattern was evident in two animals at the Sungai Dusun Reserve in Malaysia (see Schaffer et al., 1994). These same animals were later reported to have fluctuation in hormone levels suggesting estrous cycling (Brown and Goodrowe, pers. comm.) The lack of homogeneity of the ovarian tissue on ultrasound imaging was abnormal, and the Rapunzel's ovaries were slightly smaller than that reported for inactive ovaries (5x2x1cm) (B. Dresser and C.W. Furley, International Rhino Conference, 1993.).

This animal had at least two tumors in her uterus. The smaller tumor appeared on ultrasonography to be intrauterine. The larger tumor obliterated the uterine architecture. The ultrasound images of these tumors were similar to those of the Sungai Dusun females (see Schaffer et al., 1994).

Uterine leiomyoma have been reported in one Sumatran rhino (C.W. Furley, International Rhino Conference, 1993). These are primarily benign tumors occurring in older animals. The pendulous discolored character of the female's mammary gland suggests she is an older animal, however, other types of tumors could be involved.

Serum samples have been obtained on Rapunzel, but it has been frustrating trying to find a laboratory that can test them.

“Rapunzel”, female Sumatran rhinoceros
December 1994

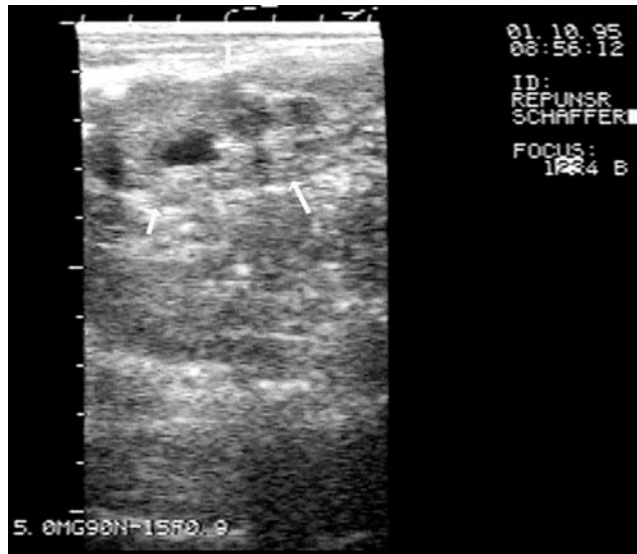

Fig. 1 “Rapunzel” Right Ovary (arrows)

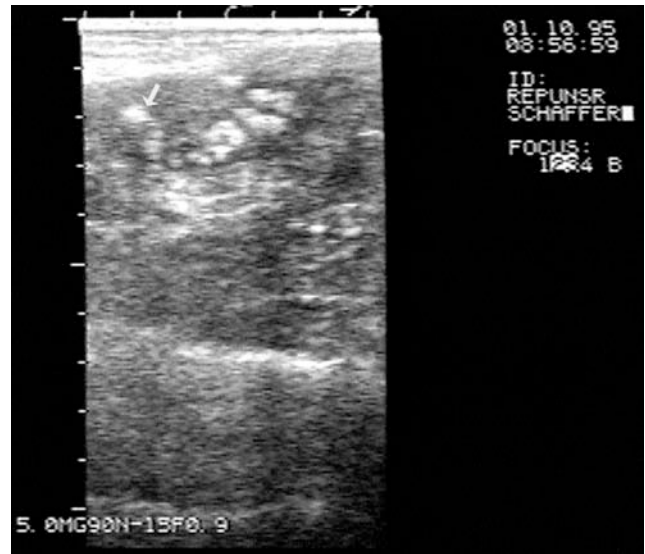


Fig. 2 “Rapunzel” Right Ovary Echogenic densities (arrow)

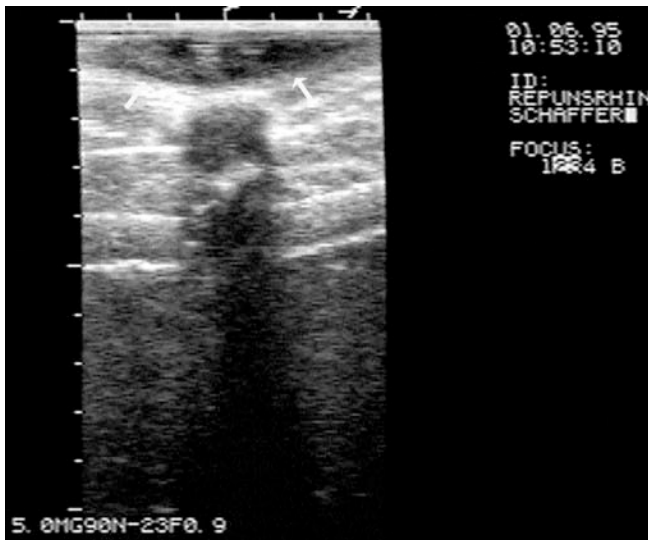

Fig. 3 “Rapunzel” Left Ovary (arrows)

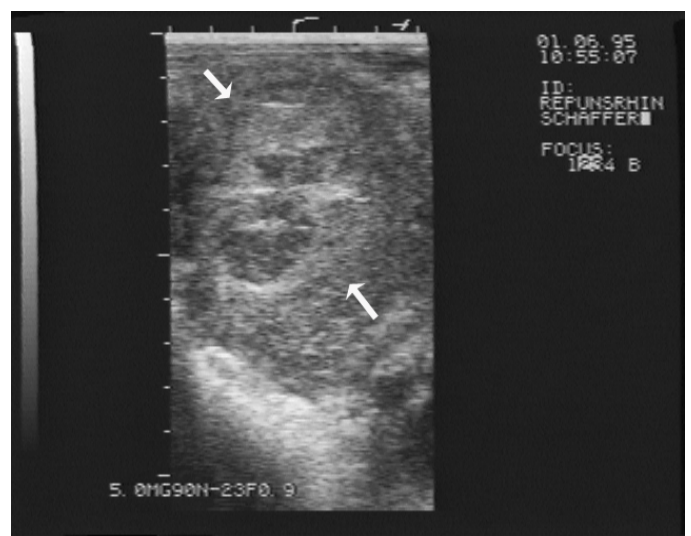

Fig. 4 “Rapunzel” Uterine tumors (arrows)

2. Bagus/ Ipuh Studbook # 28

MALE SUMATRAN RHINO "BAGUS"

Bagus was also previously acclimated to the chute. Collection of semen by manual massage was attempted 25 times in 42 days. He became rapidly disinterested. Four samples were collected (see report). They were very low in volume and sperm count. The few sperm collected were predominantly normal in morphology. All the samples had evidence of urine contamination. Although the testicles appeared to be freely mobile in the scrotal sacs, they were rarely hanging pendulously in the scrotum as seems to be the typical location in other Sumatran rhinos. Some increase in fluid accumulations was evident around the epididymis with ultrasonography (Fig.1), but not around body or head of testicle (Fig.2).

COMMENTS

The presence of sperm from the male confirms the occurrence of spermatogenesis and suggests fertility. The response to manual massage of this male was similar to other species of rhinoceros and to the one sample collected from a male at the Sungai Dusun Reserve (Schaffer, N., unpublished data). Acquiring samples for analysis took considerable time and conditioning with this male. His rapid disinterest was due in part to his decline in health toward the end of this study; however, the high frequency of collection attempts may have also been a factor.

Barbara Durrant reported that this male produced several samples when collected approximately once a week for two months. My impression from her was that these samples were higher in quality. A full report on her samples would be useful for comparison. It also may be useful to have her work on this male again, should the opportunity arise. Zainal Z. performed a few further attempts on the male at Sungai Dusun. He reported fluids with few sperm. Bagus may produce higher quality semen samples if collection methods are applied infrequently over a much longer period of time.

This male's epididymal fluid accumulation could be normal or a sequela to medical problems. Similar and slightly larger fluid accumulations were noted around the head of the epididymis of another male at Sungai Dusun in 1992 (Schaffer et al., 1994).. Swelling of the scrotum was visibly apparent dorsal to testicles of this male at the same time. Zainal Z. reported that the swelling continue to recede.

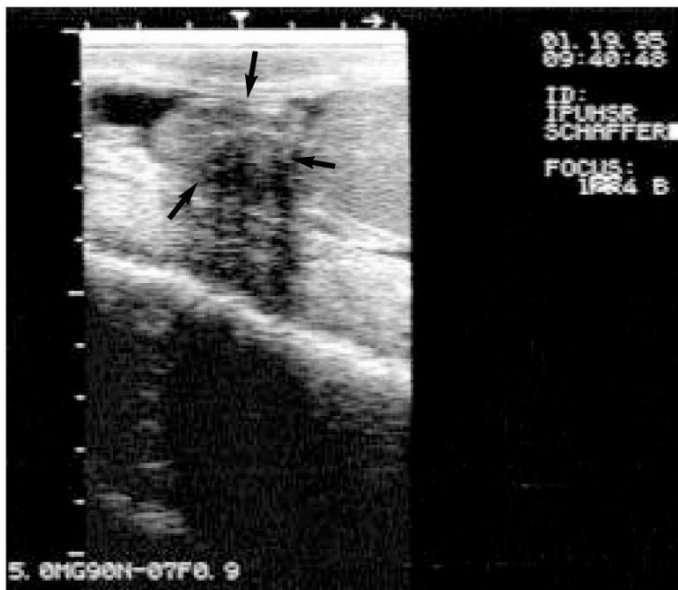

Figure 1 Tail Epididymis with Surrounding Fluid

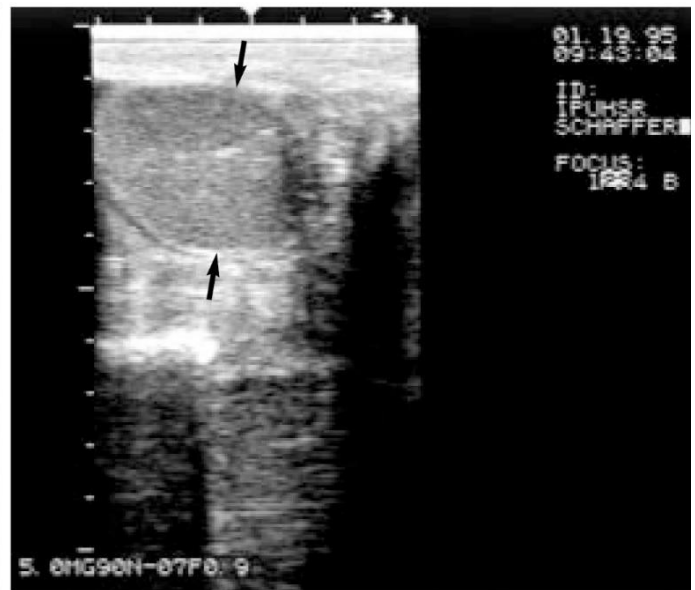

Figure 2 Testicle mid-cross section

3. Ultrasound and Penile Massage Procedures


Cincinnati Biological and

Sumatran Rhinos
1994–1995

Nan Schaffer DVM Zoological Gardens
ALS
680 N. Lakeshore Dr
Chicago, IL 60611 (312) 222-440

Rapunzel SB# 27
Ipuh SB# 28

The following are notes taken during semen collection procedures of a male “Ipuh” and ultrasonography of a female “Rapunzel”. Both procedures were performed with the animals in a chute. Both animals were fed continually by a keeper unless otherwise noted. The male was approached always from the left side (only access) and stroked on back, back legs, sheath and stomach. He never responded to stroking with penile erection. The following is a chart indicating the level (stage) of erection he could achieve. He never became fully erect (stage 5). Medical problems may have been a complicating factor (see records).



- | | |
|---------|---|
| Stage 1 | Penis in sheath |
| Stage 2 | Let to opening of sheath |
| Stage 3 | Bottom let down before glans rotate forward |
| Stage 4 | Erection |
| Stage 5 | Forward erection, projections engorged |

(*---- cumulative minutes)

Wednesday, November 30, 1994 “Ipuh”

10 am: Vets-3; CREW-3; Nan and Julie; Keepers-Steve and Paul

Ipuh: hungry, in chute being fed

Response: stroked legs, stomach, sheath

5 minutes: no response (penis high and tight in sheath), also both testicles high, at inguinal ring

11 am: same

Ipuh: fed middle stall

Response: Steve strokes down with stick and rubbing back legs. I am on side trying to get penis out by rubbing sheath. Few drops squirt onto floor (wipe up with finger onto slide- dries out) and some into cup (sterile specimen). Ipuh gets up, we leave stall.

Lab: Wash with 0.5 cc saline. Sperm in wash (20), save for stain. Heads normal, no cytoplasmic droplets. Some curled tails 5/20

30 µl in 2nd cup-squamous cells 50/HPF (high power field). CaCO₃ crystals dumbbell 100+/HPF

1:30 pm: keepers-Steve and Paul; Nan and Julie

Ipuh: in chute eating ficus

Response: stroked legs and belly caused some relaxing to opening of sheath- stage 2. Then worked penis out until forward-stage 4. Some shifting by rhino so quit.

~5 min.: to full erect, 10 min.-stroking to quit

No semen, no fluid

December 1, 1994

9:30 am: keepers-Steve and Paul; Nan and Julie

Ipuh: in chute eating ficus

Response: stroking abdomen and legs to no effect, reached into sheath rubbed tip and behind projections and pulled down until penis out of sheath; applying KY produced full erection-stage 4. One squirt on coveralls when penis retracted. No further attempt.

10 min.: stroke to quit

No semen

1:30 pm: keepers-Steve and Paul; Nan and Julie

Ipuh: eating in chute ficus

Response: stroking gives no response; enter sheath and pull penis down; applying KY and squeezing tip induces erection. Quit when losing response to rubbing.

8 min.: to full erect forward-stage 4

12 min.: stroke to quit.

December 2, 1994

9:30 am: keepers-Steve; Nan and Julie; Vets-Ken and tech

10 am:

Ipuh: eating ficus in chute

Blood collection tail vein; butterfly catheter on angio sleeve with collection tube; took it well.

10:30 am:

stroking no response, reached up sheath to pull down

5 min.: to full erection-stage 4; some thrusting, rubbing tip faster maintains erection, 2 thrusts forward

10 min.: stroking to quit

12 noon:

Ipuh: in chute eating

Penis tight in sheath must pull down, difficult to work down to stage 3, but then he takes over himself by pumping tip of penis into full erection stage 4; I maintained erection by tapping penis on belly and squeezing tip. Quit with loss response.

8 min.: to forward erection-stage 4

12 min.: stroke to quit

December 5, 1994

8:45 am: keepers-Tom and Steve; Nan and Julie

Ipuh: eating in chute, calfmana, ficus; lying in middle cage before working; 16 breaths/minute;

Rt. testicle: 1/2 in scrotum; Lt. testicle: at inguinal ring

Response: no response stroking body; penis tight in sheath; brought down by stroking and pulling; KY encourages let down; full erection in 13 min.-stage 4: extending further forward

No semen: in smears of tip; felt like squirted on hand: no sperm

16 min.: stroke to quit

1:30 pm: Keeper-Tom

Ipuh: eating ficus in chute

Response: testicles and penis high and tight; penis pulled down

15 min.: to first erection stage 4; stopped for 3 min. to relax penis no fluid with squeezing tip
5 min. of stroking to second erection stage 4, some extending of alars
23 min.: stroke to quit
Behavior Note: erections A.M. on Saturday and Sunday

December 6, 1994

8:15 am: Keepers-Paul and Steve; Nan

Ipuh: not fed, shifted in chute while waiting, full urination (clear yellow) in chute, fed medication in bananas- the only food given

Response: penis loose from urination, worked out quickly to stage 4 in 3 min. then feeding stopped, Paul distracting him.. He became agitated, retracted to stage 2. Worked with KY for 10 min. but still agitated nothing past stage 3 so stopped and just held penis then 5 min. to stage 4 by only squeezing tip. Penis erect some engorgement of alars. Let penis relax to stage 3 and squeezed out a few drops (1st).

18 min.: vigorous massage tip brought him up again increased e. Enlargement alars. Some thrusting and leg movement (kicking)

Let relax to stage 3 then some flows of clear fluid (2nd) with massaging tip. Worked him one more time, but slower to come up and no fluid with relax.

25 min. total

Lab: 1st-1.2 cc clear, brown tinge; CaCO₃-10 /HPF dumbbells; white mucus; pH 8.5 2nd 12.0cc, clear, CaCO₃-2 /HPF dumbbells, pH 7.5, spun-850 g 10 min.-no sperm in pellet saved supernatant froze in 1 orange 15cc centrifuge and 2 nunc vials.

1:00 pm: Keepers-Steve and Paul

Rapunzel: into chute, eating ficus, head at door to stall. Squeezed to maximum extent, but could still rub tail against posts. Considering removing part of sliding door and putting pad inside chute to hold rear over to right side.

Response: holding and pinching tail, rubbed between legs, relaxes tail when rubbed legs and slowly entered rectum. She stopped eating for 5 seconds when hand was inside anus , felt around and picked up feces and brought it out.

1 0 minutes total

1:30pm:

Ipuh: stage 2 to stage 4 with vigorous rubbing - 8 min. squeezed during relaxation-no fluid to stage 4 again 5 min. relaxed- no fluid to stage 4 again 8 min. relaxed- no fluid

21 min. total

December 12, 1994

10:00 am: Keeper-Steve and Craig Reece; Nan

Ipuh: eating ficus and calf mana

Response: No response to stroking (has not responded to stroking since started) have to reach up and rub and pull penis down; 3 min. to stage 3 and drops of white chalky fluid on wet floor put on slide for analysis

One drop into cup

15 min.: to stage 4, relaxed(usually gently squeezing while relaxing)- no fluid

5 min. to stage 4+, relaxed- no fluid

5 min. to stage 4+, relaxed- no fluid

5 min. more, reduced response

Not quite max. response as seen on December 6; some shaking of back legs

Lab: Samples were a mixture of CaCO₃ crystals and similarly sized round clear structures(amorphous phosphates or drug deposits?)- both dissolved with acetic acid.

Rapunzel: eating ficus

Response: allowed lifting tail and pinching; but increased sensitivity to touching anus; not

responding to stroking between legs. Able to get gloved hand in with KY but more difficult and more shifting and stomping by her, rectum filled gas.

5 min. total with 30 secs in rectum

2:00 pm: Keepers-Steve and Craig; Students/Interns-Janet and Becky; Nan

Rapunzel: eating ficus

Response: stroking between legs and pulling udder relaxed tail; able to get inside and pull fecal out but won't let in again (lots of stomping and shifting); Stopped eating when hand entered anus then continued 12 min. total

Ipuh: eating ficus and calf mana

Response: loose to begin but pulled up tight with contact; reluctant to come down

10 min.: start to stage 3

*15 min.: to stage 4

about 3 min. rubbing at stage 4 then relax for 3 min.- no fluid with squeezing

Note: noticed round bulge between cavernosum and glans penis about 1 cm diameter right lateral

* 20 min: to stage 4+ some fluid on relax

* 25 min: not responding, quit

Lab:2.4 ml slightly cloudy, viscous fluid; pH 8.0; transitional cells; very few WBCs; no amorphous phosphates (see above)

December 13, 1994

9:30 am: Keeper-Paul; Nan

Rapunzel: into chute, squeezed, eating

Response: stroking, pinching tail; sensitive just below anus and just below vulva; stopped eating 30 seconds; opened vulva several times; vulva mucous membrane-red pink

In rectum up to mid-forearm; cervix over brim of pelvis and off to left; bladder full; no feces; 2 minutes in rectum trying to pick up cervix; some movement from her

Went in again to wrist; no problem; much more relaxed

* 6 min.

9:50 am:

Ipuh: in chute eating from Paul

Response: stroking rectum and down base of penis; down legs, along stomach, squeezed testicles; stroking 5 min.; no response penis

Testicles: left- high; right at penis stalk; both are a bit soft, tail epid. not prominent (usually bulbous); reach to get penis down, rubbing for 5 min.: stage 2 to stage 3, few drops urine

*15 min.: to stage 4, only stays briefly, relax-no fluid

*20 min. to stage 4 again, relax-no fluid

*23 min. to stage 4, relax-no fluid

*25 min. to stage 4, relax-no fluid

*30 min. to stage 4, relax-no fluid

35 min. total

Working on base of penis causes pumping of glans, but as soon as squeeze tip he loses erection; just holding penis sometimes he will continue on his own, May need warmth stimulation at this point; he does respond to wet (KY), bring in bucket warm water

Box of ficus: 30-60 lbs.

1:00 pm: keeper-Paul

Rapunzel: slow to enter, did not like warm water wash of vulva (water hitting legs); also didn't get very far with hand, fingers only

Ipuh: not in mood; hard to get down, won't come forward, stopped eating

4 min. total, quit

December 14, 1994

7:15 am: Keeper-Paul; Nan

Ipuh: reluctant to go into chute

8 min.: won't respond past stage 2, kicking not eating, no KY

Rapunzel: also reluctant to enter chute

3 min.: no KY, quit

11:30 am: Keeper-Paul

Ipuh: reluctant to go into chute

5 min. to get out of sheath

*10 min. to get to stage 3

*13 min. to stage 4 weakly once; plenty KY

*14 min. loses erection with warm water wrap of penis

December 19

9:45 am: Keepers-Tom and Steve

Rapunzel: eager to get into chute; hungry, squeezed, not as jumpy, not responding to rubbing between legs; rectum filled with gas and some feces; up to elbow and trying to pick up cervix which was very flaccid and over brim

10 min. total

Ipuh: entered chute, no problem, eating ficus and calf mana, stroked around rectum, testicles hanging lower especially right was almost down into scrotum, left was even with penile stalk

*5 min.: Penis started at stage 2, responded at first then took 5 min. to stage 3

*10 min.: to stage 4, then relax 3 min. recovered erection to stage 4 with vigorous stimulation of glands

*16 min.; 2 erections to stage 4 in 10 min.

30 min. total

Recovered urine with bag over tip of penis; spun into pellet; CaCO₃ dissolved with dilute acetic acid; pellet was brown debris and cells

1:30 pm: Keeper-Tom and Steve; Tom feeding

Rapunzel: reluctant to enter chute

Response: stroke between legs no response; lots feces in rectum

5 min. in rectum

Ipuh: entered chute, stroked around rectum and legs 3 min.; no response; reached in sheath to get penis; very slow to respond;

*13 min. to stage 4; stopped to relax penis 3 min.; tried variable vibrator low level on glans- side, top, base of penis; penis quickly (1 min.) came to full stage 4 with 3 pumps by animal then lost quickly 2min.; applied direct 3/4 vibration on glands applying off and on; took about min. for erection to start from stage 2 to stage 4, but weak and lost quickly; responded again to massage but only to stage 3 in 4 min.

26 min. total

1 drop; had a lot of cells; mostly transitional

December 20, 1994

9:30 am: Keepers-Paul feeding, Steve

Rapunzel: reluctant to enter chute, eating ficus

No change in vulva since beginning; no feces in rectum; up to shoulder sweeping gut; large, firm mass that is free and can be tucked into pelvis ~10cm

Ipuh: entering chute, eating ficus

Reaching up sheath there is a lot of dirt and hay; inside sheath seems rough, base of penis has red 1 mm blisters, also one on right lateral glans big enough to feel 3mm, also scratch on wing; may be reacting to KY

Response: 8 min. to stage 3 with very gentle rubbing;

* 12 min. to stage 4 at which point I applied vibration 1/2 power intermittently to tip. Pulsing of penis occurred and it became more engorged but began to retract, gentle rubbing brought him to stage 4 then with vibration at full on he demonstrated some long thrusts, 2 pumps of the tip and wings became almost fully engorged

*15 min. to stage 5

Vibration: didn't work at stage 1-3 and prolonged (30 sec) continuous vibration of tip was counterproductive, vibration of other areas to no avail.

Best: at peak erection to squeeze and vibrate tip intermittently; no fluid with milking at stage 3; rinsed with cold water to try to get KY off; flushed sheath which he didn't like.

1:30 pm: Keeper Paul

Rapunzel: reluctant to go into chute; agitated with palpation; had to work around feces; sweeping low to left, could pick up large orange size mass at least 10 cm maybe more, felt like uterus could bring freely into pelvis; smooth except for bumps at edges; feels like it has an attached border

Ipuh: giving break

Skin on Rapunzel has 2mm holes in skin on back, dead skin falls out, pale pink skin or pus underneath; reaction to mineral oil?; reaction to A&D?; Ab?

December 21, 1994

Am: Keeper-Paul and Steve

Ipuh: Lying in stall, gets up and slowly walks into middle stall, one squirt into original stall, but can't locate before he urinates, found some clear thick fluid in stall which collected with some urine on floor; no sperm

He went immediately into stall; head toward door, I worked from squeeze door side; both testicles were in scrotal sac; penis was at stage 2; With pulling penis down he reached stage 3 in 4 min. With gentle milking of tip and base;

*7 min. to stage 4; wings also getting engorged; tail raised to 45° ; some leaning forward; 2 pumps with tip; penis relaxed; beginning again at *10 mins.; when urine flows onto floor from penis about 1.0cc then induce almost full erection and stopped to get another vial;

*15 min.: working from stage 3 get flow of urine into vial. 2 cc; then losing interest getting agitated and restless, knocks door open.

18 min. total

January 4, 1995

9 am: Keeper-Steve

Ipuh: in chute not allowed to eat, lot of movement seems thinner

Response: none to rubbing skin; reaching up sheath and pulling; massaging brings penis down after 10 min.; responses well to KY; at first let down some squirts urine;

*15 min. to stage 4; 2 pumps; lose quickly; rinsed penis with cloth; not responding; going to vibration.

20 min. total

No sperm in squirts

2:00 pm: Keeper-Paul

Rapunzel: in chute but a corner is rubbing her sides, needs modification Response: filled with gas and feces making it difficult to pick up tract; cervix feels firmer; able to get mass into pelvis; same size.

10 min. total

January 5, 1995

7:45 am:

Ipuh: in chute towards solid door, tried brushing with scrub brush; back feels warmer than belly; still bits of skin falling off. Calmer with brushing back, sides, between legs, but no response penis; he is very sensitive around tail; testicles are in inguinal ring.

PM:

Rapunzel: ultrasound, right ovary then left and mass

January 9, 1995

AM: Keepers-Tom and Steve

Ipuh: loss of weight 1400 to 1320, off isoniazid due elevation liver enzymes; looks thinner
Response: up tight, stage 1, had to pull down hard, worked base and tip rinsed warm water, retracted then had to work up again;

15 min. to stage 4; put on latex funnel and 2 headed vibrator at low underneath and against tip.
He lost erection but engorged

*18 min.; then stopped and manually squeezed which brought him to stage 4; applied vibrator to tip hard ~30 sec, he began thrusting and straining and reached full forward stage 4 but flaps not fully engorged; alternating vibration~5-10 sec and rest 15 sec; noted 1.1cc clear fluid with yellow tinge in vial at tip of funnel

* 25 min.: Stopped to relax penis, another squirt at stage 3, 30 min. total

Lab: pH 9.0, 1.1cc, 2 sperm folded with normal heads, one detached normal head; very few CaCO₃ crystals lots of tiny debris (1 mm at 40x)

January 9, 1995

AM: Keepers-Tom; Vet-Mark Campbell and tech; Nan

Rapunzel: eating

Ultrasound; Mass attached uterus probably involves lumen and connected cranially to 2 cysts within uterus--slightly lytic, not well organized like fibroma hyperechogenic tumor right cranial horn

1st on tape left ovary is small, firm, nodular, mottled cross-sectional image

2nd on tape right ovary is small, firm, with several central densities and a flat cyst on the cranial pole

Need hormones: fecal? serum TE and estradiol

January 10, 1995

8:30 am: Keeper-Paul

Ipuh: does not like rectal; feces is yellow pasty and smells acidic; 2° glands seem small

1:30 pm:

Rapunzel: eating more relaxed

US-primarily right side, left at end tape

January 11, 1995

8:30 am: Keepers-Steve and Paul

Ipuh: eating banana slowly; taking palpation better than yesterday

US: 2° sex glans, seemed small and difficult to distinguish the different glands, ~ 10 min. total

Note: started banamine® Ultrasound tape record:

9:05:11 dense triangular prostate at neck bladder very little seminal vesicle

9:06:49 urethra and at 9:06:05

9:07:21 bulbourethral: large vessel begins

9:07:57-8:13 and 9:11:18-11:57 bilateral echolucent (paired) between what appears to be bulbourethral glands.

January 12, 1995

8:30 am: Keepers-Steve and Paul

Rapunzel: jumping around; anus tight; had to pull out feces 3x; she didn't like at all US: picking up right side (1x2cm) mass on cranial end and densities in body
~15 min.: had to stop; jumping around too much.

January 19, 1995

9:30 am: Keeper-Paul; Vet-Mark and tech

I Ipuh: slow to get up and move into chute, stood very quietly, ate a few bananas

US: both testicles were high in scrotum, fluid accumulation was apparent around tail of epididymis; Left side first then right 7 min. total.

Ipuh coming non responsive and too weak to continue. Steve is going to talk to Director about nutrition.

Note: Jan. 1998 T. Roth Post-Coitus Collection Semen Parameters

130 ml, pH 7.8, $\sim 6 \text{ sperm/ml} \times 10^6$, total sperm 780×10^6 , motility 60%, normal morphology 40 %

III. Addenda Reports 2000-2006

A. Sabah: Poached Female Rhino

1. Unknown Female (N. Schaffer, A. Kilborne, 2001)

B. San Diego Zoo Necropsies:

1. Barakas Studbook #25
 - a. Necropsy (L. Lowenstine, 1995)
2. Rami Studbook #33
 - a. Necropsy (B. Rideout, 1992)
 - b. ART (R. Pope, 1992)

C. Treatment bases for Leiomyoma (J.C.M. Tisbris, 2000).

1. Poached Female Rhino, Sabah, Malaysia 2001

Gross Reproductive Tract and Images

Analisa Kilborne, SOS Rhino

A SUMMARY REPORT: POSTMORTEM EVALUATION OF 0.1 WILD SUMATRAN RHINOCEROS' REPRODUCTIVE TRACT AT SEPILOK, SABAH, MALAYSIA.

A wild female Sumatran rhino (*Dicerorhinus sumatrensis harrissoni*), died on March 10th, 2001. The cause of death due to gun shot wounds was confirmed (see detail JHL report). Her reproductive tract was analyzed in greater detail at a later date to correlate to findings in short and long term captive Sumatran rhinoceros.

Gross Post mortem evaluation of reproductive tract:

Figures: O - ovaries, T - tumors, C- cervix, E - endometrium

Uterus:

Left Uterine horn

1. A solid/ firm/ uniform in texture white mass (5 cm in diameter) with 2-3 small (2-3mm) internal cyst-like structures and a smaller mass (2x3 cm) was present within a fluid filled cyst-like structure within the wall at the tip of the left uterine horn-suspect a myofibrroma/ fibroid/ leiomyoma.

Right Uterine Horn

1. Two additional masses were located near the bifurcation of the uterus. The first was white, firm, and uniform in texture within the uterine wall and measured 2-3 cm. The second mass was similar in texture and color but smaller (1cm) and pedunculated from the uterus. Another was closer to the right ovary (1.5 cm).

Uterine Body

1. Several very small 0.5 cm, some pedunculated, fluid filled structures were seen in the lumen of the uterus.

Ovary

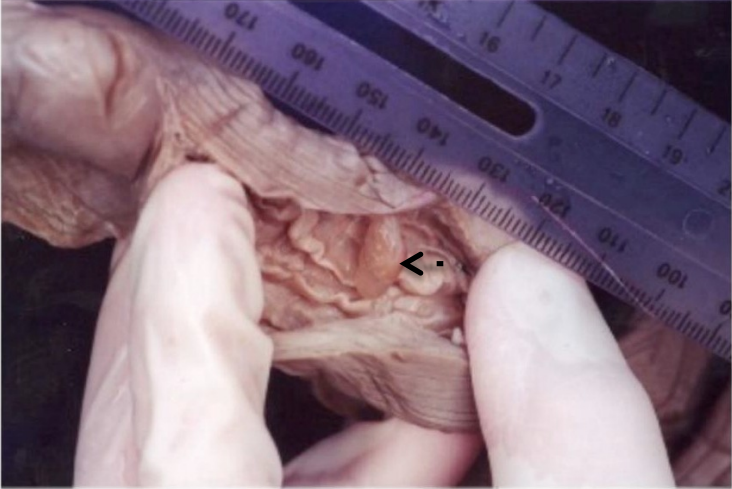
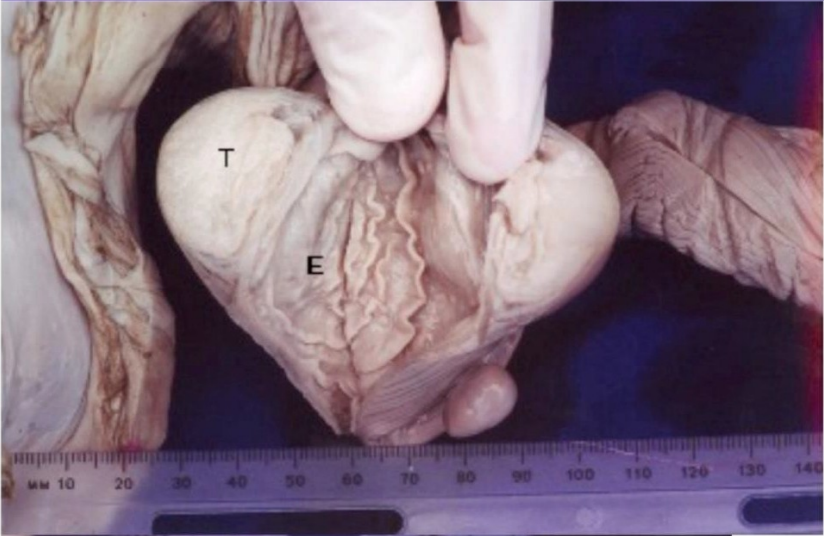
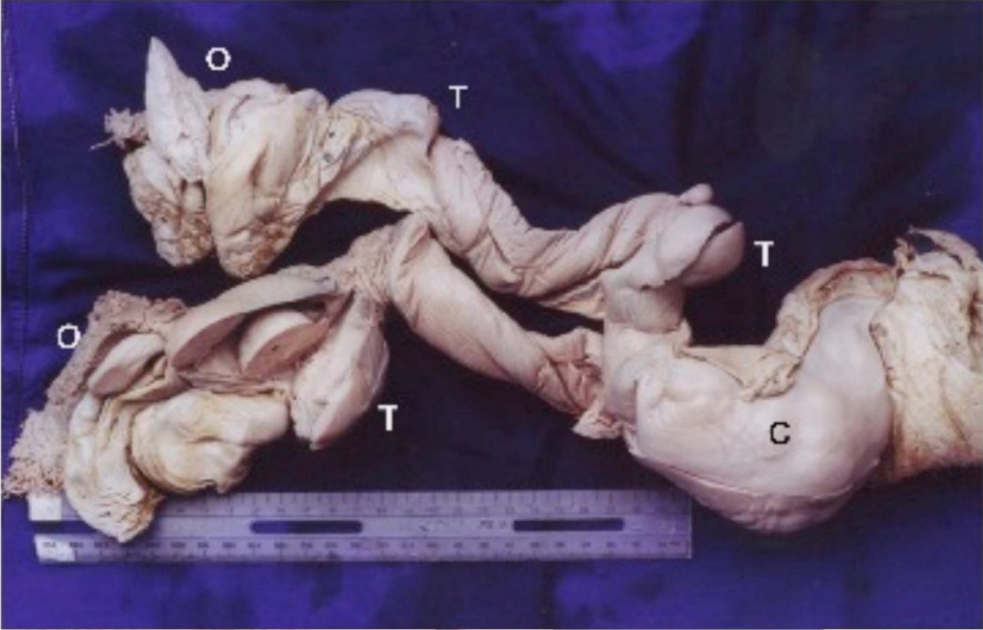
1. Right – several small cystic structures (antral follicles)
2. Left – similar cystic structures

In summary:

Pathology had been reported in captive female Sumatran rhinoceros. The pathology noted on this post mortem was similar and significant and most likely would have interfered with successful pregnancy and implantation. Myofibromas are suspected and are not uncommon in other species of older, non-breeding cycling females such as is the case in humans.

Samples have been submitted for further histological investigation to the department of pathology in Kota Kinabalu (Jabatan Haiwan) and the San Diego Zoological Gardens pathology department.

Poached Female Rhino, Sabah, Malaysia 2001 Nan Schaffer
O-ovaries, T -tumors, C- cervix, E - endometrium



2. San Diego Zoo Necropsies

a. Barakas SB #25

Zoological Society of San Diego
Necropsy Report

Page:

Species: DICERORHINUS SUMATRENSIS SUMATRENSIS Necropsy #: 0034965
Common SUMATRAN RHINOCEROS Accession #: M0588440

House BARAKAS-KUMU Death Date : 1995/02/22
Sex Female ID: NO ID Birth Date : 1988/07/24
Age 6 Yrs 6 Mos 29 Days Prosector DR. LINDA LOWENSTINE

Enclosure HOSPTL Histologist DR. LINDA LOWENSTINE
Endangered USDI- E CITES- 1 Necropsy Date: 1995/02/22

Preliminary: 1995/02/22 Carcass Disp.: Given to Coded Instit.
Final Date : 1995/12/15

HISTORY: This rhino was part of the SDZ, Rhino string. Medical summary, provided by SDZ Veterinary staff, has been microfilmed. Body weight on 95/02/20 was 412kg. Health problems from 94/09/27 to date. Okay housing conditions. Recent diet changes. Appetite decreased. Wild caught. Euthanized due to medical problems on 95/02/22. Submitted by P. Morris, DVM. Body received by Pathology on 2/22 at 11:30 AM and necropsied immediately. Drs. Rideout and Stalis assisted Dr. Lowenstine.

PRELIMINARY GROSS DX:

1. Euthanasia, medical
2. Cachexia and muscle atrophy, severe
3. Diffuse renal fibrosis with loss of lobular detail suggestive of chronic interstitial nephritis
4. Probable endogenous pneumonia and/or pulmonary fibrosis, bilateral, dorsal lung fields
5. Chronic pericarditis and epicarditis, mild
6. Valvular hemocyst and serocyst, mitral valves
- ? Nodule associated with the liver hilus (organized hematoma?)
- B. Cystic structures associated with the left jugular furrow and the caudal mediastinum, lymphangiectatic
9. Multiple submucosal lipomas at the ileocecal junction (normal anatomic feature?)
10. Distended hepatic lymphatics
11. Orange discoloration of the liver, intestinal mucosa and lymph nodes suggestive of hemosiderosis
12. Uterine endometrial cysts, one in each horn and multiple at the opening of the salpinx
13. Degenerative joint disease, mild (?post traumatic), left stifle

EXTERNAL EXk /INTEGUMENT:

Presented for necropsy is an adult female Sumatran rhino. The postmortem interval is approximately 30 minutes. All bony prominences and ribs are clearly evident, indicating poor nutritional condition. On the right side of the neck is an unsutured "T" shaped incision from a jugular "cut down" procedure. The skin over the dorsal surface of the face, neck and back is very thick, hyperkeratotic and finely fissured, giving it a reticulated appearance. There is extensive scaling and peeling of superficial

Species: DICERORHINUS SUMATRENSIS SUMATRENSIS
Common : SUMATRAN RHINOCEROS

Necropsy #: 0034965

epidermis over the back and sides. Over pressure points, the skin is thinner and more lightly pigmented. The skin of the ventrum and medial limbs is thin and pliant. The proximal half of the tail is thickened and warmer to the touch than the more distal portions. Incision of the tail skin reveals white, fibrous tissue with prominent vessels and plump muscles without edema or hemorrhage (per A. Sawyers). The base of the horn is pitted and longitudinal fibers are separated and broken. There is no dermal or subcutaneous fat anywhere on the body. There are two large inguinal teats. Mammary gland tissue is rudimentary. There is some thickening and fissuring of the plantar pad at the junction with the nails on all four feet. Waxy, dark brown, malodorous secretion is present between toes and in the fissures, but no discrete pedal scent gland is found.

There is a small amount of mucus at the nares and a small amount of dried matter at the medial canthus of the eyes.

THORACIC CAVITY/RESPIRATORY AND CARDIOVASCULAR SYSTEMS:

Within the thoracic cavity, all viscera are positioned normally and there is negative intrathoracic pressure. The anterior mediastinum is complete. The diaphragm is complete, but at the sternum is fibrous and thin and curves anteriorly to meet the caudal mediastinum which is also complete. (This area was probably where there appeared to be a hernia on ultrasound.) There are fine fibrous adhesions between the anterior lung lobes, visceral and parietal pleura. The lungs collapse partially on exposure to ambient pressure. Lobulation is distinct ventrally and less so dorsally. Lungs vary from light pink to dusky plum colored. The dorsal medial aspects of both lungs are whitish pink on cut surface suggesting endogenous lipid "pneumonia" with denser white bands of possible fibrosis (photos). The cut surface is dry. In the rest of the lungs, the cut surface varies from red to orangish brown and is dry. Trachea and bronchi are free of exudates and foam. Internal nares contain no exudates. Guttural pouches are poorly defined (unlike horse and tapir).

The heart is large, conical and is in systole. There is a 6 x 5 x 4cm, clear fluctuant loculated mass full of clear colorless fluid (Sp Gr 1.007) that is attached to the caudal aspect of the left atrium in the caudal mediastinum near the pulmonary veins (lymphatic cyst? or serous atrophy of fat). There are many tough fibrous adhesions between the epicardium and pericardium, especially over the right side of the left ventricle and anteriorly around the great vessels. (These do not appear to be extensive enough to constrict cardiac motility.) There is abundant coronary groove fat. This and the retrobulbar fat pads are the only adipose tissue remaining in this animal. Heart weight and measurements are below. There are two clear loculated cysts approximately 0.8cm diameter on the mural leaflet of the mitral valve and one reddish cyst on the septal leaflet

Species: DICERORHINUS SUMATRENSIS SUMATRENSIS Necropsy #: 0034965
Common : SUMATRAN RHINOCEROS

(photos). There are a few white circular foci on the intima of the aortic outflow (early arteriosclerosis?). There are occasional plaques on the intima of smaller arteries, such as carotid near the brachiocephalic trunk. In the aorta and rest of the arteries examined, the intimal surface is roughened, but shiny with either a reticular or corrugated pattern.

ABDOMINAL CAVITY/DIGESTIVE SYSTEM:

Within the abdominal cavity, all viscera are positioned normally and there is virtually no omental or mesenteric fat. The peritoneal surfaces are opaque and the peritoneum rubbery (normal for "mega vertebrates"). There is a peritoneal fold caudal to the muscular attachment of the diaphragm (this may have created the laparoscopic impression of a diaphragmatic hernia). There is a small amount of clear peritoneal effusion (Sp. Gr. 1.010; 3+ protein; 3+ blood) and a blood tinged, fibrin clot is present.

The dentition is symmetrical with 7 upper cheek teeth, a broad short lateral incisor and a tiny canine partially protruding from the gum on each side. On the bottom there are 6 cheek teeth, a 7th cheek tooth palpable under the gum, a small ulcer just lateral to the midline, and a small, barely erupted, lateral incisor. The anterior aspects of the caudal cheek teeth overlap the caudal aspects of the ones anterior to them on the lateral side. There are fairly long and very sharp points on the medial aspects of the 5th and 6th cheek teeth on the lower arcade and on the lateral aspects of 3, 4, and 5 on the upper. There is moderate gingival regression, especially around the 7th upper cheek tooth. There is moderate dental calculus which can be easily scraped off, except where islands of tartar are embedded in gum tissue. There is bilateral linear granular thickening of the buccal surface of the cheeks along the incisors. The parotid papillae are prominent and there are many large buccal minor salivary glands. On the lateral right surface of the tongue is a circular puckered hard (mineralized) white scar.

The stomach is characterized by the presence of an anterior squamous portion and a caudal glandular portion with a sharp smooth demarcation. The stomach is distended by mixed digesta including cubes of vegetable matter and clipped hay or browse with a fermented silage like, acidic odor. The pylorus and sphincter are indistinct. The duodenal mucosa is arranged in a series of plicae. The mucosa of the entire small intestine is orangish brown (hemosiderosis?). The distal ileum has a 1cm wide band of squamous mucosa at the ileocecal valve (photos). At the cecocolic junction (2-3cm from the ileal orifice), there is a chain of large firm irregular multinodular, light tan, submucosal masses measuring approximately 18cm in total. The masses are composed of coalescing nodules arranged along the base of a ridge like fold of tissue that marks off the entrance to a separate ceca

Species: DICERORHINUS SUMATRENSIS SUMATRENSIS Necropsy #: 0034965
Common SUMATRAN RHINOCEROS

pouch at the cecocolic junction. The pouch is 10-15cm diameter x 15-20cm long. These masses greatly elevate the mucosa, but the mucosa is freely movable over the surface of the masses (photos). The muscularis in this region of the GI tract is relatively thin and it is difficult to discern whether the submucosal masses infiltrate the muscularis. On the cut surface, the nodules are homogenous cream-colored and have a faint pattern. The cut surface exudes a small amount of clear oily fluid when cut. The nodules resemble firm adipose tissue and all sections float in formalin. There is also a similar, but much smaller (approx. 0.5 x 0.3 x 0.4cm), submucosal mass separated by approximately 2cm from the main masses and closer to the ileal opening (photos). The cecum contains watery granular, normal appearing digesta. The cecum is more globoid than in a horse. The large colon is not as long as in a horse. The rest of the intestinal tract is unremarkable.

The liver is somewhat smaller than expected and is dark red brown with prominent gray vascular markings on the capsular surface (lymphatics) (photos). There is a firm to hard, dark yellowish brown, reiform mass adherent to the liver near the hilus. This mass is dry on cut surface. It measures approximately 9 x 3 x 3cm (photos). Upon sectioning, a cystic space with clear fluid (Sp. Gr. 1.006) is found (hematoma?). The pancreas is somewhat solid (less diffuse than in horses), but distinctly lobulated.

UROGENITAL SYSTEMS:

The kidneys are covered by dense gray white, fibrous capsules through which lobulation is vaguely discernible. The biopsy site cannot be identified. The kidneys are firm when cut. The cut surface is finely and uniformly streaked with gray foci. The cortices are greenish tan and the medulla short and pinkish white. Rare pinpoint cysts are appreciated. The bladder is somewhat distended by pale urine with grayish turbid sediment (Sp. Gr. 1.007; pH 7.5; 0 protein; 0 ketones, 0 urobilinogen; 0 bilirubin; 0 blood; CaCO₄ crystals). The genital tract is removed for measurement, photography and harvest of preantral ova by Dr. B. Durrant. Several endometrial cysts, including ones near the opening of the salpinx, are noted. The ovaries are smooth and tan with a few scattered, barely discernible, gray lmm cysts.

HEMATOPOIETIC/LYMPHOPOIETIC SYSTEMS:

There is no lymphadenopathy, in fact many of the nodes are smaller than expected. In the axillary and inguinal areas there are clusters of many small lymph nodes. Nodes throughout the body are either tan with dense white capsules or dark reddish brown (hemosiderosis?). There is a multiloculated ovoid mass in the caudal neck along the cervical lymph node chain (lymphangiectatic lymph node?). The spleen is large and the

Species: DICERORHINUS SUMATRENSIS SUMATRENSIS Necropsy #: 0034965
Common : SUMATRAN RHINOCEROS

hilar surface extensively creased and folded, giving this surface a villiform pattern (photos). There are several smaller accessory spleens in the adjacent mesenteries. The marrow cavity ends before the metaphysis, at approximately the midpoint of the third trochanter, tapering abruptly to a point.

ENDOCRINE:

The thyroids are flat lobulated, dark brown structures connected by a "V" shaped isthmus. The left is larger than the right. Sectioning of the left thyroid revealed two spaces containing mucoid yellow, slightly opaque fluid (cultured). Several small, tan to pink nodules both anterior and posterior to the thyroids are collected as possible parathyroids (some may be lymph nodes or accessory thyroid nodules). The adrenals are large and the cortices tan striped with brown and gray. The cortex:medulla ratio is approximately 2 or 3:1. The pituitary has a pale white nodule on cut surface.

NERVOUS SYSTEM:

The brain has slight leptomenigeal opacification in the sulci. Coronal sections of fixed brain reveal an unusually shaped, convoluted hippocampus {photos}. The spinal cord is not examined. (CSF Sp. Gr. 1.006)

MUSCULOSKELETAL:

The femur cortex is of expected thickness. The third trochanter of the femur is very large and the marrow sample was obtained by cutting the femur transversely just distal to the third trochanter. There were no palpable bony lesions. (Bones will be examined when the LA County museum has prepared them for study.) There is muscle wasting and all the muscles are dark red-brown. All joints examined are smooth. The only evidence of osteoarthritis is the presence of two joint mice (0.8 x 0.5 x 0.1cm and 1.0 x 0.6 x 0.2cm) in the left stifle joint and slight roughening of the distal patella with two slightly depressed areas approximately 0.4 x 0.3cm.

WEIGHTS AND MEASUREMENTS:

Body weight 340kg (great discrepancy with weight on clinical scales which was 437kg)

Crown to rump length 164cm, tail 55cm

Heart weight 3115g

LAV valve 21cm

RAV valve 22cm

Aortic valve 20.3cm

Pulmonary valve 17cm

LV wall 4cm

RV wall 1.5cm

Septum 3.5cm

24cm b se

Left lung 2.175kg

Right lung 2.625kg

Liver 4440g

Spleen 740.8g

Species: DICERORHINUS SUMATRENSIS SUMATRENSIS Necropsy #: 0034965
Common : SUMATRAN RHINOCEROS

Left kidney 652.6g, measures 19 x 11 x 3cm
Right kidney 800.3g, measures 21 x 12 x 3cm
Left adrenal 21.7g Right adrenal 28.9g
Left thyroid 24.9g Right thyroid 15.7g
Small intestine 913.5cm (Provided by M. Edwards/Nutritionist)
Large intestine 429cm " " " " " " " "
Brain 671.7g

Specimen sent to investigators are appended
Frozen in OCT and plain: One visceral and one peripheral lymph node,
spleen and pituitary.
Frozen for toxicology: Liver, kidney and fat
Photos taken: Spleen, liver, liver nodule, ileum cecal-colic
lung cut surface.

COMMENT ON GROSS EXAM: The probable organized hematoma attached to the liver and the presence of accessory spleens suggest past abdominal trauma (possibly from when the male pushed her into the moat). This may have also caused the lesions in the stifle joint. The orange coloration in the liver suggests hemosiderosis which is a common, but unexplained, finding in rhinos of all species. In this case, chronic weight loss and inanition may have played a role. No overt neoplastic process was found to account for the chronic weight loss and hypercalcemia seen clinically. The kidneys were uniform in appearance which suggests that the lesion seen at renal biopsy may have been representative of the entire kidney and that chronic renal disease was surely a factor. Many of the other observations were incidental findings. The distended lymphatics in the liver and probable cystic lymph nodes in the mediastinum suggest lymphatic blockage, but similar changes were not present in the mesenteries, therefore, lymphangiectasia as a cause of malabsorption cannot be evoked. Bony lesions were not noted on palpation or partial examination of the skeleton, but the bones will be examined more closely when they have been prepared by the L. A. Museum.

Aerobic culture of thyroid (PAL # 3248380) FINAL
-Moderate growth of Staphylococcus epidermidis
-Sensitivity report has been microfilmed

Anaerobic culture of thyroid (same PAL # as above) FINAL
-No growth of anaerobic organisms after 9 days

Veterinary Medical Teaching Hospital, UC, Davis
Cytology final report

Request WW1596
Bone marrow evaluation. Impression smears: The specimen (five slides) consists of erythrocytes and occasional clumps of amorphous debris, sometimes with lipid droplets. Intact nucleated cells are not observed. All material shows marked blue/

Zoological Society of San Diego Page 7
Necropsy Report

Species: DICERORHINUS SUMATRENSIS SUMATRENSIS Necropsy #: 0034965
Common : SUMATRAN RHINOCEROS

turquoise discoloration.

Biopsy: Several sections of bone marrow are examined. There is a moderate amount of cancellous bone. Hematopoietic precursors are extremely rare. No megakaryocytes and very few undifferentiated cells are found. No cells that appear to be maturing cells or either myeloid or erythroid series are found. Several prominent vessels are found in the marrow areas.

INTERPRETATION: IMPRESSION SMEARS - Nondiagnostic

BIOPSY - Extreme hematopoietic hypoplasia (aplasia)
Comments: Impression smears - The blue discoloration of the slides suggests exposure to formalin vapors or a delay (i.e. days) prior to staining.

Thyroid abscess smear:

WG - Amorphous acellular material with emeshed epithelial cells, low numbers of RBC's, golden globular material and very rare neutrophils.

Gram - No bacteria seen. (LL)

Hepatic mass smear:

WG - Few exfoliated cells with nuclei suggestive of epithelial cells; occasional macrophage like cells with pigment; one multinucleated giant cell seen.

Gram - No bacteria seen. (LL)

Heart cystic lesion smear:

WG - Epithelial and endothelial cells with blue granules in cytoplasm.

Gram - Gram positive granules and crenated RBC's.

Smears of marrow:

WG - Hemosiderosis. Partial atrophy of fat cells. (LL)

HISTOPATHOLOGY FINAL DX:

1. CHRONIC INTERSTITIAL NEPHRITIS (NEPHROSCLEROSIS) ASSOCIATED WITH FIBROINTIMAL HYPERPLASIA OF INTERLOBAR AND INTERLOBULAR ARTERIES
2. SEVERE INANITION AND CACHEXIA (GROSS AND CLINICAL)
3. ARTERIOSCLEROSIS CHARACTERIZED BY FIBROINTIMAL PLAQUES, MILD TO MODERATE; AND MINIMAL ATHEROSCLEROSIS OF GREAT VESSELS AND SMALL AND MEDIUM SIZED ARTERIES INCLUDING RENAL, CAROTID, PULMONARY, SPLENIC, GASTRIC AND MESENTERIC
4. MEDIAN DEGENERATION OF ELASTIC FIBERS IN GREAT VESSELS (MILD)
5. HEMOSIDEROSIS, SEVERE, LIVER (HEPATOCYTES AND KUPFFER CELLS), SPLEEN, LYMPH NODES AND BONE MARROW AND MILD TO MODERATE IN KIDNEY (GLOMERULAR TUFTS AND INTERSTITIUM), LYMPH NODES, INTESTINAL MUCOSA, THYROID FOLLICULAR EPITHELIUM, INTERALVEOLAR SEPTA OF LUNGS, ACINAR PANCREAS AND PANCREATIC INTERSTITIUM, ENDOMETRIUM
6. PULMONARY INTERSTITIAL FIBROSIS AND MINERALIZATION, INTERLOBULAR SEPTA

Species: DICERORHINUS SUMATRENSIS SUMATRENSIS Necropsy #: 0034965
Common : SUMATRAN RHINOCEROS

7. ZYMOGEN DEPLETION AND EARLY ACINAR ATROPHY, EXOCRINE PANCREAS, ETIOLOGY? NUTRITIONAL
8. LIPOGRANULOMATOUS LYMPHADENITIS, MULTIPLE LYMPH NODES
9. LYMPHANGIECTASIA, MULTIPLE LYMPH NODES
10. HEPATIC CAUDATE LOBE INFARCTION (POST TRAUMATIC TORSION?)
11. HEMATOCYSTS AND SEROCYSTS, MITRAL VALVES (INCIDENTAL)
12. LIPOFUSCINOSIS, MILD TO MODERATE, MYOCARDIOCYTES, NEURONS
13. LIPOGRANULOMATOUS STEATITIS IN BONE MARROW ASSOCIATED WITH HEMOSIDEROSIS AND SCATTERED FOCI OF HEMATOPOIESIS WITH INCREASED M:E RATIO
14. FIBROSIS, ADRENAL CORTICOMEDULLARY JUNCTION
15. THYROID INTERSTITIAL FIBROSIS, OCCASIONAL CYSTIC FOLLICLES AND FOCI OF FOLLICULAR COLLAPSE ..
16. NODULAR HYPERPLASIA, ACIDOPHILIC CELLS, PARS DISTALIS OF THE PITUITARY AND MULTIPLE COLLOID CYSTS PARS DISTALIS AND INTERMEDIA
17. CYSTIC ENDOMETRIAL HYPERPLASIA WITH VERY MILD MULTIFOCAL LYMPHOCYTIC ENDOMETRITIS
18. OVARY WITH MANY ATRETIC FOLLICLES, CORPORA ALBICANS, SMALL CORPUS LUTEUM, SEVERAL SMALL SECONDARY FOLLICLES BUT NO PRIMARY FOLLICLES OR OOCYTES
19. OSTEOARTHRITIS, MILD ASSOCIATED WITH CARTILAGENIOUS FREE BODIES (JOINT MICE), LEFT FEMOROTIBIAL (STIFLE) JOINT, PROBABLE TRAUMATIC ETIOLOGY (GROSS DX)

COMMENT ON MICROSCOPIC EXAM: The most significant changes appear to be in the kidneys. The lesion is primarily one of diffuse fibrosis with little inflammation. Given the degree of fibrosis, it is easy to see why isosthenuria was present. Hypercalcemia due to decrease in the normal excretion of calcium carbonate by the perissodactyl kidney would explain at least some of the hypercalcemia seen in this animal. It is difficult to understand, however, why the BUN was not elevated other than the fact that the animal was cachectic and had long standing inanition. The cause of the renal sclerosis is uncertain. Resolved tubulointerstitial nephritis must be considered. Candidate agents would be leptospirosis (although plasma cells are not present) and other bacteria capable of causing septicemia. Viral etiologies such as Hantaan virus must be considered, given the animal's origin.

Renal arterial lesions suggest the possibility of underlying "benign" hypertension as an etiology for the nephrosclerosis, but hyaline arteriosclerosis of small arterioles and marked thickening of glomerular vascular poles are not present (although there is thickening of the poles in some glomeruli). Arteriosclerosis with fibrointimal thickening, and splitting and "reduplication" of internal elastic membranes is seen in other organs as well as in some vessel's foam cells suggestive of early atherosclerosis. Such arterial changes are common in aging humans, but are accentuated in individuals with hypertension or diabetes mellitus. Also present in sections of great vessel was disruption of elastic fibers and

Species: DICERORHINUS SUMATRENSIS SUMATRENSIS Necropsy #: 0034965
Common : SUMATRAN RHINOCEROS

mild mucinosis in the media; a lesion which has been associated with copper deficiency.

Another striking lesion was the generalized hemosiderosis. Inanition may have been responsible, at least in part, for this lesion. Hemosiderosis is common in rhinos at necropsy (Kock, et al) and hemolysis has been postulated as the etiology. However, prolonged fasting as occurs in reindeer on migration has been associated with massive, but reversible, iron storage (Broch-Iohnsen, B and Nilssen, KH, 1987, Seasonal iron overload in Svalbard reindeer liver, J. nutrition 117, 2072-2078). The pancreatic acinar atrophy is probably also associated with inanition as protein deficiency, general caloric deficiency and specific nutritional deficiencies such as amino acids and trace elements (especially copper, zinc and selenium) have been associated with this lesion in domestic animals. Excess calcium, iron and molybdenum can aggravate these deficiencies (Jubb, Kennedy and Palmer, 4th edition, 1992, Vol. 2).

Lesions in the lung suggest a past episode of pneumonia or localized ischemic damage. The alveolar septal hemosiderosis might be due, in part, to a degree of passive congestion, however, macrophages (histiocytes) laden with hemosiderin are present in vessel of multiple other organs including capillaries of brain and glomerular tufts. The foci of fibrosis in the lungs were the only areas in which calcification was seen, in spite of the persistently high calcium level seen in this animal.

Another interesting finding is the lipogranulomatous inflammation in lymph nodes and bone marrow. Lipogranulomatous lymphadenitis is part of the syndrome of idiopathic lymphangiectasia in dogs with malabsorption, hypoproteinemia syndrome and is thought to be the result of stasis of high fat lymph with peroxidation and chemotaxis of macrophages. Similarly, degeneration of fat during starvation, possibly coupled with deficiency of antioxidants {e.g. Vitamin E, A, C and selenium) could lead to fat necrosis and macrophage response. Lymphangiectatic lymph nodes seen in caudal neck and mediastinum were probably the result of obstruction.

Other changes suggest abdominal trauma including the infarction of the caudate lobe of the liver, the splenic hilar fissures (gross) and the stifle arthritis.

Lipofuscinosis is a common aging change, but it's presence can be accelerated by hypovitaminosis E.

The changes in the endocrine glands may also be a reflection of aging. The nodular hyperplasia of acidophilic cells suggests the possibility of endocrine dysfunction, although nonsecretory adenomas and hyperplastic foci are common. Acidophilic cells of the pars distalis of the pituitary in most mammals are responsible

Species: DICERORHINUS SUMATRENSIS SUMATRENSIS Common : SUMATRAN
RHINOCEROS
Necropsy #: 0034965

for the production of somatotropin and prolactin. In humans, microadenomas of prolactin secreting cells lead to infertility. Acidophilic cell proliferations that secrete somatotropin can cause acromegaly and hypertension, as well as diabetes. The parathyroids had interstitial fibrosis, but were morphologically identical to those in Tanjung, who did not have hypercalcemia.

In summary, this animal presents as much of a challenge to the pathologist as she did to the clinicians. Additional tests that will be pursued as time permits will be retrospective analysis for serum and tissue copper, additional serum hormone levels, serology for Hantaan virus and other infectious agents.

CVDLS #D9801133: HEAVY METAL SCREEN AS,CD,FE,CU,HG,MN,MO,PB,ZN} The liver contains 6.6ppm of copper. Listed trace mineral concentrations of additional metals have been microfilmed. Of seven cases submitted (Nx #34476, 34974, 36463, 37609, 37767, 34965, 35705}, five had low copper levels when compared to livestock animals; two had above-normal copper levels.

Toxicology: Please note that most livestock animals have copper levels between 25-100 ppm. However, normal liver copper levels for rhinoceros may be below that range. Also note that #36463 and #35705 had higher copper concentrations than the other submitted liver samples. Please note that copper deficiency may contribute to illthrift, poor production, decreased resistance to other diseases, diarrhea in livestock animals and, at extremely low levels, death may occur.

TISSUES DONATED TO RESEARCHERS:
200mg spleen, liver - Melnick
50g spleen, 50g liver, 50g kidney - Sherman
50g brain, 50g spleen - Sibley
Epicardium (in foil} - Shaffer
Bone marrow - SDZ Pathology

b. RAMI #33
i. Necropsy

Zoological Society of San Diego
Necropsy Report

Page:1

Species: DICERORHINUS SUMATRENSIS SUMATRENSIS Necropsy #: 0030915
Common SUMATRAN RHINOCEROS Accession#: M0691738

House RAMI Death Date : 1992/05/25
Sex Female ID: Birth Date : 1991/06/12
Age Yrs 11 Mos 13 Days Prosector DR. BRUCE RIDEOUT

Enclosure ER3 Histologist
Endangered USDI- E CITES- 1 Necropsy Date: 1992/05/25
Preliminary: 1992/05/25 Carcass Disp.: Given to Coded Instit.

Final Date : 1992/06/03

HISTORY: This Sumatran Rhinoceros was received by the SDZ on 91/11/23. It was part of the Rhino string, ER 3. Enclosed with one female, same species. Accession: M0691738. Death occurred on 92/05/25 at 9:15AM. First recorded body weight after arrival was 634.0kg on 91/11/23. "Received from Sumatra. History of minor mastitis. Bled opportunistically 92/01/23; serum stored. 92/05/25: Showing signs of severe distress in AM. Ate well yesterday. Apparently ate overnight, had feces in barn, but signs of thrashing there. 9:30 AM: Difficulty standing. Getting up and down and kicking severely. 9:00 AM: Beginning signs of respiratory distress seen. 9:10AM: Given 50mg Butorphenol intramuscularly via dart. 9:15AM: Apnea, no sign of heart beat. Attempted CPR. Unsuccessful. Postmortem blood samples collected and saved." This information was provided by SDZ Veterinary Director, Donald L. Janssen, DVM. The rhino was received by Pathology on 92/05/25 at 10:50 AM and was posted that day commencing at 10 AM by Pathologist, Bruce A. Rideout, DVM, PhD. Items saved for Necropsy Rounds. Body saved for museum. Gross data sheets microfilmed.

GROSS FINDINGS:

- Stomach: The margin between the squamous and glandular portions of stomach (margo plicatus) has a few round to oval (5mm diameter) focal defects in the squamous portion, which are probably normal irregularities in the margin of the squamous region but could also be previous attachment sites for gastric parasites (e.g. bats, assuming rhinos are hosts to these parasites)
- Small intestine: The mucosa of the duodenum, jejunum and ileum is moderately congested/hyperemic and the luminal content is watery
- Cecum: There is a multinodular submucosal mass at the ileocecolic junction, which measures about 6cm x 2cm x 2cm. (The largest dimension runs perpendicular to the long axis of the gut in this region.) This mass is situated on a mucosal ridge that demarcates the junction between the cecum and large colon, and is adjacent (distal) to the ileocecal junction. This mass is composed of coalescing nodules (apprx. 1cm-2cm diameter) of cream colored, firm, fleshy homogenous tissue with a slight fibrous texture on cut surface in some areas. The cut surface has a greasy or oily feel and all sections float well in formalin. The mass appears to be limited to the submucosa and is covered by intact, grossly normal mucosa.
- Cecal lymph node has some patchy pale foci on cut surface

Species: DICERORHINUS SUMATRENSIS SUMATRENSIS Necropsy #: 0030915
Common : SUMATRAN RHINOCEROS

- Large colon: There is a 360 degree torsion at the root of the large colon (counterclockwise rotation if facing animal's head and looking toward rear). There is marked congestion and petechiation of the serosal surface along the course of the large serosal veins. No gross thromboses of veins or mesenteric arteries are evident. The mucosal surface of the large colon is dark red/black and there is marked diffuse submucosal edema. The entire large colon is markedly distended with gas (more than expected for the short postmortem interval) but otherwise contains normal ingesta.
- Pituitary: The pituitary is prominent and bilobed, with two equal sized lobes appx 5mm to 7mm diameter, arranged side by side. The nodules project dorsally toward the hypothalamas.
- Abundant abdominal fluid - tan, cloudy (postmortem?)
- Not pregnant
- Good nutritional condition

ORGAN WEIGHTS AND MEASUREMENTS:

Liver 10.8kg
Spleen 1575.0g
Right kidney 1750.0g
Left kidney 1350.0g
Right thyroid 33.5g
Left thyroid 36.6g
Right adrenal 44.0g
Left adrenal (partial} 9.5g
Right lung 2.5kg
Left lung 1.6kg
Heart 3.775kg
Cerebellum (without brainstem) 78.3g
Whole brain 702.5g
Pituitary 4.5g
Body weight 630.0kg
Crown to rump length 195.5cm

TENTATIVE LIST OF ITEMS DONATED TO RESEARCHERS:

200.0g spleen & so.0g liver to Dr. Don Melnick, Dept.of Anthropology,
Colombia University, New York, NY 10027
20ml serum & 200.0g each of liver, kidney, spleen and brain to
Dr. Eric Miller, St. Louis Zoo
10ml serum and 100.0g liver to Dr. Joseph Smith, Pathology Department,
College of Veterinary Medicine
Kansas State University
5ml serum and 50.0g liver to Dr. Carol Bolin, NADC, Ames, Iowa
5ml serum and 100.0g liver to Dr. Duane Ullrey, Dept of Animal Science
Michigan State University
5.0g each of liver, heart, adipose, skeletal muscle, peripheral nerve
Dr. Ellen Dierenfeld, New York Zoological Society,
Bronx, New York
Skin specimen (fixed in 10% NBF) to Dr. Danny Scott, Cornell University
Whole right kidney with associated ureter & blood vessels to

Zoological Society of San Diego
Necropsy Report

Page: 3

Species: DICERORHINUS SUMATRENSIS SUMATRENSIS Necropsy #: 0030915
Common : SUMATRAN RHINOCEROS

Dr. Noble Maluf, 12500 Edgewater Drive, Cleveland, Ohio
50.0g each of liver, kidney & spleen to Dr. G.B. Sherman

Dept. of Vet. Biosciences
University of Illinois, Urbana

50.0g spleen, 50.0g brain & 200.0g kidney to Dr. Charles Sibley
95 Seafirth Road
Tiburon, California

Bile sample to Lee Hagey/Dr. Alan Hofmann, UCSD

One-half pituitary to Endocrinology/CRES

Data regarding brain and body to Dr. Sam Ridgway

1S.Og **spleen**, 100.Og brain and 100.Og heart to Genetics/CRES

Left ovary to Dr. Earle Pope, CREW, Cincinnati Zoo

Photographs, measurements of female reproductive tract and one ovum
frozen by Reproductive Physiology/CRES

5.0ml serum, 50.0g each of liver & kidney to Virology, Worley/CRES

Skin biopsy to Cytogenetics/CRES

Body and skin samples (1 skin sample to be returned to SDZ Education)
to Dr. David Archibald, Mammology Dept/SDSU

10ml serum to Dr. Anne Bowling (Phone 916 752-2211)

PATHOLOGIST COMMENTS ON GROSS FINDINGS: Colonic torsion is cause of
death, but whether cecocolic mass predisposed to torsion is unclear.
Histo, cytologies and cultures pending. Lymph node and ileocecolic
mass frozen for future culture if needed.

PRELIMINARY GROSS DX:

- 1.Torsion of large colon
- 2.Secondary toxemia/shock
- 3.Submucosal mass, cecocolic junction
- 4.Possible lymphadenitis, cecal lymph node

* * * * *

HISTOPATHOLOGY

Aerobic culture of abdomen (PAL # 2129639) FINAL

-Moderate growth of Escherichia coli

-Moderate growth of Beta hemolytic streptococci

Anaerobic culture of abdomen (Same PAL # as above) FINAL

-No growth of anaerobic organisms after 10 days

Smear of abdominal fluid consists of moderate numbers of mixed
bacteria with some fragments of septate fungal hyphae. No
inflammatory cells evident. (BR)

Smear of cecal mucosal mass are non-diagnostic, consisting

Species: DICERORHINUS SUMATRENSIS SUMATRENSIS
Common : SUMATRAN RHINOCEROS

Necropsy #: 0030915

primarily of fecal debris with rare unidentified mesenchymal-like cells. Acid fast negative. (BR)

TISSUES EXAMINED

Slide 1: Liver
Slide 2: Heart
Slide 3,4: Lung
Slide 5: Lung, heart
Slide 6: Skeletal muscle, kidney, trachea
Slide 7: Stomach (squamous and glandular)
Slide 8: Spleen, liver
Slide 9: Kidney, thyroid, parathyroid (fragmented)
Slide 10: Thyroid, adrenal
Slide 11: Lymph node, mammary gland
Slide 12: Tongue, esophagus
Slide 13: Submucosal mass cecum
Slide 14: Stomach (squamous and glandular), thymus
Slide 15: Adrenal, adipose tissue, colon
Slide 16: Small intestine
Slide 17: Colon, lymph node
Slide 18: Cecum
Slide 19: Cecum, small intestine
Slide 20: Lymph node
Slide 21: Pancreas, salivary gland
Slide 22: Pancreas, lymph node
Slide 23: Ovary, cerebellum
Slide 24: Brainstem
Slide 25: Pituitary, cerebrum
Slide 26: Cerebrum
Slide 27: Cerebellum
Slide 28: Cerebrum
Slide 29: Cerebrum

PATHOLOGIST COMMENTS ON MICROSCOPIC FINDINGS: Histopathologic findings confirmed colon torsion and subsequent shock as the cause of death. The liver lesions are interpreted as a reflection of shock and showering of the liver with endotoxin and/or bacteria from the devitalized segment of bowel. The submucosal mass at the ceca-colic junction appears to be a lipoma (a benign tumor of fat cells), but evaluation of the mass is hindered by technical problems associated with sectioning and mounting the tissue on microscope slides (tissues with high fat content are frequently difficult to section and mount). Although submucosal lipomas of the gastrointestinal tract are extremely rare in domestic animals, they are relatively common in humans. Interestingly, they are most often found near the ileo-ceco-colic junction in humans, which was the location of the lipoma in this rhinoceros. In humans, these tumors usually cause no clinical signs, but can be associated with intussusceptions or luminal obstruction in some cases. In this case it is tempting to speculate that altered intestinal motility or function associated with

Species: DICERORHINUS SUMATRENSIS SUMATRENSIS
Common : SUMATRAN RHINOCEROS

Necropsy #: 0030915

this lipoma was the predisposing factor that led to the colonic torsion, particularly since no other predisposing factors could be identified. However, there is unfortunately no way to verify that the lipoma played such an etiologic role. Many cases of large colon torsion in the horse are spontaneous (i.e. no predisposing causes can be identified). There is circumstantial evidence that rolling on the ground (from any cause, but usually due to pain from other intestinal problems, such as sand impaction) can result in colonic torsion in horses. In this case there was no evidence of sand impaction or any other source of gastrointestinal pain that would have caused the animal to roll on the ground.

The gastric lesions are most likely a reflection of resolving mild parasitism. No parasites were evident at necropsy, presumably because of previous anthelmintic treatment. The cause of the lymphoid hyperplasia is not evident.

The hemosiderosis in the spleen and a few other organs is interesting because it has been seen in other rhinos and may be related to previous episodes of hemolysis (intravascular hemolysis appears to be an important disease process in rhinoceros}. It may just be a normal age-related finding in this case. Most of the other postmortem findings are interpreted as secondary to shock, or as incidental age-related changes.

Some bacterial culture results and special stains are still pending. Any additional significant findings will be reported in an addendum.

In summary, the cause of death in this case is 360 degree torsion of the large colon, which may have been related to the submucosal lipoma at the ceco-colic junction, or may (equally likely} have been spontaneous. No specific changes in management are recommended.

HISTOPATHOLOGY FINAL DX:

- 1.LARGE COLON 360 DEGREE TORSION
- 2.SHOCK SECONDARY TO COLON TORSION
- 3.LIPOMA, CECAL SUBMUCOSA
- 4.HEPATITIS, ACUTE, NEUTROPHILIC, NECROTIZING, MULTIFOCAL, MILD
- 5.HEPATOPATHY CHARACTERIZED BY MODERATE DIFFUSE HEPATOCYTE SWELLING
- 6.ACUTE TUBULAR NECROSIS, MULTIFOCAL, MILD, KIDNEY
- 7.INTERSTITIAL FIBROSIS WITH MINERALIZATION, MULTIFOCAL, MILD, KIDNEY
- 8.GASTRITIS, ULCERATIVE EOSINOPHILIC, CHRONIC, MULTIFOCAL, MILD (ETIOLOGY, PARASITIC?)
- 9.LYMPHOID HYPERPLASIA, MODERATE, WITH PROMINENT GERMINAL CENTER LYMPHOLYSIS, LYMPH NODE, SPLEEN
- 10.LYMPH NODE (GASTRIC?), DRAINAGE REACTION
- 11.HEMOSIDEROSIS, MODERATE, SPLEEN
- 12.HEMOSIDEROSIS, MILD, DUODENUM AND KIDNEY

Species: DICERORHINUS SUMATRENSIS SUMATRENSIS Common : SUMATRAN
RHINOCEROS

Necropsy #: 0030915

- 13. FATTY INFILTRATION, THYROID
- 14. PULMONARY EDEMA WITH CIRCULATING LEUKOCYTOSIS, MILD, LUNG
- 15. VASCULOPATHY CHARACTERIZED BY MYOINTIMAL THICKENING
AND VACUOLATION, STOMACH
- 16. MYODEGENERATION, MULTIFOCAL, MINIMAL, TONGUE
- 17. VACUOLATION, ADRENAL CORTEX, MODERATE

ADDENDUM: Fat, heart, skeletal muscle & liver analysis results from the New York Zoological Society, Bronx Zoo, Animal Health Center have been microfilmed.


ADDENDUM: Due to an unfortunate miscommunication, the reproductive tract was discarded by the Reproductive Physiology group of CRES after their examination and was therefore not available for examination by the Pathology Department. A single section of ovary was available for histologic examination.

ADDENDUM: Special stains revealed a few, scattered, gram positive cocci and rods in the superficial portions of the ulcerated, gastric mucosa. This is interpreted as insignificant.

ADDENDUM: Dr. Noble Maluf (recipient of kidney) concurs that "from an anatomical standpoint, the kidneys appear to be essentially normal".

ADDENDUM 92/08/26: Kansas State University, Department of Pathology
Iron request
Results: 430 ug/dl iron.
453 ug/dl TIBC.
1389 ug/Fe gram tissue of liver

ii. Rami ART Earle Pope



Select A City

Buttons: Reply, Reply All, Forward, Attachments (1), Print, Prev, Next, Inbox

Download Attachments

1 - Choose Folder -

From: "Dr. Earle Pope" <epope@acres.org> 1 Block address
To: "Dr. Sabine Hilsberg" <dr_hilsberg@yahoo.com>
Subject: "Rami" ISIS#0691738 San Diego SB #33
Date: Wed, 14 Jun 2000 17:27:24 -0500

Add Addresses

Dr. Hilsberg,

According to my notes she died on 5/25/92. One ovary was removed and shipped chilled to me on 5/26. On 5/27 at 11:25 am I received the ovary at CREW.

Dimensions=73 mm long, 40 mm deep and 20 mm wide, with a slice removed from the middle before shipment.

Structures: several CAs were present, especially on one side

Oocyte retrieval: visible surface follicles were aspirated before the ovary was sliced and minced into small pieces. Recovered 3 oocytes from the 5 largest follicles; one with "expanded" cumulus cells, one with compact cumulus and one without cumulus (bare)

Recovered 2 oocytes with compact cumulus from 6 smaller follicles. Plus, 2 oocytes with compact cumulus were recovered after slicing/mincing the tissue. Total oocytes recovered=7

That is all of the information that I have. I hope it is of some use.

Best Regards,

Earle Pope
New Orleans, LA

The oocyte with "expanded" cumulus cells was placed in IVM culture for 25+ hr before fixing/staining. It was at Metaphase I with some chromosome clumping.

The other 6 oocytes were frozen (controlled rate) at recovery and should be still in the CREW "Frozen Zoo"

Buttons: Print, Prev, Next, Inbox, Reply, Reply All, Forward

3. Treatment bases for Leiomyoma- J.C.M. Tisbris 2000



UNIVERSITY OF SOUTH FLORIDA

COLLEGE OF MEDICINE

DEPARTMENT OF OBSTETRICS AND GYNECOLOGY

SUITE 529
HARBOURSIDE MEDICAL TOWER
DAVIS ISLANDS
4 COLUMBIA DRIVE
TAMPA, FLORIDA 33606

RESEARCH DIVISION
JOHN C.M. TSIBRIS, PH
D. PROFESSOR AND DIRECTOR

TELEPHONE (813) 254 774
FAX (813) 254-0940
EMAIL JTSIBRIS@COM1.MED.USF.EDU

February 21, 2000

Dr. Nan Schaffer
680 N. Lake Shore Drive, Apt. 807
Chicago, IL 60611

Dear Dr. Schaffer:

Following your telephone request, I am happy to provide a synopsis of what we have learned about the pathways to uterine leiomyomata. We have adopted a dual approach (Tsibris et al., Cancer Research 59:5737-44, 1999) of screening human hysterectomy specimens for nuclear receptor expression and then testing concepts in our excellent model of ovariectomized Dunkin-Hartley guinea pigs (*Cavia Porco/Jus*), as follows:

Human leiomyomata showed 4-fold higher levels of nuclear receptors RXR α and PPAR γ and all-trans retinoic acid (a biologically active form of vitamin A) than normal myometrium. Such high levels, however, occurred only during the follicular phase of the menstrual cycle, when estrogens are unopposed by progesterone. Based on these data, we gave to guinea pigs estradiol, all-trans retinoic acid and troglitazone, a PPAR γ agonist, which caused very large uterine leiomyomata and validated the view that "nutritional excesses" can lead to leiomyomata.

So, what can we do for Asian Rhinos? Going to the root of the problem by eliminating the presumed master inducer, estradiol, did not work well in women with the previous generation of available drugs, such as Leupron (a GnRH agonist), due to serious side effects and in the case of the rhinos, incompatibility with reproduction. New estrogen antagonists, the SERM (such as Raloxifene) will undoubtedly work better, but they are proprietary and realistically non-existent for veterinarian use for a few years. I hope that after 2-4 years of Phase I and II trials we could arrive at non-genomic therapies for human leiomyomata with mono- or combined-exposure (not orally, but either vaginally or in situ through an endoscope) to SERM and RXR /PPAR γ antagonists.

Even if we had now a few grams of each of these receptor antagonists, it would be criminally irresponsible to think of giving them to rhinos for leiomyomata, without the assurance that their leiomyomata are similar to those in women and guinea pigs. There are no inhibitors specific enough for retinol (vit. A) dehydrogenases/oxidases to lower all-trans retinoic acid (atRA) levels in the tumors; I would forget lowering vitamin A intake, before we know that rhino leiomyomata contain too high levels of the active ingredient (atRA).

Our efforts must have scientific credibility to attract financial support from appropriate international agencies. It is never too late for the first step, namely, convince people who care for these beautiful animals to obtain and freeze as quickly as possible uterine specimens (leiomyomata and matched myometrium) from scheduled necropsies. Dry ice or a -75°C freezer should suffice for storage of the specimens until air transportation is arranged.

I hope that my lab can be of assistance in this very worthwhile effort.

Sincerely,
John C.M. Tsibris, Ph.D.
Professor and Director

THE UNIVERSITY IS AN AFFIRMATIVE ACTION EQUAL OPPORTUNITY INSTITUTION

NECROPSY REPORTS OF SUMATRAN RHINOCEROS “DUSUN”

Captured 9 September 1986 at Sungei Dusun, Malaysia

Died 7 February 2001 at Way Kambas, Sumatra, Indonesia

LABORATORIUM PATOLOGI VETERINER

Jurusan Parasitologi dan Patologi, Fakultas Kedokteran Hewan - Institut
Pertanian Bogor

Jalan Taman Kencana No. 3 BOGOR - 16151,

Tel dan Fax: (0251) 329539; Email : patoipb@indo.net.id

March 03rd, 2001

Protocol No: P/04/01

Anamnese:

Sumatran Rhinoceros, 35 year old, Female

Dead on February 07th, 2001 at 01.50 local time.

Clinical history:

Paralysis for 10 days, appetite was normal.

Necropsy Findings: There were decubitus lesion at the hind leg and mammary skin, inflammation of mammary gland, subcutaneous edema with serous atrophy of the fat. Tracheal mucosa was hemorrhage with mucous exudate. The lungs were congested with multi focal calcification; a bullet was found attached to the inner site of bronchi; There was adhesion of the pleura and diaphragm. The heart showed serous atrophy of the depo of fatty tissue, dilatation of the left ventricle with thickened valves, and the myocard was pale. There were multi-focal raised plaques over the surface of aorta and left atrium.

The stomach was full of normal ingesta, the mucosa showed reddish and echimotic.

Inflammation with cattharal exudate were found in the intestines.

The liver lobulation were accentuated and there was one white cyst 0.5 cm in diameter. Nodular hyperplasia (1 cm in diameter) were found in spleen.

Both kidneys have multiple brown cysts (0.5-1 cm in diameter), the cysts contain black and gritty like materials.

The urinary bladder contain deposit of greyish white sandy materials, with some ecchymotic hemorrhage on the mucosa.

Pancreas were red and diffusely nodulated.

The wall of the uterus has focal thickened nodule of 2 cm in diameter.

Anatomy Pathological Diagnose:

Decubitus, Mastitis, Oedema, Tracheitis, Pneumonia, Corpus alienum, Pleuritis, Dilatatio cordis sinistra, Arteriosclerosis, Gastroenteritis cattharalis et hemorrhagica, Spleen hyperplasia and Kidney cyst.

Pathologist,

Bambang Pontjo Priosoeryanto, DVM, MSc, Ph.D.

=====

Microscopical Findings:

Lung:

Congestion and severe fibrosis of alveolar wall with multi focal granuloma, leukocytes were found within numerous alveolar lumen.

Tongue:

Lymphocytes infiltration were found at lamina propria accompanied with multi-focal area of necrosis with calcification.

Stomach and Intestine:

Surface and cryptal epithelium desquamation were prominent due to autolysis change. Some lymphocytic inflammatory cells were observed within the lamina propria.

Liver:

Hepatocytes were enlarged with variable degree of degeneration. Bile pigment deposition were observed within some hepatocytes cytoplasm. Numerous macrophages which phagocytosed brown pigment (probably bile pigment?) were found at portal hepatic. The space of Disse was dilated due to edema.

Pancreas:

There were autolysis lesion within acinar cells of pancreas, proliferation of fibrous connective tissue between lobes and atrophied acinar cells were observed.

Heart

Mild lymphocytic infiltration of epicardium. Lipofuchsin pigment deposition were observed within myocytes.

Spleen:

Lymphoid follicle were depleted, numerous hemosiderin containing macrophages were observed within red pulp.

Kidney:

There were diffuse infiltration of fibrous connective tissue and chronic inflammatory cells within interstitial tissue. The cysts were contained proteinaceous fluid with numerous macrophages phagocytosed light brown pigment (probably hemosiderin?). Some glomerulus showed atrophy, dilated space of Bowman with proteinaceous fluid and thickened capsule. Numerous tubules were showed flattened epithelium, the lumen were dilated and filled with proteinaceous fluid or occasionally mineral sedimentation.

Uterus:

Lamina propria of uterus wall were showed edema. The mass which observed grossly within uterus wall was composed of proliferation of spindle cells resemble smooth muscle cells. There was low mitotic figure and no atypia cells observed.

Mammary Gland:

There were remnant of glands surrounded by fibrous tissue proliferation. Congestion and mild hemorrhage were observed diffusely. Numerous macrophages which phagocytosed brown pigment (probably hemosiderin?) were observed within area of fibrosis.

Brain:

Almost all neuron were enlarged, lipofuchsin pigment was accumulated within cytoplasm. Mild gliosis were observed.

Histo pathological Diagnose:

1. Fibrinous pneumonia with multi focal granuloma.
2. Epicarditis
3. Necrotic ulcerative cheilitis with calcification
4. Edema, degenerated hepatocytes with bile pigment stagnation
5. Interstitial fibrosis of pancreas
6. Nephrosis
7. Leiomyoma of the Uterus
8. Ceroid lipofuchsin storage within myocardium and neuron

Pathologist,

Dewi Ratih Agungpriyono, DVM, Ph.D.
NIP. 131760 839