



Anatomy of Pedal Scant Gland in Greater one Horn Rhinoceros (*Rhinoceros unicornis*)

Anil Deka^{1*}, Kabita Sarma¹, M. Talukdar¹, B. Choudhury², S. Sinha¹, P. Basumatary², S. Ali² and D. Baro²

¹Department of Anatomy & Histology, College of Veterinary Science, Assam Agricultural University, Khanapara, Guwahati, Assam, India

²Veterinary Surgeon, Wild Life Trust of India, India

*Corresponding author: dranilvet01@gmail.com

ABSTRACT

The present study was conducted on one Pedal scant gland of Greater one Horn Rhinoceros. The Pedal scant gland was exocrine glandular complex, situated in the subcutaneous layer. The Pedal scant gland was composed of proximal, intermediate and distal. The proximal part of the gland contained large cutaneous pores on the skin surface. A canal was observed in the intermediate part of the gland. The intermediate part of the gland was lined by keratinized stratified squamous epithelium. Dermal layer of the gland contained connective tissue along with blood vessels. The distal part of the gland contained abundant acini. These acini were lined by simple cuboidal epithelium. Collagen fibers were observed among the acini as well as dermal layer of gland.

Keywords: Pedal, Scant, Gland, Greater, One, Horn, Rhinoceros

The greater one-horned rhinoceros is native to the Indian subcontinent. Rhinoceros is the largest among the perissodactyla and third largest among the land animals. Greater one horn Rhinoceros is Schedule I animal as per wildlife protection Act, 1972. The Greater one horn Rhinoceros is the second largest terrestrial animal next to Asian elephant. The rhino's single horn is present in both males and females, but not on newborn young. Their population is decreased due to encroachment of habitat by human and livestock, and their poaching for horn. The pedal scant gland helps detection of other Rhinoceros because Rhinoceros showed particular interest in the sites of urination and defecation of other Rhinoceros (Laurie, 1982). Literature on the Greater one horn Rhinoceros (*Rhinoceros unicornis*) which is considered as an endangered and Schedule I species is found to be scarce. Therefore, considering the importance of this species in wildlife the present

study was undertaken to elucidate the gross and histomorphological parameters of the Pedal scant gland.

MATERIALS AND METHODS

In present study, one pedal scant gland was utilized. Immediately after death the Pedal scant gland was collected from Forest Department, Kaziranga National Park by Wildlife trust of India and fixed in ten percent formalin. After that, the gland was sent to the Department of Anatomy & Histology, College of Veterinary Science, Assam Agricultural University, Khanapara, Guwahati, Assam, India for examination. After that gross anatomical parameter was recorded. Then tissue was processed for Paraffin embedding method. Paraffin sections were cut in five micron thickness and stained with Haematoxylin and Eosin method for histomorphological and Van Gieson's method for collagen fibre (Luna, 1968).

RESULTS AND DISCUSSION

The current study was conducted on one Pedal scant gland of Greater one Horn Rhinoceros (*Rhinoceros unicornis*). The Pedal scant gland was exocrine glandular complex, situated in the subcutaneous layer. The Pedal scant gland was composed of proximal, intermediate and distal. The proximal part of the gland contained large cutaneous pores on the skin surface (Fig. 1).

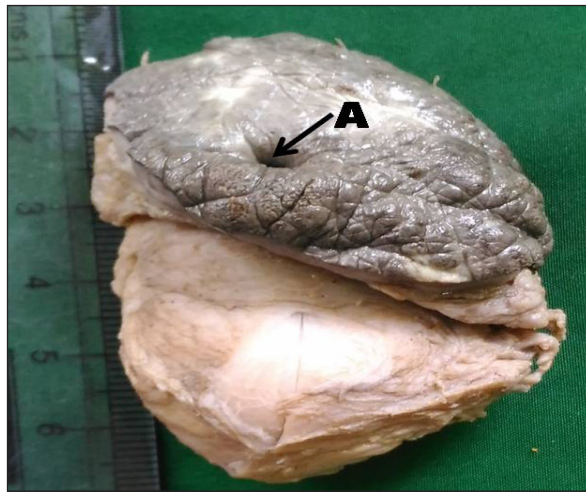


Fig. 1: Photograph showing the presents of large cutaneous pores (A) on the skin surface of proximal part of pedal scant gland

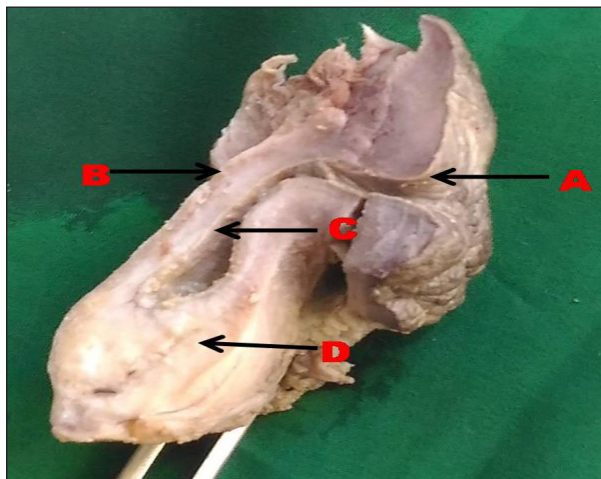


Fig. 2: Photograph showing the presents of large cutaneous pores (A) on the skin surface of proximal part, Intermediate part (B), Canal (C) and apex (D) of pedal scant gland

These findings were corroborated with the findings of Bacchetta *et al.* (2007) in carpal gland of wild swine. A canal was observed in the intermediate part of the gland. The length and breadth of the pedal scant gland were 5.1 cm and 1.7 cm, respectively. The length and breadth of the canal of the gland (Fig. 2) were 3.3 cm and 0.5 cm, respectively.

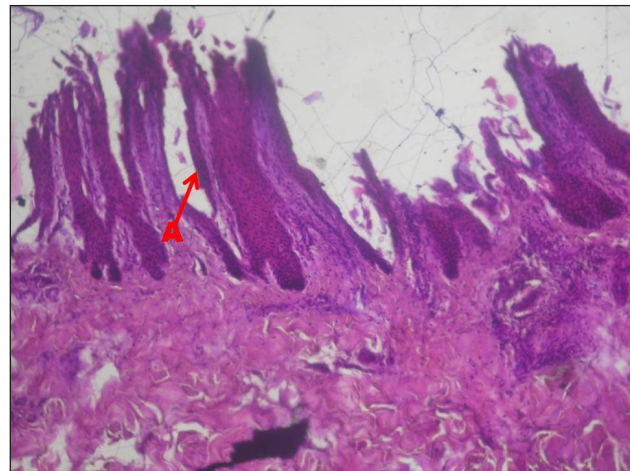


Fig. 3: Photomicrograph showing the keratinized stratified squamous epithelium pedal gland of Greater one horn rhinoceros

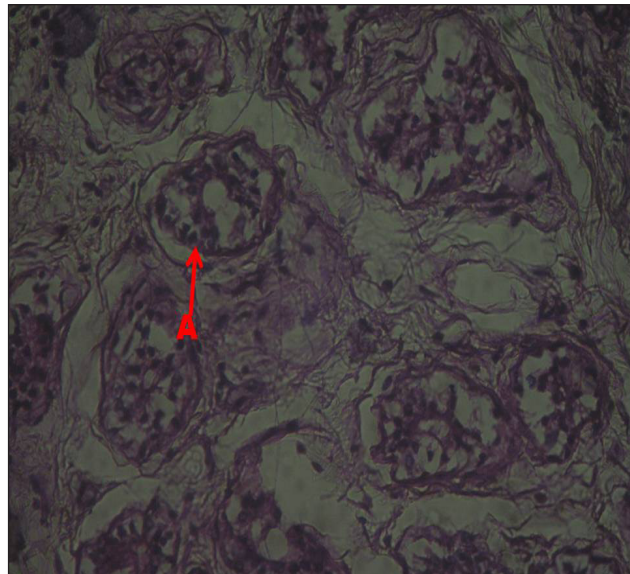


Fig. 4: Photomicrograph showing the abundant acini (arrow) in the distal part of the gland of Greater one horn Rhinoceros

The intermediate part of the gland was lined by keratinized stratified squamous epithelium (Fig. 3). These findings were in accordance with the findings of Cave (1961) in Pedal gland of Rhinoceros. Stratum corneum was blackish in colour. Dermal layer of the gland contained connective tissue along with blood vessels. The distal part of the gland contained abundant acini (Fig. 4). Collagen fibers (Fig.5) were observed among the acini as well as dermal layer of gland.

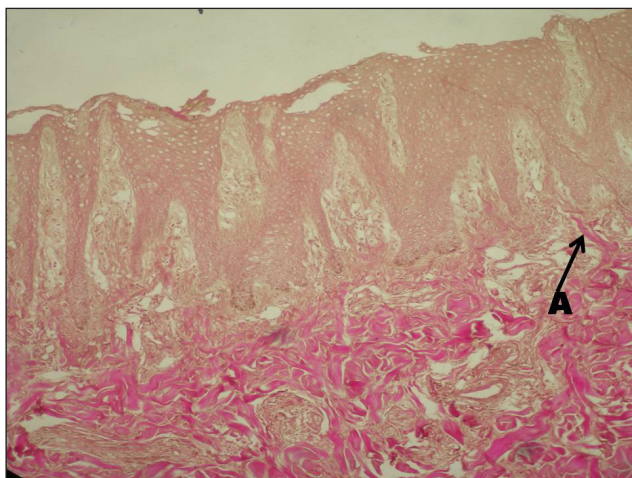


Fig. 5: Photomicrograph showing the collagen fibers (arrow) of Pedal scant gland of Greater one horn Rhinoceros

SUMMARY AND CONCLUSION

The Pedal scant gland was composed of proximal, intermediate and distal. The proximal part of the gland contained large cutaneous pores on the skin surface. A canal was observed in the intermediate part of the gland. The intermediate part of the gland was lined by keratinized stratified squamous epithelium. Stratum corneum was blackish in colour. The distal part of the gland contained abundant acini. These studies will be helpful to wildlife veterinarians in many veterolegal cases in order to identify this organs and disease control regimes.

REFERENCES

- Bacchetta, R., Mantecea, P., Lattuada, L., Quaglia, F., Vailati, G. and Apollonio, M. 2007. The carpal gland in wild swine: Functional evaluations. *Italian Journal of Zoology*, **74**(1): 7-12.
- Cave, A.J.E. 1961. The Pedal scant gland in Rhinoceros. University of London, pp. 685-690.
- Laurie, A. 1982. Behavioural ecology of the Greater one horned Rhinoceros (*Rhinoceros unicornis*). *Journal of Zoology*, **196**: 307-341.

