

MANDIBLE OF THE GREAT INDIAN ONE HORNED RHINOCEROS (*RHINOCEROS UNICORNIS*)

C.C. Bordoloi, S. Borthakur, S.R. Talukdar, S.N. Kalita,
G. Baishya and H. Kalita

Department of Anatomy & Histology,
College of Veterinary Science,
Assam Agricultural University,
Khanapara, Guwahati-781 022

The great Indian one horned *Rhinoceros unicornis* belongs to the class - *Mammalia*, order - *Perissodactyla* and family - *Artiodactyla*. It is a rare and valuable species found in Assam forest. An attempt has been made to investigate the gross anatomical characteristics of the mandible, which was not found in the available literatures.

Materials and Methods

Six numbers of mandibles of adult and young rhinos were collected from the Kaziranga national park, Assam and brought to the Department of Anatomy and Histology, College of Veterinary Science, Khanapara, Guwahati. These bones were processed and prepared as per the technique recommended by Raghavan (1964) for gross anatomical study.

Results

The mandible of the one horned rhinos was the largest bone of the skull. It consisted of two symmetrical

halves which ossified at the body, both in the adult and young animals. The two halves of the mandible ossified at the symphysis mandible. The lingual surface was wide, smooth and slightly concave, presenting a median line indicating the line of fusion of the originally distinct two halves of the body. The alveolar border was thick and slightly convex and continuous with the alveolar border of the body. There were 4 alveoli for lower incisor teeth. The 2 alveoli in the middle were smaller and outer 2 were larger in size, which contained 2 large incisors. The inter-alveolar septum was massive. The lateral border was thick and slightly convex and continuous with the alveolar border formed a sharp ridge, extending from the large incisor teeth to the alveolar border of the rami and terminated at the cheek tooth. The rami, right and left diverged laterally, forming a 'V' shaped intermandibular space. They were massive and flattened from side to side. Each ramus was bent upwards and for-

the horizontal part was perforated by 6 alveoli for the cheek teeth, the first alveolus was the smallest and the rest were gradually larger in size towards backwards. The posterior border of the horizontal part was thick, convex and smooth posteriorly while the vertical part was convex and rough.

The lateral surface of the ramus was widest at the angle of the mandible. It was concave at the vertical part and convex at horizontal part. The horizontal part was gradually narrow towards the body of the mandible. The vertical part was wide throughout its

length. The vertical part presented few rough lines at its lateral surface for the muscular attachment. The mental foramen was present at the level of the 2nd cheek tooth (Fig.1). The horizontal part was convex dorsoventrally.

The medial surface at the vertical part was concave with a prominent rough line towards the posterior part. Numerous faint impressions for nerves and blood vessels could also be noticed. The mandibular foramen was closer to the alveolar border of the vertical part (Fig.2). The coronoid process projected upwards and then

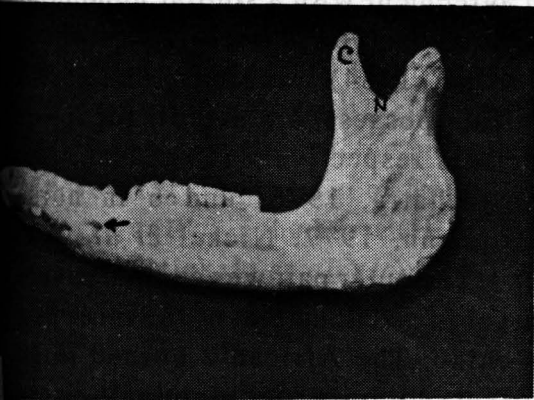


Fig. 1 Lateral surface of the mandible of one horned rhino showing the mental foramen (arrow) coronoid process (C) and mandibular notch (N)

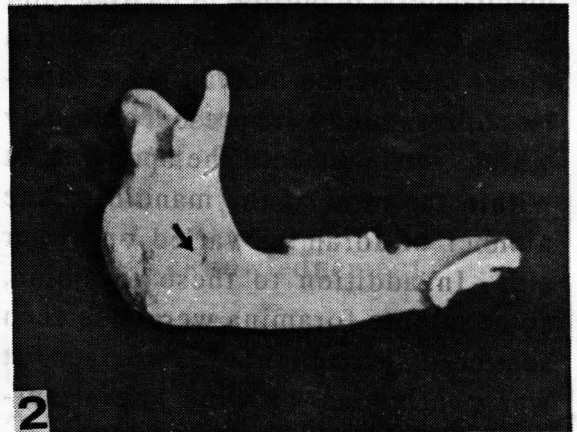

Fig. 2 Medial surface of the mandible of one horned rhino showing the mandibular foramen (arrow)

slightly backwards and inwards. It was pointed at the extremity and wide at the base (Fig.1). The mandibular notch was wide (Fig.1). The articular surface of the condyle situated below and behind the coronoid process. It was elongated transversely and projected inwards. Laterally, the surface was higher in position and thicker than the medial part. The condyle was convex antero-posteriorly. The neck of the condyle was thick, short and constricted. The posterior part behind and below the condyle revealed a triangular tuberosity.

The labial surface was flat and quadrilateral in outline. A median faint ridge was found in some cases. On either side of the median ridge, a series of foramina were present obliquely which continued into the spongy part within the rami of the mandible. The number of foramina varied on either side. In addition to these foramina, some minute foramina were also seen scattered throughout this surface. It was continuous with the lateral surface of the horizontal part of the ramus.

Discussion

The general gross anatomical characteristics of the mandible of one

horned rhino resembled that of other ruminants and equines (Raghavan, 1964 : May, 1970; Hillmann, 1977; Nickel *et al.*, 1981). The mandible of rhino was found to be the largest bone of the skull. Similar observations were recorded in other domestic animals (Sisson, 1977; Miller *et al.*, 1964; Raghavan, *loc. cit.*; May, *loc. cit.*; Hillmann, *loc. cit.*). The symmetrical halves of the mandible fused after birth both in the adult and young rhinos. This observation was in accordance with similar observations recorded in horse (Hillmann, *loc. cit.*; Nickel *et al.*, *loc. cit.*). There were 4 alveoli for the lower incisors in rhino, which was in agreement with a similar number of alveoli observed in *Rhinoceros indicus* (Jerdan, 1984); whereas, cattle and buffalo possessed 8 alveoli for lower incisors respectively (Raghavan, *loc. cit.*; Khatra, 1978) and 6 in horse (Hillmann, 1977; Nickel *et al.*, *loc. cit.*). The outer pair was comparatively larger in size than that of the inner pair in rhino. The African 2 horned rhino possessed only deciduous incisors (Jerdan, *loc. cit.*). The 'V' shaped intermandibular space was in conformity with the similar findings in domestic animals (Sisson, *loc. cit.*; Miller, *et al.*, *loc. cit.*; Khatra, *loc. cit.*; Hillmann, *loc. cit.*) and other species of rhinoceros (Jerdan, *loc. cit.*).

The presence of 6 alveoli for cheek teeth recorded in this study were in conformity with the findings in cattle (Raghavan, *loc. cit.*) buffalo (Khatra, *loc. cit.*) and horse (Hillmann, *loc. cit.*; Nickel, *loc. cit.*). The masseteric fosse in the mandible of rhino presented few rough lines for muscular attachment like that of cattle (Raghavan, *loc. cit.*), buffalo (Khatra, *loc. cit.*). The mandibular foramen was situated in the medial surface close to the alveolar border of the vertical part which simulated the findings in horse (Hillmann, *loc. cit.*; Nickel, *et al.*, *loc. cit.*). However, in cattle the mandibular foramen was located in the middle of the medial surface of the vertical part (Raghavan, *loc. cit.* and Nickel, *et al.*, *loc. cit.*) and more caudally in buffalo (Khatra, *loc. cit.*). The neck was thick, constricted and short. Mediolaterally, the condyle was grooved unlike in the horse (Hillmann, *loc. cit.*; Nickel, *et al.*, *loc. cit.*), ox (Raghavan, *loc. cit.*).

The coronoid process projected upwards and slightly backwards and inwards, whereas it was strongly backwards and outwards in cattle (Raghavan, *loc. cit.*) and curved

slightly medially and caudally in horse (Hillmann, *loc. cit.*; Nickel *et al. loc. cit.*). The labial surface of the mandible of rhino exhibited few larger foramina which were not reported in other domestic animals.

Summary

Six numbers of mandibles of Indian one horned rhinoes were studied. The mandible of rhino was the largest bone of the skull. There were 4 alveoli for lower incisors and 6 alveoli for the cheek teeth. The mandibular foramen was situated in the medial surface closer to the alveolar border of the vertical part. The mental foramen was present at the level of the 2nd cheek tooth. The coronoid process was pointed at the extremity and wide at the base. The mandibular notch was wide.

Acknowledgement

The authors are grateful to the Director of Research (Vety.), AAU, Khanapara and Department of Forest, Govt. of Assam for providing necessary facilities and for encouragement during the course of this investigation.

REFERENCES

- Hillmann, D.J. (1977) ... In "Sisson and Grossman's The Anatomy of the Domestic Animals" Vol.I., The MacMillan Co. of India Ltd., Delhi, p.318, p.1231.
- Jerdan, T.C. (1984) ... In "A Handbook of the Mammals of India", Mittal Publications, Delhi. p.234.
- Khatra, G.S. (1978) ... Ph.D. Thesis, Haryana Agricultural University, Hissar.
- May, N.D.S. (1970) ... In "The Anatomy of the Sheep - A dissection manual", 3rd edn., University of Queensland press, Queensland, p. 282.
- Miller, M.S., Christensen, G.C. and Evans, H.E. (1964) ... In "Anatomy of Dog", 2nd edn. W.B. Saunders Co., Philadelphia, p.36, p.113.
- Nickel, R., Schummer, A. and Seifrlle, E. (1981) ... In "Anatomy of the Domestic Animals"" Verlag Paul Parey, Berlin, Hamburg. pp.122 - 124.
- Raghavan, D. (1964) ... "In Anatomy of Ox", Indian Council of Agricultural Research, New Delhi, p.76.
- Sisson, S. (1977) ... In "Sisson and Grossman's The Anatomy of the Domestic Animals", Vol.I, The MacMillan Co. of India Ltd., Delhi, p. 769.

I.V.J. BUILDING FUND

Liberal contributions towards IVJ Building Fund in the form of Cash, M.O., or Bank draft drawn in favour of the IVJ Building Fund Account payable at a bank in Madas are solicited.

Editor
