

Clinicopathologic Correlations of Tuberculosis in Large Zoo Mammals

Peter C. Mann, DVM; Mitchell Bush, DVM; Donald L. Janssen, DVM; Elizabeth S. Frank, BS; Richard J. Montali, DVM

SUMMARY

In August 1978, a black rhinoceros at the National Zoological Park died with generalized tuberculosis caused by *Mycobacterium bovis*. A 2nd black rhinoceros was euthanatized 9 months after *M bovis* was cultured from its lungs. After these 2 deaths, numerous large zoo mammals that had been potentially exposed were subjected to various procedures to ascertain their status regarding tuberculosis. The procedures were: intradermal tuberculin testing, evaluation of delayed hypersensitivity reaction on biopsy specimens, enzyme-linked immunosorbent assay (ELISA) testing, and culture of various secretions and organs. Several of the animals in this series died during the study. These were necropsied and examined for evidence of mycobacterial infection. The results of tuberculin testing varied from species to species and from site to site within a species. Delayed hypersensitivity responses generally correlated well with the amount of swelling at the tuberculin site. In some cases, however, positive reactions were found without any delayed hypersensitivity response. Results of ELISA testing were confirmatory in tuberculous animals. Several species were judged to be nonspecific reactors, based on positive or suspect tuberculin test results, with negative ELISA results and necropsy findings.

(*Diceros bicornis*) died from tuberculosis caused by *M bovis* and one was euthanatized with the same condition. These animals had been housed in the elephant house at the NZP, where others may have been exposed.

After the death of these 2 rhinoceros, the tuberculin testing program was intensified. There are several problems associated with tuberculin testing in large zoo mammals. First, the intradermal skin test, which is the accepted method for the detection of tuberculosis of domestic hoofstock,⁵ primates,⁶ and man,⁷ has not been standardized in many large zoo mammals. It is not always possible, therefore, to determine a positive versus a suspect reaction, especially when comparing reactions between different species of mammals. Second, due to anatomic peculiarities (eg, thick skin, armored plates) of large zoo mammals, it is not always possible to administer tuberculin tests in similar locations in all species. Last, laboratory tests such as enzyme-linked immunosorbent assay (ELISA) and lymphocyte transformation have been used on a limited basis in large zoo mammals.^{8,9} The results of such tests have not permitted us to develop firm guidelines in determining whether a large zoo animal has tuberculosis.

The purpose of this report is 2-fold: (1) to describe the pathologic findings in 2 black rhinoceros with *M bovis* infections, and (2) to describe the tuberculosis surveillance that has evolved at NZP since the death of these 2 animals.

Materials and Methods

A protocol with several tests was used for tuberculosis surveillance at the NZP. Because of some difficulties with restraint, not every test was used on each animal.

Tuberculin Testing—In most cases, large zoo mammals had to be anesthetized prior to tuberculin testing. Some or all of the following tuberculins were used: mammalian old tuberculin, purified protein derivative-bovis (PPD-B), avian old tuberculin, purified protein derivative-avian (PPD-A), saline control, and medium control, which consisted of old tuberculin without mycobacterial antigen. These tuberculins were injected intradermally at a dose of 0.1 ml. The injection site varied with each animal. The caudal tail fold was usually employed. Simultaneous tests were done on the abdomen, the perineum below the caudal tail fold, near the ears, on the neck or shoulders, or on the vulvar fold.

The animals were reanesthetized at 72 hours to palpate and to measure the tuberculin test sites; punch or

MAMMALIAN TUBERCULOSIS, whether caused by *Mycobacterium bovis*, *M tuberculosis*, or *M avium*, is a problem with a long history in zoological settings throughout the world.¹⁻³ At the National Zoological Park (NZP), tuberculosis has been a sporadic cause of death in mammals as well as birds throughout this century.⁴ During the past decade, most death losses to tuberculosis have been in birds; mammalian tuberculosis has been the cause of death in isolated cases only.⁴ In 1978 and 1979, one black rhinoceros

From the Departments of Pathology (Mann, Montali), Animal Health (Bush, Janssen), and Animal Programs (Frank), National Zoological Park, Smithsonian Institution, Washington, DC 20008.

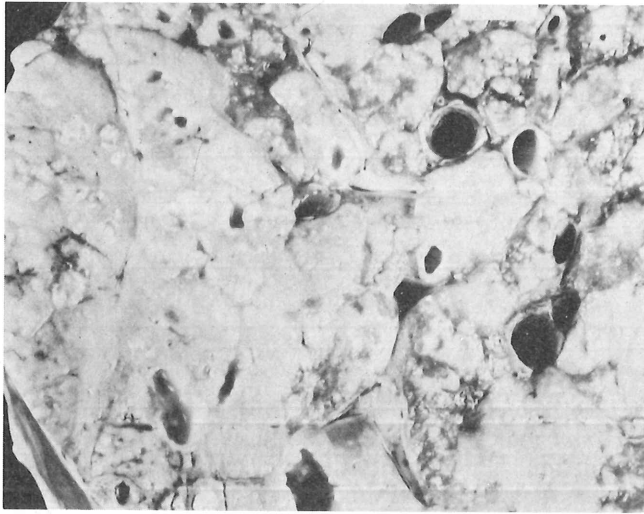


Fig 1—Lung, black rhinoceros BR1. Parenchyma replaced by confluent areas of consolidation, with purulent cavitations.

excision biopsies were also performed. A few animals did not need general anesthesia to evaluate the tuberculin test sites; biopsy specimens in these cases were obtained after inducing local anesthesia. In 1 black rhinoceros (BR2), percutaneous lung biopsy specimens were obtained on 2 occasions while the animal was anesthetized.

Cultures—Tissues suspected of harboring mycobacteria were examined microscopically in our laboratory, using Kinyoun's acid-fast stain. Acid-fast positive specimens were then cultured on Lowenstein-Jensen medium. Subcultures or tissue specimens in sodium borate were sent to the National Veterinary Services Laboratories, Animal and Plant Health Inspection Service, US Department of Agriculture, Ames, Iowa, for cultural confirmation and serotyping. Sputum and specimens from the trachea, nasopharynx, and stomach for attempted isolation of acid-fast bacteria were obtained by injecting small amounts of sterile saline solution into an endotracheal tube while the animal was anesthetized; specimens of lung were obtained by percutaneous biopsy. Postmortem specimens were obtained aseptically for acid-fast bacteria and prepared for culture as previously described.

Enzyme-Linked Immunosorbent Assay—The ELISA was used according to methods described by Thoen et al for large zoo mammals.⁸ Serum was tested in our laboratories, using one or more of the following antigens: *M bovis* AN5, *M bovis* PPD, *M avium* serotype 1, or *M avium* PPD.⁸ Results were reported on a semiquantitative basis, based on degree of color change at a 1:20 dilution, from 1+ for a mild change to 4+ for a marked change.

Delayed Hypersensitivity Reaction—Biopsy specimens were processed by routine methods; 6µm-thick sections

*These antigens were prepared as described⁸ and were obtained from Dr. Charles Thoen, Ames, Iowa.

TABLE 1—Clinicopathologic Correlations of Tuberculosis in Black Rhinoceros

Animal	Date	Test (location)	Results	DHS*
BR1	July 1978	Necropsy	Generalized granulomatous disease	...
		Culture (lung, bronchial lymph node)	<i>M bovis</i>	...
		ELISA, <i>M bovis</i> AN5	3+†	...
		ELISA, <i>M bovis</i> PPD	2+	...
BR2	Sept 1978	MOT (caudal tail fold)	1-cm nodule	4+
		PPD-B (caudal tail fold)	1-cm nodule	3+
		AOT (abd)	0.5-cm nodule	2+
		PPD-A (abd)	0.5-cm nodule	1+
		Culture (trachea, bronchus)	Negative for mycobacteria	...
		Culture (lung biopsy)	<i>M bovis</i>	...
		ELISA, <i>M bovis</i> AN5	3+	...
	March 1979	ELISA, <i>M bovis</i> PPD	3+	...
		MOT (caudal tail fold)	3-cm nodule	NB
		AOT (caudal tail fold)	8-cm nodule	NB
		Culture (trachea)	Negative for mycobacteria	...
		Culture (lung biopsy)	Negative for mycobacteria	...
		ELISA, <i>M bovis</i> AN5	2+	...
		ELISA, <i>M bovis</i> PPD	2+	...
June 1979	Necropsy	Granulomatous pneumonia	...	
	Acid-fast stain	Positive	...	
	Culture (lung, liver, testicle, portal lymph node)	Negative for mycobacteria	...	
	ELISA, <i>M bovis</i> AN5	4+	...	
BR3	Dec 1978	ELISA, <i>M bovis</i> PPD	3+	...
		MOT, PPD-B (caudal tail fold)	Negative	NB
	June 1979	MOT, PPD-B, AOT, PPD-A (abd)	Negative	NB
		MOT (caudal tail fold)	5-cm nodule	3+
		MOT (eyelid)	Swollen (positive)	NB
	Jan 1980	ELISA, <i>M bovis</i> AN5	3+	...
		ELISA, <i>M bovis</i>	1+	...
		ELISA, <i>M avium</i> , serotype 1, PPD	Negative	...
		Culture (trachea)	Negative for mycobacteria	...
		MOT (vulvar fold)	1-cm nodule	NB
		ELISA, <i>M bovis</i> AN5	3+	...
		MOT (caudal tail fold)	Diffuse thickening	1+
	May 1980 Dec 1980	Necropsy	Hemolytic anemia	...
		Culture (liver, bronchial lymph node)	Negative for mycobacteria	...
MOT, PPD-B (caudal tail fold)		Negative	NB	
BR4	Dec 1978 June 1979	MOT (caudal tail fold)	1.5-cm nodule	3+
		ELISA, <i>M bovis</i> AN5	2+	...
		Culture (trachea)	Negative for mycobacteria	...
	Jan 1980	MOT, MC (caudal tail fold)	Negative	NB
		MOT, PPD-B, MC (abd)	Negative	NB
		ELISA, <i>M bovis</i> AN5	2+	...
	May 1980 June 1981	MOT, MC (caudal tail fold)	Negative	Negative
		MOT (neck)	Diffuse thickening	2+
	AOT (neck) MC (neck)	AOT (neck)	4-cm nodule	3+
		MC (neck)	Diffuse thickening	Negative

*Delayed hypersensitivity reactions were graded 1+ (minimal), 2+ (mild), 3+ (moderate), 4+ (marked). †ELISA results were semiquantitatively graded 1+ (mild) to 4+ (strongly positive).

MOT = mammalian old tuberculin; AOT = avian old tuberculin; PPD-B = purified protein derivative, bovine; PPD-A = purified protein derivative, avian; MC = medium control; abd = abdomen; NB = not biopsied.

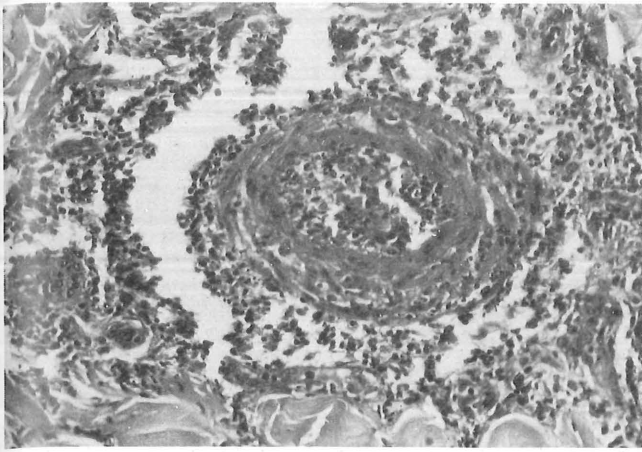


Fig 2—Tuberculin test site, black rhinoceros BR2 (mammalian old tuberculin). Marked delayed hypersensitivity reaction consisting of perivascular lymphocytes and macrophages. H&E stain; $\times 150$.

were stained with hematoxylin and eosin. Slides were examined by light microscopy and any mononuclear cell reaction was graded according to Gladstone's criteria.¹⁰ Reactions were identified as delayed hypersensitivity type if they consisted predominantly of large and small lymphocytes and macrophages, with a perivascular orientation in the dermis. These were graded as follows: 0, no reaction; 1+, minimal reaction; 2+, mild reaction; 3+, moderate reaction; and 4+, marked reaction.

Background

In late August 1978, a 20-year-old female African black rhinoceros (BR1) at the NZP died after a 3-day illness during a period of extreme heat and humidity. Gross findings include enlargement of superficial and deep lymph nodes and a generalized lack of cavitory fat stores. The lungs (Fig 1) had numerous cavitations with greenish purulent centers. The liver contained many 1- to 2-mm tannish white spots throughout the parenchyma. Histopathologic findings were typical of disseminated tuberculosis. Acid-fast stains of the lungs, lymph nodes, and liver were positive. *Mycobacterium bovis* was isolated from the lungs and lymph nodes. Serum was obtained from BR1 shortly before its death; the ELISA was positive (Table 1).

After the death of BR1, its mate (BR2) was evaluated for tuberculosis (Table 1). Mammalian old tuberculin, PPD-B, and avian old tuberculin produced positive results. Biopsy results were as follows: mammalian old tuberculin—marked delayed hypersensitivity (Fig 2); PPD-B—moderate delayed hypersensitivity (Fig 3); and avian old tuberculin—mild delayed hypersensitivity (Fig 4). *Mycobacterium bovis* was isolated from a lung biopsy specimen. On the basis of this information, BR2 was treated as an active case of tuberculosis; isoniazid therapy was begun in December 1978 at a rate of 7 g/day. This dosage was doubled in February 1979. Mammalian and avian old tuberculin tests were positive in March 1979. At this time, tracheal cultures and lung biopsy were negative for mycobacteria.

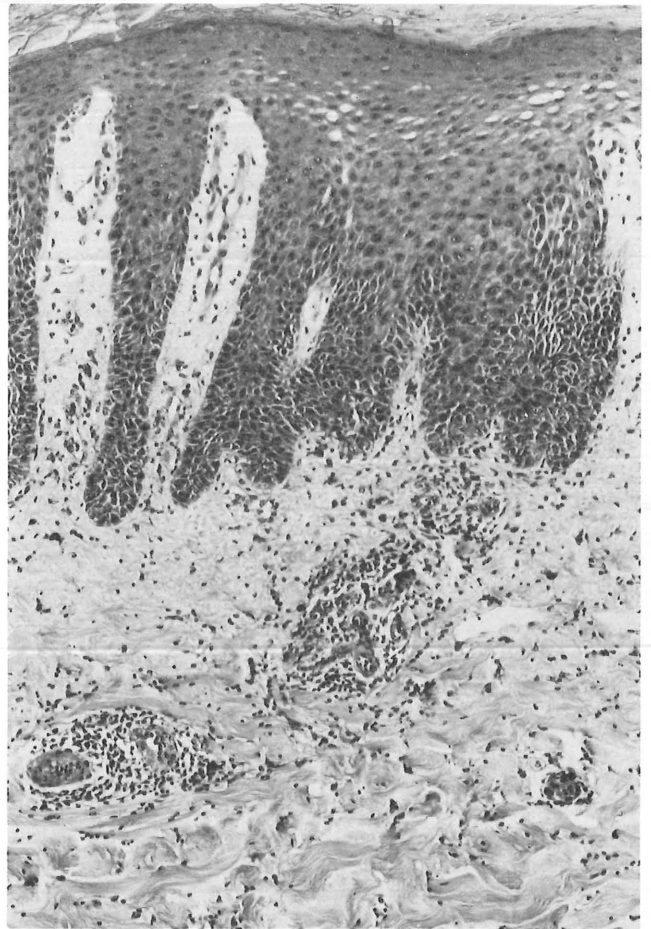


Fig 3—Tuberculin test site, black rhinoceros BR2 (PPD-B). Moderate delayed hypersensitivity reaction consisting of perivascular lymphocytes and macrophages. H&E stain; $\times 83$.

In June 1979, a decision was made to euthanize BR2 because (1) it had had evidence of active tuberculosis; (2) 2 other black rhinoceros (BR3 and BR4) had recently become positive to the tuberculin test; and (3) the effect of isoniazid was unknown in these great mammals. Thus, it was believed that the risk of infection to other rhinoceros and to the zoo-going public outweighed the exhibit value of the animal. At necropsy, the major lesions were seen in the lungs: nodular-like lesions replacing parenchyma, which on cut surface contained greenish suppurative centers. Microscopically, the lungs contained suppurative granulomas with giant cells and areas of alveolar wall fibrosis. Acid-fast stains of the lung lesions were positive; however, cultures of lung, liver, testicle, and portal lymph nodes failed to yield any mycobacteria.

Serum from BR2 was tested against *M bovis* AN5 and *M bovis* PPD by the ELISA, with positive results on several occasions.

Tuberculosis Testing Program at the NZP—In the aftermath of the deaths of the 2 black rhinoceroses, an intensified program for detection of tuberculosis was initiated at the NZP. The procedures used are described in the Materials and Methods section. In addition, several of the animals died during the study; necropsies were performed on these animals

TABLE 2—Clinicopathologic Correlations of Tuberculosis in Indian Rhinoceros

Animal	Date	Test (location)	Results	DHS*
IR1	Jan 1976	ELISA, <i>M bovis</i> AN5†	3+	...
	Aug 1978	ELISA, <i>M bovis</i> AN5	2+	...
	Apr 1979	MOT (ear)	1.5-cm nodule	NB
		MOT, PPD-B, PPD-A (abd)	Negative	NB
	Mar 1980	ELISA, <i>M bovis</i> AN5	3+	...
		<i>M bovis</i> PPD	2+	...
		MOT (caudal tail fold)	2-cm nodule	1+
		MOT (neck)	Slight nodule	3+
	Sept 1980	ELISA, <i>M bovis</i> AN5	3+	...
		Necropsy	Gastric impaction, pyloric-duodenal torsion	...
Acid-fast smear (bronchial lymph node)		Negative	...	
	Culture (bronchial lymph node)	Negative for mycobacteria	...	
IR2	Mar 1979	MOT, PPD-B, AOT, PPD-A (abd)	Slight swelling	NB
	Mar 1980	MOT (caudal tail fold)	2-cm thickening	3+
		PPD-B (caudal tail fold)	1.5-cm thickening	NB
	Mar 1981	ELISA, <i>M bovis</i> AN5	2+	...
		MOT (cervical)	0.5-cm nodule	...

*Delayed hypersensitivity reactions were graded 1+ (minimal), 2+ (mild); 3+ (moderate), 4+ (marked). †ELISA results were semiquantitatively graded 1+ (mild) to 4+ (strongly positive).

abd = abdomen; NB = not biopsied; MOT = mammalian old tuberculin; AOT = avian old tuberculin; PPD-B = purified protein derivative, bovine; PPD-A = purified protein derivative, avian.

to eliminate the possibility of tuberculosis. Subsequently, a detailed description of the history and results of the various procedures done on several of the animals being monitored is given.

Black Rhinoceros—A 3rd black rhinoceros (BR3), a female, had been bred by BR1 in August 1976 and then had been moved to another yard in August 1977. It had a male calf (BR4) in January 1978. These 2 animals were tuberculin tested (Table 1) in December 1978, with negative results. When these 2 rhinoceros were retested in June 1979, tuberculin reactions were positive, with moderate delayed hypersensitivity reactions. For BR3, the ELISA was positive against the mammalian antigens. Tracheal washings cultured negative for mycobacteria. Tuberculin tests administered in January 1980 and May 1980 were negative. Black rhinoceros 3 died in December 1980 after a peracute episode of hemolytic anemia. Evidence of granulomatous disease was not seen at necropsy.

Black rhinoceros 4, which had never had direct exposure to BR1 or BR2, was first tuberculin tested in December 1978, when it was approximately 1 year old. Results were negative (Table 1). In June 1979, a mammalian old tuberculin test (tail fold) was positive. Cultures of tracheal washes failed to yield any mycobacteria.

In June 1981, a mammalian old tuberculin test was negative, while avian old tuberculin produced positive results.

Isoniazid therapy was begun on BR3 and BR4 immediately after their conversion to a positive tuberculin test (14 g/day for the adult female, BR3, and 7 g/day for the younger male, BR4). This therapy was continued on both animals until BR3 died.

Indian Rhinoceros—An adult female Indian rhinoceros (*Rhinoceros unicornis*, IR1) was first tested in April 1979 (Table 2). A mammalian old tuberculin injection site behind the ear was positive, whereas an abdominal mammalian old tuberculin site was negative. Approximately 1 year earlier, urine- and feces-soaked straw from BR1, the animal that died from generalized tuberculosis, had been put in the

pen with IR1 and its mate (IR2) to stimulate sexual activity through pheromones. Both Indian rhinoceros took a liking to this material and ate it.

In March 1980, another series of tuberculin tests were administered. A mammalian old tuberculin test was positive in the tail fold but negative in the neck.

In September 1980, IR1 died suddenly. Necropsy findings were gastric impaction and pyloric-duodenal torsion, with no evidence of granulomatous disease.

A 2nd animal, IR2, was housed in the yard adjacent to IR1. It was tuberculin tested on 3 occasions (Table 2). This animal has since been sent to another zoo on a breeding loan.

Both of the Indian rhinoceros were started on isoniazid therapy in March of 1980. The IR1 was being treated when it died; treatment for IR2 was discontinued in December 1980.

Nile Hippopotamus—A 24-year-old male Nile hippopotamus (*Hippopotamus amphibius*; NH1) was tuberculin tested in May 1980. Mammalian old tuberculin produced a 2-cm nodule in the tail fold and an area of induration in the neck that was 5 cm in diameter at 72 hours and 8 cm at 144 hours. Avian old tuberculin produced a 3-cm nodule with a necrotic center in the caudal tail fold. The ELISA was negative for both *M bovis* and *M avium* PPD.

In November 1980, NH1 was anesthetized for further testing. Thirty minutes after reversal of anesthesia, using etorphine,^b the animal suddenly died. Necropsy findings were compatible with congestive heart failure and postanesthetic shock. There was no evidence of granulomatous disease.

Pygmy Hippopotamus—A 40-year-old female pygmy hippopotamus (*Choeropsis liberiensis*; PH1) was tested in May 1980. Mammalian old tuberculin injected in the caudal tail fold produced a 5-cm nodule with an ulcerated center (Fig 5). Biopsy of the site revealed a mild delayed hypersensitivity reaction. The ELISA was negative for *M bovis* PPD and *M avium* PPD.

^bM-99, D-M Pharmaceutical Inc, Rockville, Md.

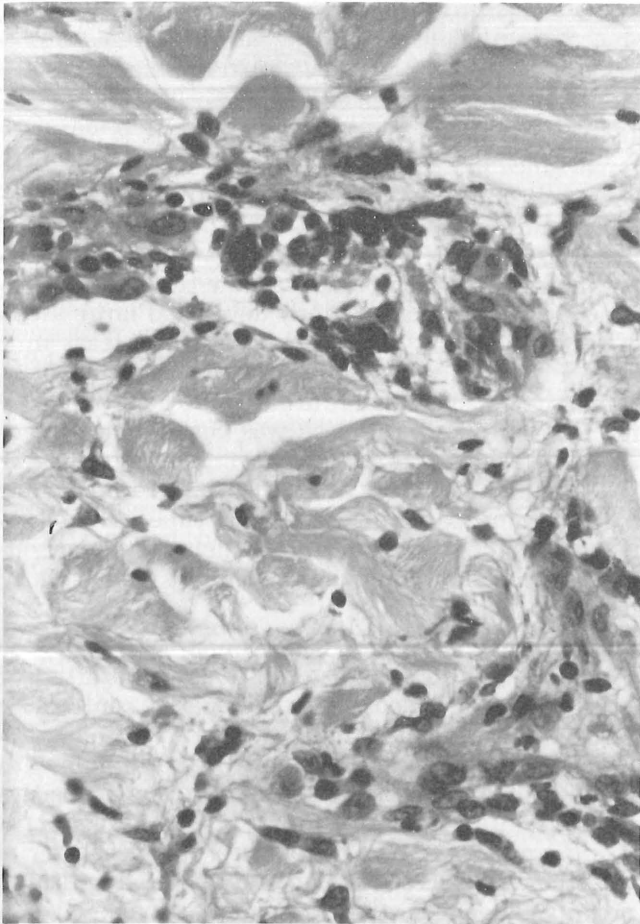


Fig 4—Tuberculin test site, black rhinoceros BR2 (avian old tuberculin). Mild delayed hypersensitivity reaction consisting of perivascular lymphocytes and macrophages. H&E stain; $\times 302$.

This animal (PH1) was euthanatized in May 1980 because of advanced renal disease. There was no evidence of granulomatous disease at necropsy.

Pygmy hippopotamus 2, a 15-year-old female, was tested in May 1980. Testing with mammalian and avian old tuberculin sites in the shoulder produced results similar to that seen in PH1.

African Elephant—A 24-year-old female African elephant (*Loxodonta africana*) was tuberculin tested in July 1979 and March 1980. Mammalian old tuberculin produced a 4-cm nodule in the caudal tail fold. Biopsy revealed a mild delayed hypersensitivity reaction. The ELISA and tracheal washings were negative.

Asian Elephant—A 4-year-old female Asian elephant (*Elephas maximus*) was tuberculin tested in March 1980. Mammalian old tuberculin produced a 3 \times 4-cm nodule; biopsy of this site was negative for delayed hypersensitivity. The ELISA was also negative (*M bovis* AN5 and *M avium*, serotype 1).

Tapir—A 1-year-old male Brazilian tapir (*Tapirus terrestris*) was acquired by the NZP in July 1980. This animal was tuberculin tested while in quarantine. An abdominal injection of mammalian old tuberculin produced a 0.9-cm nodule with hyperemia; biopsy revealed a moderate delayed

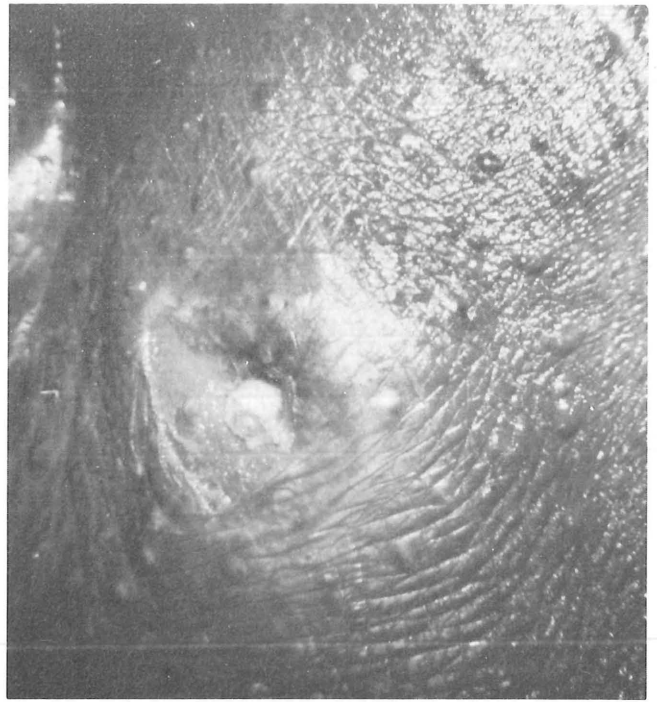


Fig 5—Tuberculin test site, pygmy hippopotamus PH1. Caudal tail fold, mammalian old tuberculin. There was a 5-cm diameter nodule with ulcerated center at 72 hours.

hypersensitivity reaction. The ELISA was positive against all 4 antigens.

Three other tapirs in the collection had been tuberculin tested earlier, with negative results. The ELISA was negative for both mammalian and avian antigens in all cases. On the basis of these findings, the tapir with the positive reaction was not allowed to enter the general collection.

Discussion

Tuberculosis caused by *M bovis* does not appear to be an ongoing problem in the elephant house at the NZP. In the 3 years since the death of BR1, 4 animals in the elephant house have died from unrelated causes. All of these animals (BR3, IR1, NH1, and PH1) were thoroughly examined at necropsy for evidence of granulomatous disease: findings were negative in all cases.

The interpretation of the intradermal tuberculin test in large zoo animals is difficult. In man,⁷ a 1-cm induration is a positive reaction. Anything less is considered a nonspecific reaction. There is no similar applicable standard in large zoo mammals. In the case of the black rhinoceros, BR2 had a 1-cm nodule (mammalian old tuberculin) in September 1978, when it was shown to be harboring *M bovis* in its lungs. Seven months later, after isoniazid therapy, the size of the mammalian old tuberculin nodule was 3 cm, while an avian old tuberculin injection produced an 8-cm nodule. Black rhinoceros 3, which was shown at necropsy to be free of granulomatous disease, was initially negative on skin testing but later converted to positive, with a mammalian old tuberculin reaction that was larger (5 cm) than that seen in the positive animal (BR2).

Black rhinoceros 4, which is assumed to be free of tuberculosis, had a 1.5-cm nodule (mammalian old tuberculin) after it converted to positive; the largest reaction in this animal (4 cm) was from avian old tuberculin.

In man, *M avium* and other nontuberculous mycobacteria will cause positive skin reactions.⁷ In the South Atlantic region of the United States (where the NZP is located), large numbers of nontuberculous mycobacteria have been isolated in cases of human infection.¹¹ Many of the nontuberculous mycobacteria can be cultured from soil and water; the Nile and pygmy hippopotamuses spend most of their time in an aquatic environment. *Mycobacterium avium* is still a problem at the NZP. In the recent past, 10 to 45 birds have died from the disease each year. Although the numbers have declined in the past 2 years,⁴ *M avium* is most certainly still in the environment.

Several of the animals in this series (BR2, BR4, NH1, and PH2) had reactions to avian tuberculin that were as large or larger than those produced by mammalian tuberculins. With the exception of BR2, none of these animals has been shown to be tuberculous; in fact, NH1 was found to be free of granulomatous disease at necropsy. The lack of findings at necropsy (NH1) and the negative culture results (BR4) strongly suggest that the strong positive reactions to avian tuberculin in these animals are attributable to a hypersensitivity to nontuberculous mycobacteria in the environment.

In large zoo mammals, the site for the tuberculin test appears to be quite important. The mammalian old tuberculin site behind the ear of IR1 was positive in April 1979, whereas the same tuberculin was negative in the abdomen. In March 1980, injection of mammalian old tuberculin in the caudal tail fold produced a 2 cm nodule, whereas mammalian old tuberculin in the neck produced a slight nodule. Nile hippopotamus 1 developed a nodule from mammalian old tuberculin in the neck that was 8 cm in diameter at 144 hours; mammalian old tuberculin in the tail fold produced only a 2-cm nodule. These varying results suggest that it is impossible to predict 1 preferred site when crossing species lines.

The evaluation of biopsy specimens for delayed hypersensitivity reaction shows promise when combined with other techniques. In the case of 1 of the tuberculous animals (BR2), the response was greatest in the mammalian tuberculin sites (mammalian old tuberculin, PPD-B) and less reactive in the 2 avian sites. In the case of BR4, the 3+ delayed hypersensitivity reaction seen with avian old tuberculin was consistent with the large size of the nodule when compared with the smaller swelling and 2+ reactions seen with mammalian old tuberculin.

In several cases, the degree of delayed hypersensitivity reaction was to aid in the evaluation of the tuberculin reaction. In the case of BR4, injection of mammalian old tuberculin in the neck produced a diffuse thickening, with a mild delayed hypersensitivity response. In addition, there was an acute

response associated with a small strand of keratin that was probably driven into the dermis by the tuberculin needle. This keratin abscess no doubt contributed to the swelling seen at the site.

The problem of nonspecific reactions is of major importance in large zoo animals. Earlier studies at the NZP indicated that camels, like horses, are nonspecific reactors.^{12,13} On the basis of results in the present series, it appears that pygmy hippopotamuses may also be nonspecific tuberculin reactors, since those in our study developed large areas of induration and necrosis, although at least in 1 case (PH1) had no evidence of mycobacterial infection at necropsy or on culture. In addition, the ELISA for pygmy hippopotamuses was consistently negative. The evidence is similarly compelling to classify the Nile hippopotamus as a nonspecific reactor, since both mammalian and avian old tuberculins produced nodules with moderate delayed hypersensitivity reaction, but the ELISA was consistently negative.

The results from ELISA must be evaluated together with other results. It is generally not possible to provide positive and negative controls for ELISA in large zoo mammals. There was good correlation in the cases of BR1 and BR2, animals with proved tuberculous infection and strongly positive ELISA results. However, BR3 also had a strong ELISA result and was shown to be free of mycobacterial infection at necropsy. The BR4, which cultured negative, also had a positive but less marked ELISA result. Inasmuch as BR3 and BR4 had been on isoniazid therapy for 18 months, the failure to isolate mycobacteria might be expected. Indian rhinoceros 1, which had no evidence of mycobacterial infection at necropsy, similarly had a positive ELISA result. Both Nile hippopotamuses were consistently negative on ELISA; NH1 was shown to be negative for granulomatous disease at necropsy. These results, in conjunction with tuberculin tests and biopsy evaluation, have prompted us to regard the Nile hippopotamus and Indian rhinoceros as nonspecific reactors.

The 2 elephants in this series were ELISA-negative against the mammalian and the avian antigens. These animals had positive tuberculin tests but mild or negative delayed hypersensitive reactions. The African elephant had a negative tracheal culture. On the basis of these data, we consider both species of elephants to be nonspecific reactors to intradermal tuberculin injection. In an earlier study on Asian elephants,⁸ animals with negative skin test results had suspect ELISA results; however, there were no animals with positive tuberculin reactions and negative ELISA results.

The situation with the tapir provides perhaps the best protocol for evaluation of tuberculosis in large zoo mammals. This animal was positive on tuberculin testing at 72 hours. Biopsies of the test sites provided confirmatory evidence that the nodules were caused by a delayed hypersensitivity reaction. The ELISA results were positive in varying degrees.

The decision to return this animal to its zoo of origin was made by comparing the results obtained with those from 3 other tapirs in our collection (negative tuberculin test and ELISA results). Unfortunately, it is often not possible to perform this complete an intraspecific protocol.

The effects of isoniazid therapy are not well known in large zoo mammals. It appears that isoniazid had a beneficial effect in BR2, inasmuch as it was not possible to culture viable mycobacteria from this animal at necropsy, even though acid-fast organisms were seen with special stains. In the case of BR3 and BR4, isoniazid was initiated after these animals converted to a positive tuberculin test result. These animals later became negative on tuberculin testing, a situation that has been seen in other large zoo animals.¹⁴

Hemolytic anemia has been reported in man after isoniazid therapy.¹⁵ We were concerned about a similar situation when BR3 died with peracute anemia. However, a syndrome of hemolytic anemia has been observed in several black rhinoceros, none of which was on isoniazid therapy at the time of death.^{16,c}

In man, definitive diagnosis of tuberculosis normally requires demonstration of mycobacteria in the patient's tissues or secretions by microscopy or culture¹⁷; it seems reasonable that similar criteria should be applied to zoo animals. Unfortunately, these techniques are often performed only at necropsy in large zoo animals. Because of the expense and rarity of many of these animals, this is not a feasible solution.

A more reliable method of evaluating the tuberculosis status of large zoo mammals is needed. The tuberculin test alone is not a reliable index to exposure. Too many animals have false-positive and nonspecific reactions. Until such time as specific guidelines for evaluating tuberculin tests in each species have been formulated, it is our opinion that a combination of clinical judgment, tuberculin testing, examination of biopsy specimens, and ELISA can

be used in conjunction to make specific recommendations and evaluations of individual cases.

References

1. Snyder RL: Historical aspects of tuberculosis in the Philadelphia Zoo, in Montali RJ (ed): *Mycobacterial Infections of Zoo Animals*. Washington, DC, Smithsonian Institution Press, 1978, pp 33-44.
2. Griner LA: Occurrence of tuberculosis in the zoo collection of the Zoological Society of San Diego, 1964-1975, in Montali RJ (ed): *Mycobacterial Infections of Zoo Animals*. Washington, DC, Smithsonian Institution Press, 1978, pp 45-53.
3. Schliesser TA: Prevalence of tuberculosis and mycobacterial diseases in some European zoos, in Montali RJ (ed): *Mycobacterial Infections of Zoo Animals*. Washington, DC, Smithsonian Institution Press, 1978, pp 29-32.
4. *Annual Report, National Zoological Park*. Washington, DC, Smithsonian Institution Press, 1918-1978.
5. Lepper AWD, et al: The use of bovine PPD tuberculin in the single caudal fold test to detect tuberculosis in beef cattle. *Aust Vet J* 53:208-213, 1977.
6. McLaughlin RM, Marrs GE: Tuberculin testing in non-human primates: OT vs PPD, in Montali RJ (ed): *Mycobacterial Infections of Zoo Animals*. Washington, DC, Smithsonian Institution Press, 1978, pp 123-128.
7. Reichman LB: Tuberculin skin testing: The state of the art. *Chest* 76S:764S-770S, 1979.
8. Thoen CO, Mills K, Hopkins MP: Enzyme-linked protein A: An enzyme-linked immunosorbent assay reagent for detecting antibodies in tuberculous exotic animals. *Am J Vet Res* 41:833-835, 1980.
9. Johnson DJ, Soper FT, Rakich PM: Lymphocytic transformation as a diagnostic tool in tuberculosis of exotic animals, in Montali RJ (ed): *Mycobacterial Infections of Zoo Animals*. Washington, DC, Smithsonian Institution Press, 1978, pp 135-138.
10. Gladstone GP: Reactions to exogenous allergens: Atopy and delayed hypersensitivity, in Florey HW (ed): *General Pathology*, ed 4. Philadelphia, WB Saunders Co, 1970, pp 1109-1136.
11. Good RC: Isolation of non-tuberculous mycobacteria in the United States, 1979. *J Infect Dis* 142:779-783, 1980.
12. Kennedy S, Bush M: Evaluation of tuberculin testing and lymphocytic transformation in Bactrian camels, in Montali RJ (ed): *Mycobacterial Infections of Zoo Animals*. Washington, DC, Smithsonian Institution Press, 1978, pp 139-143.
13. Konyha LD, Kreier JP: The significance of tuberculin tests in the horse. *Am Rev Respir Dis* 103:91-99, 1971.
14. Fowler ME: Treating giraffes with isoniazid, in Montali RJ (ed): *Mycobacterial Infections of Zoo Animals*. Washington, DC, Smithsonian Institution Press, 1978, pp 185-188.
15. Isoniazid: *Physicians' Desk Reference*. Oradell, NJ, Medical Economics Co, 1981, pp 1072-1073.
16. Douglass EM, Plue RE: Hemolytic anemia suggestive of leptospirosis in the black rhinoceros. *J Am Vet Med Assoc* 177:921-923, 1980.
17. Glassroth J, Robbins AG, Snider DE: Tuberculosis in the 1980's. *N Engl J Med* 302:1441-1450, 1980.

^cBegg T, Howlett's Zoo, Centerbury, Kent, England: Personal communication, 1981.