

# Degenerative Arthritis in a Black Rhinoceros

J. D. Wallach, B.S., D.V.M.

## SUMMARY

Necropsy of an aged, free-ranging black rhinoceros with clinical signs of lameness revealed multiple lesions of advanced degenerative arthritis, complicated in the femoral head by the loss of the ligamentum teres and its associated blood supply.

Degenerative joint disease is considered a normal senile change.<sup>2-4,6</sup> Classically, the disease is slowly progressive,<sup>3,4</sup> permitting a concurrent functional compensation to occur. When the process appears early in life<sup>3,4</sup> or progresses at an accelerated rate,<sup>3,4</sup> resulting in pain and impairment of locomotion,<sup>4</sup> it can be regarded as a pathologic state.

Juvenile hyaline cartilage is blue-white,<sup>3,4</sup> smooth,<sup>3,4</sup> translucent,<sup>3,4</sup> and elastic.<sup>4</sup> As aging progresses, cartilage becomes inelastic,<sup>4</sup> opaque,<sup>4</sup> grainy,<sup>1,3,4</sup> and gray or yellow.<sup>4</sup> While the associated bone continues to grow, the articular cartilage is capable of interstitial growth;<sup>3,4</sup> when the bone stops growing, the capacity of effective proliferation of chondrocytes is lost,<sup>3,4</sup> except at the junction with the synovial membrane<sup>3,4</sup> or when fractures of the associated joint form a callus;<sup>3,4</sup> therefore, cartilage present at maturity must last the remainder of the animal's life.<sup>4</sup> Investigators have shown this to be attributed to biochemical changes in the chondrocytes<sup>2,3</sup> and synovial fluids.<sup>3</sup>

A bone exposed to the pressures of a moving joint because of a disruption in the continuity of the articular cartilage will become grooved,<sup>2,4</sup> dense,<sup>4</sup> and polished;<sup>2,4</sup> when osteomalacia,<sup>4</sup> osteoporosis,<sup>4</sup> and/or the loss of the ligamentum

teres<sup>5,6</sup> and its blood supply accompany arthritis, there is usually a resultant gross deformity and epiphyseal collapse. There is a marked tendency for the disease to occur more frequently and with a greater degree of severity in the joints that bear the most weight.<sup>2,4</sup> The incidence of the disease can, in some cases, be associated with genetics,<sup>4</sup> traumatic work,<sup>2,3</sup> or injury.<sup>3,5,6</sup>

Degenerative arthritis does occur in wild animals, as it does in man<sup>2,6</sup> and domestic animals.<sup>2,6</sup> The disease has been observed in gorillas,<sup>6</sup> bears,<sup>6</sup> elephants,<sup>1</sup> zebras, aoudads, mouflon, and in the 14 million-year-old fossil of a rhinoceros.<sup>6</sup>

## Case Report

For several weeks an aged and emaciated male black rhinoceros, *Diceros bicornis*, was observed having locomotion difficulties. The animal was eventually found unwilling to rise near a tourist road in Hluhluwe Game Reserve, Zululand, South Africa. It was decided to immobilize the animal for examination, treatment, and transportation to a hospital pen. The combination of 3.0 mg. M.99,\* 50.0 mg. scopolomine, and 4.5 mg. of acetyl promazine maleate\*\* was administered intramuscularly by means

From the Center for the Biology of Natural Systems at the St. Louis Zoological Park, St. Louis, Mo. 63110.

\*M.99, Reckitt & Son, Ltd., Hull, England.

\*\*Acetyl Promazine Veterinary, Boots Pure Drug Company, Nottingham, England.

of a gas-powered rifle\* and a 1-cc. projectile syringe.\*\* The animal rose with difficulty and ambled 20 yards, then turned and watched us until immobilization was complete in 4 minutes.

Physical examination revealed severe emaciation, dependent swelling of both forelimbs, and typical bilateral cutaneous filarid erosions posterior to the scapulohumoral joints. Nalorphine hydrobromide† (250 mg., i.v., and 250 mg., i. m.) was administered as an antagonist to the M.99. The animal did not rise completely but crawled into the crate. The crate was loaded onto a truck for transport to hospital pens in Umfolozi Game Reserve 35 miles away. The rhinoceros died enroute to the pens, and a necropsy was performed.

### Results of Necropsy

Gross necropsy revealed a severely emaciated carcass and advanced degenerative arthritis. Upon examination of all major joints, it was observed that the articular cartilage had become mat-

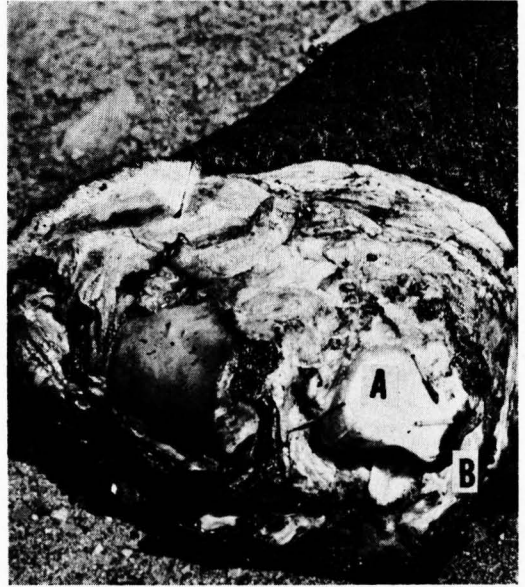

Fig. 1—Distal articulations of metacarpals of an aged black rhinoceros. Left lateral metacarpal has a large eroded area (A), 1.5 by 2.0 cm. Remaining cartilage (B) is darker than normal.

ted in appearance and had acquired a tan color which became more pronounced as the specimen dried.

The distal articular surface of the left lateral metacarpal, associated fabellae, patella, and the right femoral head were affected to a greater degree.

\*Cap-Chur Gun, Palmer Chemical and Equipment Company, Atlanta, Ga.

\*\*Projectile syringes, 1 cc., Palmer Chemical and Equipment Company, Atlanta, Ga.

†Lethidrone, Burroughs Wellcome and Company, London, England.

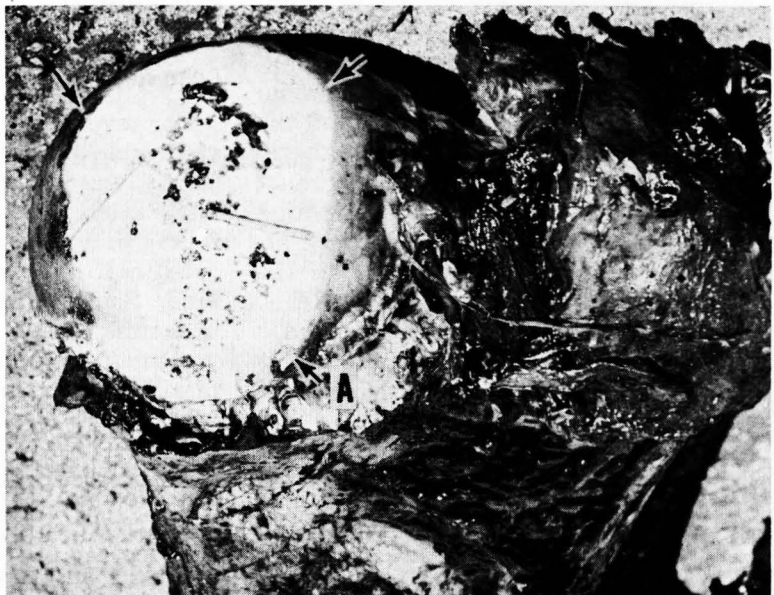

Fig. 2—Right femoral head of rhinoceros described in Figure 1, showing advanced degenerative arthritis. Erosion covering an area 5 by 7 cm. (arrows) exposes underlying cancellous bone. Scalloped exostoses (A) are associated with periarticular edge.

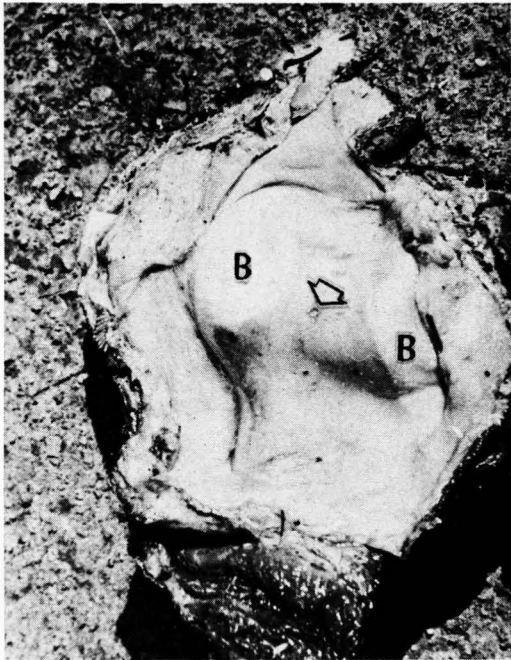


Fig. 3—Articular surface of patella with a central punctate ulcer (arrow), 3.0 mm. in diameter, and 2 linear eroded areas (B), 1.5 by 3.0 cm.

The left lateral metacarpal had a 1.5-by 2.0-cm. eroded area (Fig. 1); the associated fabellae were macerated, and the joint contained one "joint mouse" 2 mm. in diameter.

The ligamentum teres of the right coxofemoral joint was ruptured, resulting in greatly reduced circulation to the femoral head. Three-fourths of the articular cartilage was eroded deeply enough to expose a large area of cancellous bone (Fig. 2). The periarticular edge of

the femoral head had scalloped exostoses. The patella of the right stifle joint had a punctate ulcer 3 mm. in diameter (Fig. 3).

## Discussion

One of the oldest recorded cases of degenerative arthritis was discovered in a 14 million-year-old fossilized rhinoceros.<sup>6</sup> The disease occurred in the femoral head,<sup>6</sup> as did the arthritis cited; both cases were complicated by the loss of the ligamentum teres, with a resultant flattening of the femoral head.<sup>6</sup>

The arthritic lesions of the fossilized femur were the indirect result of a bizarre femoral fracture.<sup>6</sup> In the case of the black rhinoceros reported here, there were generalized lesions indicating a true systemic degenerative disease.

## References

- <sup>1</sup> Fox, H.: *Disease in Captive Wild Mammals and Birds*. J. B. Lippincott Co., Philadelphia, Pa. (1923): 347-348.
- <sup>2</sup> Gesham, G. A., and Jennings, A. R.: *An Introduction to Comparative Pathology*. Academic Press, New York (1962): 325-328.
- <sup>3</sup> Ham, A. W.: *Histology*. 3rd ed. J. B. Lippincott Co., Philadelphia, Pa. (1957): 246, 326-336.
- <sup>4</sup> Jubb, K. V. F., and Kennedy, P. C.: *Pathology of Domestic Animals*. Academic Press, New York (1963): 46-51.
- <sup>5</sup> Junggren, G. L.: Conservative vs. Surgical Treatment of Legg-Perthes' Disease. *Anim. Hosp.*, 2, (1966): 6-10.
- <sup>6</sup> Stecher, R. M., Schultz, C. B., and Tanner, L. G.: A Middle Miocene Rhinoceros Quarry in Morrill County Nebraska (with Notes on Hip Disease in *Diceratherium*). *Bull. Univ. Nebraska State Museum*, 4, (Dec., 1962): 101-111.