

RESEARCH ARTICLE

Body Condition Scoring System for Greater One-Horned Rhino (*Rhinoceros unicornis*): Development and Application

Eva M. Heidegger,¹ Friederike von Houwald,² Beatrice Steck,² and Marcus Clauss^{1*}

¹Clinic for Zoo Animals, Exotic Pets and Wildlife, Vetsuisse Faculty, University of Zurich, Zurich, Switzerland

²Zoo Basel, Basel, Switzerland

Preventing obesity in zoo animals is increasingly recognized as an important husbandry objective. To achieve this goal, body condition scoring (BCS) systems are available for an ever-increasing number of species. Here, we present a BCS for the greater one-horned rhinoceros (*Rhinoceros unicornis*) based on an evaluation (on a scale from 1 to 5) of seven different body regions, and report resulting scores for 62 animals from 27 facilities, based on digital photographs. In animals above 4 years of age, this BCS correlated with the body mass:shoulder height ratio. Although differences between the sexes for individual regions were noted (with consistently higher scores in males for the neck and shoulder and in parous females for the abdomen), the average BCS of all regions did not differ significantly between males (4.3 ± 0.4) and females (4.1 ± 0.5). Linking the BCS to results of a questionnaire survey and studbook information, there were no differences in BCS between animals with and without foot problems or between parous and non-parous females. In a very limited sample of 11 females, those eight that had been diagnosed with leiomyoma in a previous study had a higher BCS (range 3.9–4.9) than the three that had been diagnosed as leiomyoma-free (range 3.5–3.7). The BCS was correlated to the amount of food offered as estimated from the questionnaire. Adjusting the amounts and the nutritional quality of the diet components is an evident measure to maintain animals at a target BCS (suggested as 3–3.5). Zoo Biol. 35:432–443, 2016. © 2016 Wiley Periodicals, Inc.

Keywords: rhinoceros; body condition; obesity; feeding; reproduction; foot lesion

INTRODUCTION

The greater one-horned rhinoceros (*Rhinoceros unicornis*, GOH-rhino) is currently the least threatened of the three still-existing Asian rhinoceros species. It can be found in seven Indian National Parks and Wildlife Sanctuaries, as well as in two National Parks and one Wildlife Sanctuary in Nepal [von Houwald et al., 2014]. According to the International Union for Conservation of Nature and Natural Resources (IUCN), the population in the wild is classified as “vulnerable” [Talukdar et al., 2008] and with current numbers ranging around 3,400 individuals [von Houwald et al., 2014], it is still far from a “near threatened” status. In contrast, the other Asian rhino species, the Sumatran (*Dicerorhinus sumatrensis*) and the Javan rhinoceros (*Rhinoceros sondaicus*), are critically endangered [van Strien et al., 2008a,b]. Rhinos represent examples of species where improvements of the management of ex situ populations are important components of the overall preservation efforts.

Zoos and wildlife parks play an active role in conservation through establishing breeding programs and creating awareness for animal protection and welfare. The international studbook listed 207 (males.females.unknown: 105.100.2) GOH-rhinos in 73 institutions at the end of the year 2014. Currently, 24 European zoos are housing 65 individuals (31.34) and 79 animals (38.41) are living in 29 North American zoos and wildlife parks [von Houwald et al., 2014].

Conflict of interest: None.

*Correspondence to: Marcus Clauss, Clinic for Zoo Animals, Exotic Pets and Wildlife, Vetsuisse Faculty, University of Zurich, Winterthurerstr. 260, CH-8057 Zurich, Switzerland.
E-mail: mclauss@vetclinics.uzh.ch

Received 21 February 2016; Revised 25 May 2016; Accepted 06 June 2016

DOI: 10.1002/zoo.21307

Published online 20 June 2016 in Wiley Online Library (wileyonlinelibrary.com).

To maintain viable populations, it is important to know the health problems that potentially have to be faced when keeping GOH-rhinos to prevent as many medical conditions as possible.

The most frequently reported health issues in captive adult GOH-rhinos are gastrointestinal or pulmonary diseases, foot problems, or uterine leiomyoma [Montali et al., 1982; Göltenboth, 1995; von Houwald, 2001; Atkinson et al., 2004; Wyss et al., 2012; Hermes et al., 2014]. These two latter problems are suspected to be associated with, among other factors, obesity, and most of the animals with these problems were reported to be in a body condition at time of death that was scored as “good” by the respective pathologists, most likely indicating animals that were not emaciated but had various degrees of adipose tissue stores [Wyss et al., 2012]. While foot lesions are not triggered by obesity, obesity may exacerbate existing lesions and delay the healing process [von Houwald, 2001]. Obesity can also affect reproduction. In black rhinoceros (*Diceros bicornis*), nulliparous females were scored higher in body condition than parous females [Edwards et al., 2015]. Similarly, captive female African elephants with a higher body mass (BM) are more likely to be acyclic [Freeman et al., 2009; Morfeld and Brown, 2014]. Obesity is a common problem in zoo animal husbandry, due to the lack of exercise and over-supplementation of energy [e.g. Schwitzer and Kaumanns, 2001; Clauss and Hatt, 2006; Videan et al., 2007].

GOH-rhinos often receive a diet with a restricted amount of concentrates and an *ad libitum* amount of roughage [Clauss et al., 2005]. They are classified as mixed feeders from an ecological point of view, because they ingest, in addition to grasses that represent the majority of their natural diet, also some browse and wild fruit. However, this classification may erroneously lead to feeding regimes with increased amounts of concentrates or commercial fruit [Clauss and Hatt, 2006]. Even with a roughage-only diet, the daily energy intake may still be higher in individual cases than the estimated maintenance requirement [Clauss et al., 2005].

Monitoring the weight of an animal continuously over time is probably the best option to check for changes in nutritional status, but using body weight only may be difficult, because the average body weight for stages of growth, maintenance, or pregnancy, have yet to be defined, and because of inter-individual variation. Also, it evidently requires the availability of scales, which are considered a prerequisite for any new GOH-rhino facility [von Houwald, 2016, pers. comm.], but may not be available at all facilities currently keeping these animals.

Body condition scoring (BCS) systems are often-used tools in veterinary practice to specify the animal's nutritional status and to help the observer to achieve reproducible results. They are standardized systems, where certain body regions are visually assessed and the perceived amounts of subcutaneous fat and muscle are determined from the body contour. These systems are

being more and more propagated as management tools for various zoo-kept species [Bray and Edwards, 2001], and BCS systems have been published for the white rhinoceros (*Ceratotherium simum*) [Keep, 1971; Versteeg and van den Houten, 2011], the black rhinoceros [Reuter and Adcock, 1998], tapirs (*Tapirus spp.*) [Clauss et al., 2009], and repeatedly for elephants [Wemmer et al., 2006; Fernando et al., 2009; Morfeld et al., 2014]. To date, to our knowledge, no such score is available for GOH-rhinos.

Therefore, the aim of this study was to establish a standardized BCS system for GOH-rhinos. Data about feeding practice, husbandry conditions, and health and reproductive status of GOH-rhinos were collected. We expected that the BCS would be independent of absolute measures of body mass or shoulder height (SH), but that it would correlate with the ratio of these two measures as an objective proxy for body condition; additionally, we expected that the BCS should correlate with the amount of food offered. In particular, we wanted to test whether differences in reproductive status or reproductive diseases correlated with the BCS, indicating a negative effect of obesity as suggested in elephants [Freeman et al., 2009; Morfeld and Brown, 2014] or black rhinos [Edwards et al., 2015].

METHODS

Survey

A survey in conjunction with a detailed photo instruction was sent to all 54 GOH-rhino keeping facilities in Europe and the US. The survey contained questions about the animals (body mass, shoulder, and hindquarter height, including historical measurements that were available from different time points for the same individual in several facilities), feeding practice (composition and amount of diet, feeding frequency), enclosure (substrate, size, group composition), and the reproductive and veterinary history (foot or skin problems, reproductive problems). The photo instruction was sent with a description of how standardized pictures should be taken (Fig. 1).

For each animal in the collections, seven pictures from three different angles (one from each side, one directly from behind, and one from half behind of each side) were requested. Two pictures from each side were required, because in white and black rhinos, it had become evident that the neck must be evaluated in a head-up and -down position for a satisfactory evaluation [Keep, 1971; Reuter and Adcock, 1998]. Most pictures were received as digital images of varying resolution; for two animals, pictures were scanned and sent by mail. Additional information on individual animals was taken from the studbook (e.g., reproductive history, age), from Hermes et al. [2014], and from the survey results. Based on the veterinary information provided, animals were considered as having mid- or long-term foot problems (during the last 4 years) typical for GOH-rhinos if the information listed,




Fig. 1. The seven different views requested for each individual greater one-horned rhinoceros (*Rhinoceros unicornis*) for the evaluation of body condition.

for example, cracks, fissures, foot pad overgrowth [von Houwald, 2016]; animals reported to have, for example, “lameness around the knee” or “fractured metatarsal bone” or a condition that healed within a short time period were not considered as having “foot problems.” For those facilities that responded with amounts of different diet items offered per animal on a daily basis, a total dry offer of the winter feeding regime was estimated by adding dry diet ingredients (hay, pelleted feeds, grains, bread) to the sum of fresh diet items (fruits and vegetables); following Flores-Miyamoto et al. [2005], the latter were corrected for a moisture content of 85%.

Body Condition Score Development

Twenty-seven GOH-rhino keeping facilities (20 from Europe, 7 from the US) participated in the survey and sent the requested pictures and information. Photographs of a total of 62 animals (30.32) were evaluated. The pictures obtained from the zoos were then evaluated using the existing body condition scoring system for black and white rhinos. In order to understand the anatomical descriptions necessary for the BCS, a self-compiled nomenclature was defined, due to the lack of a generally accepted terminology for the skin folds and body regions of GOH-rhinos [Laurie et al., 1983; Dinerstein, 1991] (Fig. 2a). The key body features used in these scores were taken as points of reference, which were: neck, shoulder, ribs, spine, rump, abdomen, and the tail base [Keep, 1971; Reuter and Adcock, 1998] (Fig. 2b). During this initial assessment process it became obvious that not all body features used in the existing scores could be transferred to GOH-rhinos.

The different body regions used for assessment were all evaluated individually and compared to the existing body condition scores for white and black rhinos [Keep, 1971;

Reuter and Adcock, 1998]. The final description of the BCS is given in Table 1, with examples for the five general scores in Figure 3. Manipulation of photos included a cropping of the image to reduce background, an adjustment of brightness in some cases, and mirroring for didactic purposes (to have all animals in Fig. 3 in the same direction). Specific considerations for the individual body regions are described in the following paragraphs.

Neck

In white rhinos, the first visual sign of deteriorating condition is a groove along the dorsal part of the neck due to the reduction of the fat deposit over the funicular part of the nuchal ligament. In early stages it is best seen when the head is down, because when the head is up, the muscles contract and tend to obscure the groove [Keep, 1971]. The neck groove is visible in GOH-rhinos as well. Due to overlapping of the posterior cervical fold, there is no development of a prescapular groove (due to hollowing out of the muscles in front of the shoulder blade) like in black rhinos [Reuter and Adcock, 1998]. In GOH-rhinos, the general appearance of the neck is judged, whether it appears thick, round, well-muscled, flat, or narrow, as well as the presence of a neck groove, which becomes visible with early stages of condition loss.

Shoulder

In black rhinos the shoulder area shows a rounded appearance [Reuter and Adcock, 1998], which was found hard to assess in GOH-rhinos because of the skin folds and the lack of distinctive roundness. Contrary to the white and black rhinos, the anterior border of the scapula is not visible in GOH-rhinos due to the position of the posterior cervical fold [Keep, 1971; Reuter and Adcock, 1998]. When

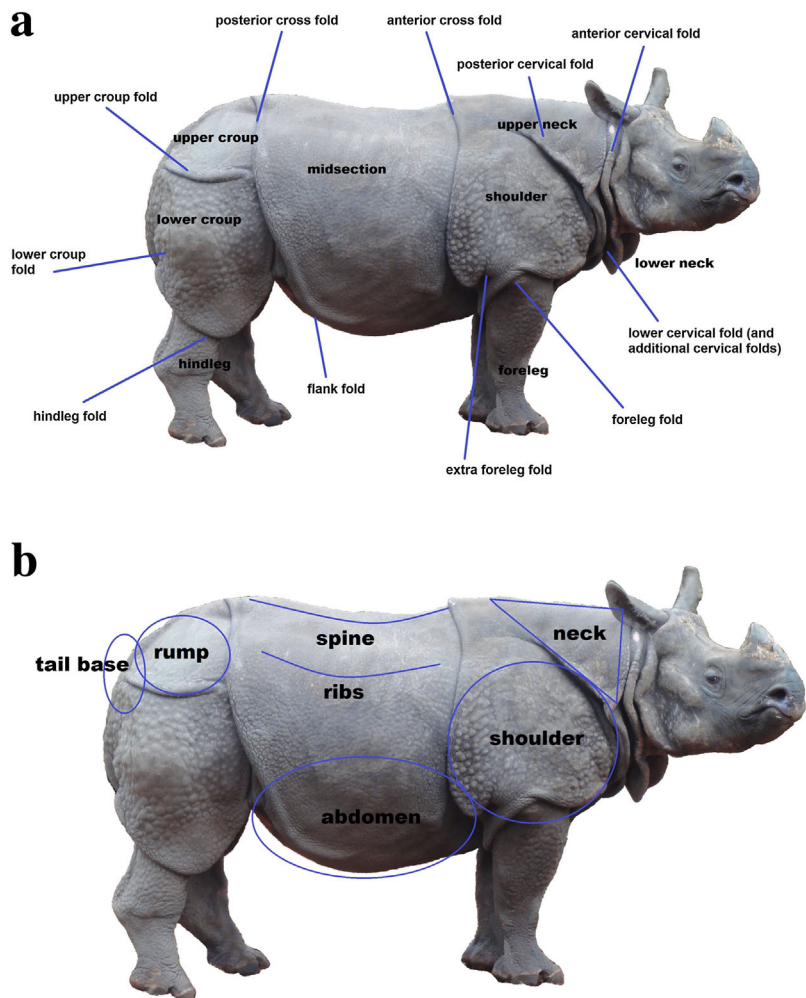


Fig. 2. a) The nomenclature for the skin folds and body regions for greater one-horned rhinoceros (*Rhinoceros unicornis*) used throughout this study. b) The body regions used to assess the body condition.

assessing GOH-rhinos, the general appearance, especially the part caudal of the scapula, is important. It is assessed, whether the shoulder region seems well muscled or hollowed out, and whether the spine of the scapula is visible completely, only in part, or not at all.

Ribs

The ribs of black and white rhinos in an obese to slight overweight condition are covered with thick skin folds [Keep, 1971; Reuter and Adcock, 1998]. This can lead to a “ribby” appearance and is not to be mistaken for a thin condition. GOH-rhinos also develop such skin folds, but they are not as distinctive as in the other species.

Spine

As condition decreases, a back groove becomes visible, which means the back hollows out on either side of the spine due to loss of subcutaneous fat and muscle wasting. This back groove becomes visible in white, black, and GOH-rhinos.

Rump

In black rhinos, the bony protuberances are used as main indicators for assessing the rump region [Reuter and Adcock, 1998]. In GOH-rhinos, the posterior cross fold and the upper croup fold make the assessment of this region difficult. The muscles that fill the rump region were used for indication. For best assessment, three different angles were used to evaluate this region: the rear view directly from behind and each side view from a 45° angle from behind.

Abdomen

In black rhinos there is the development of a skin fold of the flank, when condition is lost. However, in white rhinos, this flank fold is nearly always present [Keep, 1971], yet it may become more prominent if condition is lost. In GOH-rhinos, the posterior cross fold proceeds toward the abdomen, creating the flank fold, thus being always present. The prominence may vary; it is suggested that the filling status of the intestinal tract and the hydration

TABLE 1. Description of the characteristics of each assessment site for the body condition score in greater one-horned rhinoceros (*Rhinoceros unicornis*) developed in this study

Condition/ Assessment site	1 ("Very thin")	2 ("Thin")	3 ("Ideal")	4 ("Slight overweight")	5 ("Obese")
Neck	Neck very narrow, hollowing out of muscles very prominent	Hollowing out of neck muscles obvious, neck groove obvious	Neck groove visible, neck becomes flat, narrower, neck muscles start to hollow out	Musled, in the head down view a small neck groove can be visible	Thick, well-muscled, no neck groove visible neck bulges with muscles
Shoulder	Spine of scapula obvious, muscles hollowed out strongly	Spine of scapula obvious, muscles hollowed out	Spine of scapula slightly hollowed out	Musled, part of spine of scapula visible; small gradation caudal of scapula slightly visible	Well-muscled, scapula well covered, not visible
Ribs	Ribs very obvious	Ribs obvious	Ribs visible	"Ribby" appearance, but ribs are covered with skin folds	No ribs visible, all well covered
Spine	Back groove very obvious, from rear view very bony	Back groove obvious, from rear view bony	Small back groove visible, from rear view pointy	No back groove, musled, not bulging, from rear view slightly angular	Back rounded, muscles bulging; no back groove detectable, from rear view spine rounded and broad
Abdomen	Pulled up distinctively	Pulled up	Slightly pulled up, stomach line does not run below flank fold	Filled, small part of stomach below the flank fold visible	Distended, taut
Rump	Obvious depression	Concave	Slightly concave	Flattened	Region well filled with muscles and fat deposit, rounded
Tail base	Very thin and bony	Raised above the rump, bony	Slightly raised above the rump, narrow	Rounded, not bulging	Broad, well rounded, bulging

status influence the prominence of the flank fold [Reuter and Adcock, 1998]. For GOH-rhinos, we focused on the general appearance of the abdomen, whether it appeared distended or pulled in, and how much of the abdomen is seen below the flank fold.

Tail base

The amount of subcutaneous fat around the tail base also indicates the condition of GOH-rhinos. The tail base can be broad and round in an animal in obese condition to thin and bony in an animal in thin condition. This body region is best assessed with the tail not moving, resting in a physiological position, and from an angle directly from behind.

Body Condition Score Application

Each animal was given a score by the same observer (EMH). Two animals (1.1) were about 6 months old, five animals (2.3) were between 1 and 2 years old, three animals (3.0) were between 2 and 3 years old. No animal was between 3 and 4 years old. Fifty-two animals (24.28) were between 4 and 45 years old; 20 of these females were parous. Every body region was assessed and scored separately (1–5, 0.5 increments), and then the mean value of all regions was calculated. In doing so, all the regions were considered equally important; nonetheless, the more extensive body regions or the regions with larger muscles groups were easier to evaluate compared to the tail base, which only has subcutaneous fat as a reference point. It was allowed to have different scores for the different body regions in one animal.

Statistics

Data for the investigated animals were assessed, as indicated by normal distribution as assessed by the Kologorow–Smirnow test, using parametric or non-parametric tests for correlations (Pearson's R or Spearman's ρ , respectively) and for differences between subgroups (t -test or U -test, respectively). Subgroups were formed based on information from the studbook, survey, or the literature [Hermes et al., 2014]. These subgroups mostly contained only a fraction of all animals scored, and the respective sample sizes are mentioned in the results. Due to the generally limited sample size, no multiple regression was attempted. Analyses were performed in SPSS 21.0 (SPSS, Inc., Chicago, IL), setting the significance level to 0.05.

RESULTS

The patterns of age and size or body mass in the evaluated animals corresponded to that in the overall historical dataset that included multiple measurements in individual animals (Fig. 4). These data patterns justify the inclusion of animals from the age of approximately 4 years on in statistical




Fig. 3. Pictures of individual greater one-horned rhinoceroses (*Rhinoceros unicornis*) showing the different body conditions scores. BCS 2 taken in an animal prior to euthanasia for old age; the animal is otherwise represented in the dataset with a BCS of 3. Photos from the participating institutions, except BCS 1, which was kindly provided by Stanley Breeden.

evaluations; this corresponds to the onset of sexual maturity of females in captivity [von Houwald et al., 2014].

Considering animals from 4 years of age onwards, males were on average taller at the shoulder and heavier than females (Table 2). Applying the BCS developed for this study, in the animals from 4 years of age onwards, males and females did not differ significantly (Table 2, Fig. 5). However, when investigating the scores of the individual body regions separately, males had significantly higher scores for the neck, the shoulder, and the rump, whereas females had higher scores for the abdomen (Table 2). Of the 24 males and the 28 females, 14 and 20 animals, respectively (or 58 and 71 %), had a difference in the BCS of individual body regions of 1 or less. Six males and five females (or 25% and 18%), respectively, had a difference of 1.5, and four males and three females (or 17% and 11%) had a difference of 2.

In the animals from 4 years of age onwards, there was no correlation between age and BCS (Fig. 6A, $R = 0.03$, $P = 0.852$, $n = 52$), shoulder height and BCS (Fig. 6B, $R = 0.18$, $P = 0.232$, $n = 47$) or body mass and BCS (Fig. 6C, $R = 0.33$, $P = 0.078$, $n = 29$). However, there was a significant correlation between the BM:SH ratio and BCS (Fig. 6D, $R = 0.48$, $P = 0.013$, $n = 26$).

When classifying the females from 4 years onwards as parous ($n = 20$) or non-parous females ($n = 8$) according to

studbook information, no difference in BCS was evident (parous 4.1 ± 0.5 vs. non-parous females 3.9 ± 0.2 , $P = 0.171$). Analyzing the BCS for the individual body regions also did not result in any significant difference, except for the BCS of the abdomen; parous females had significantly ($P < 0.001$) higher abdomen scores (4.4 ± 0.5 , range 3.5–5.0) than non-parous females (3.4 ± 0.2 , range 3.0–4.0).

Our sample of females overlapped with that of Hermes et al. [2014] by 11 animals, of which eight were classified by those authors as having leiomyoma (aged 13–22 years at the time of evaluation and 15–28 years at the time of BCS scoring; note that leiomyoma evaluations spanned a period of about 10 years), and three were leiomyoma-free (aged 8–12 years at the time of evaluation and 9–24 years at the time of BCS scoring). In the responses to our survey, for six of the eight animals classified as having leiomyoma by Hermes et al. [2014] this diagnosis was also stated. In the three animals considered leiomyoma-free by Hermes et al. [2014], very detailed veterinary histories were provided that did not indicate reproductive problems up to the date of BCS scoring. The BCS of these two groups showed no overlap, being 4.5 ± 0.4 (range 3.9–4.9) in the leiomyoma animals versus 3.6 ± 0.1 (range 3.5–3.7) in the animals without leiomyoma (U -test $P = 0.012$).

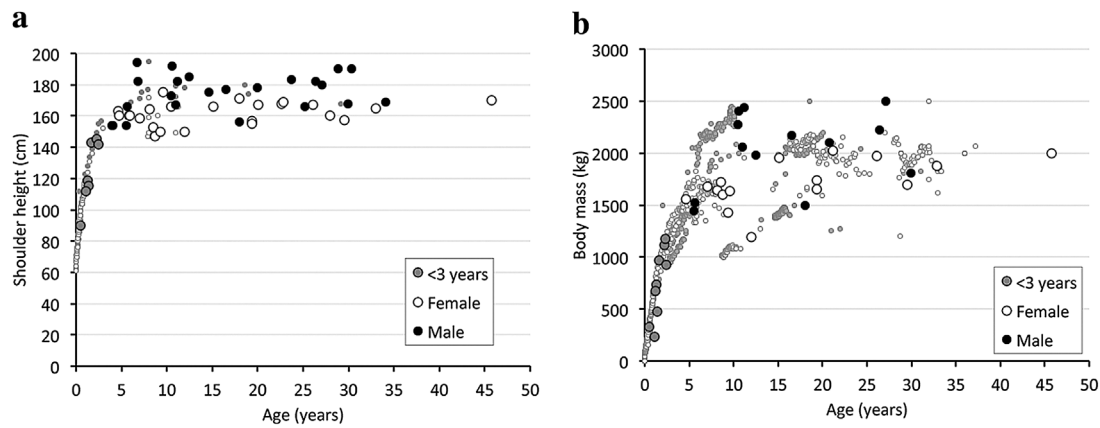


Fig. 4. Age, shoulder height, and body mass in the individual greater one-horned rhinoceroses (*Rhinoceros unicornis*) scored for body condition in this study. Background data for males (filled circles) and females (empty circles) from historical data from captive individuals (incl. multiple measures per individual).

Classifying animals from 4 years onwards as those with ($n = 18$) and without ($n = 34$) foot problems did not result in a difference in BCS (4.2 ± 0.4 vs. 4.1 ± 0.5 , $P = 0.604$). There were no significant correlations between the BCS and other enclosure measurements such as size of outdoor enclosure. Enclosure characteristics did not differ for animals without and with foot problems.

The facilities that responded to the survey offered a variety of roughages (mainly grass hay, but also straw and

lucerne hay), pelleted compound feed, and fruit and vegetables, with rare occasions of bread or grain feeding. Fruits and vegetables ranged from 0 to 25 kg as fed per animal and day. The estimated dry mass offered of all diet items combined (for 22 facilities with 43 animals older than 4 years) per animal and day ranged from 15 to 46 kg. There were negative correlations between the amount of roughage offered and the amount of pelleted feeds ($\rho = -0.51$, $P = 0.001$) or fruits and vegetables ($\rho = -0.34$, $P = 0.027$)

TABLE 2. Body mass, age, height measurements, and body condition scores in male and female greater one-horned rhinoceros (*Rhinoceros unicornis*) older than 3 years

	Males	Females	<i>P</i>
Body mass (kg)	2031 \pm 364 (1441–2500, $n = 13$)	1711 \pm 221 (1197–2026, $n = 16$)	0.012 (<i>t</i> -test)
Age (years)*	15.6 (4.0–34.0, $n = 24$)	18.7 (4.7–45.7, $n = 28$)	0.898 (<i>U</i> -test)
Shoulder height (cm)	175 \pm 13 (154–194, $n = 23$)	162 \pm 7 (147–175, $n = 24$)	<0.001 (<i>t</i> -test)
Hindquarter height (cm)	177 \pm 11 (157–198, $n = 23$)	164 \pm 6 (152–175, $n = 24$)	<0.001 (<i>t</i> -test)
Body mass:shoulder height ratio (kg/cm)	11.6 \pm 1.6 (9.2–13.9, $n = 12$)	10.5 \pm 1.1 (8.0–11.8, $n = 14$)	0.051 (<i>t</i> -test)
Body condition score (total)	4.3 \pm 0.4 (3.6–4.9, $n = 24$)	4.1 \pm 0.5 (3.0–4.9, $n = 28$)	0.181 (<i>t</i> -test)
BCS neck*	5.0 (3.5–5.0, $n = 24$)	4.0 (2.5–5.0, $n = 28$)	0.001 (<i>U</i> -test)
BCS shoulder*	5.0 (3.5–5.0, $n = 24$)	4.0 (3.0–5.0, $n = 28$)	0.001 (<i>U</i> -test)
BCS ribs*	4.0 (3.0–5.0, $n = 24$)	4.0 (3.0–5.0, $n = 28$)	0.159 (<i>U</i> -test)
BCS spine*	4.0 (3.0–5.0, $n = 24$)	4.0 (2.5–5.0, $n = 28$)	0.469 (<i>U</i> -test)
BCS abdomen*	4.0 (3.0–5.0, $n = 24$)	4.0 (3.0–5.0, $n = 28$)	0.042 (<i>U</i> -test) ^a
BCS rump*	4.5 (4.0–5.0, $n = 24$)	4.0 (3.0–5.0, $n = 28$)	0.001 (<i>U</i> -test)
BCS tailbase*	4.0 (3.5–5.0, $n = 24$)	4.0 (3.0–5.0, $n = 28$)	0.682 (<i>U</i> -test)

Data given as means \pm standard deviation (range) when normally distributed; difference assessed by *t*-test.

*Data not normally distributed, given as median (range); difference assessed by *U*-test.

^aHigher values in females.

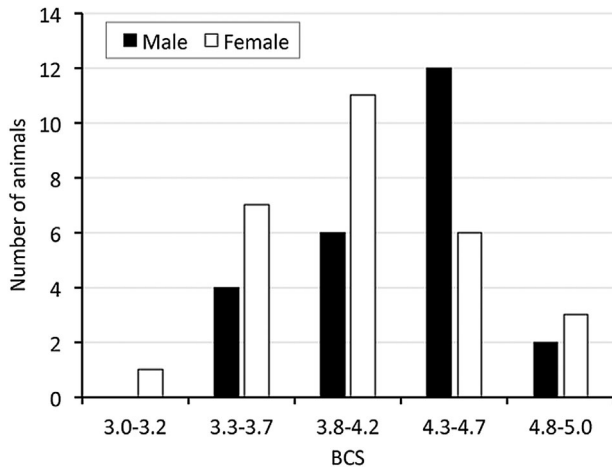


Fig. 5. Distribution of the individual male and female greater one-horned rhinoceroses (*Rhinoceros unicornis*) scored for body condition in this study.

in these diets. The total estimated dry amount of all diet items was significantly correlated to the overall BCS ($R = 0.38$, $P = 0.013$; Fig. 7). Neither the amount of roughages ($\rho = 0.10$, $P = 0.516$) nor the amount of pelleted feeds alone ($\rho = 0.12$, $P = 0.440$) were correlated to the BCS; for

fruits and vegetables, the correlation approached significance ($\rho = 0.28$, $P = 0.074$).

DISCUSSION

The present study provides a BCS for greater one-horned rhinos that was based on BCS for black and white rhinos [Keep, 1971; Reuter and Adcock, 1998; Versteeg and van den Houten, 2011] and comprises some species-specific modifications. It suggest that the captive population under study is comprised of animals ranging from ideal to obese body conditions, with no alarmingly thin animals, similar to a previous suggestion for this species [Clauss and Hatt, 2006]. As expected, the BCS did not correlate with age, shoulder height, or body mass, but showed a correlation with the BM:SH ratio. The relationship of body mass to a length or height measure, which is in itself unresponsive to the current nutritional status, is common practice when evaluating body condition [e.g., Stirrat, 2003; Barthelmess et al., 2006; Cabezas et al., 2006; Labocha et al., 2014]. Such a ratio is also used for humans to achieve a rough assessment of the body condition, the body mass index (BMI). It sets the body weight in relation to the height (kg/m^2) [e.g., Pietrobelli et al., 1998]. Evidently, recording the actual body mass and shoulder height on a regular basis

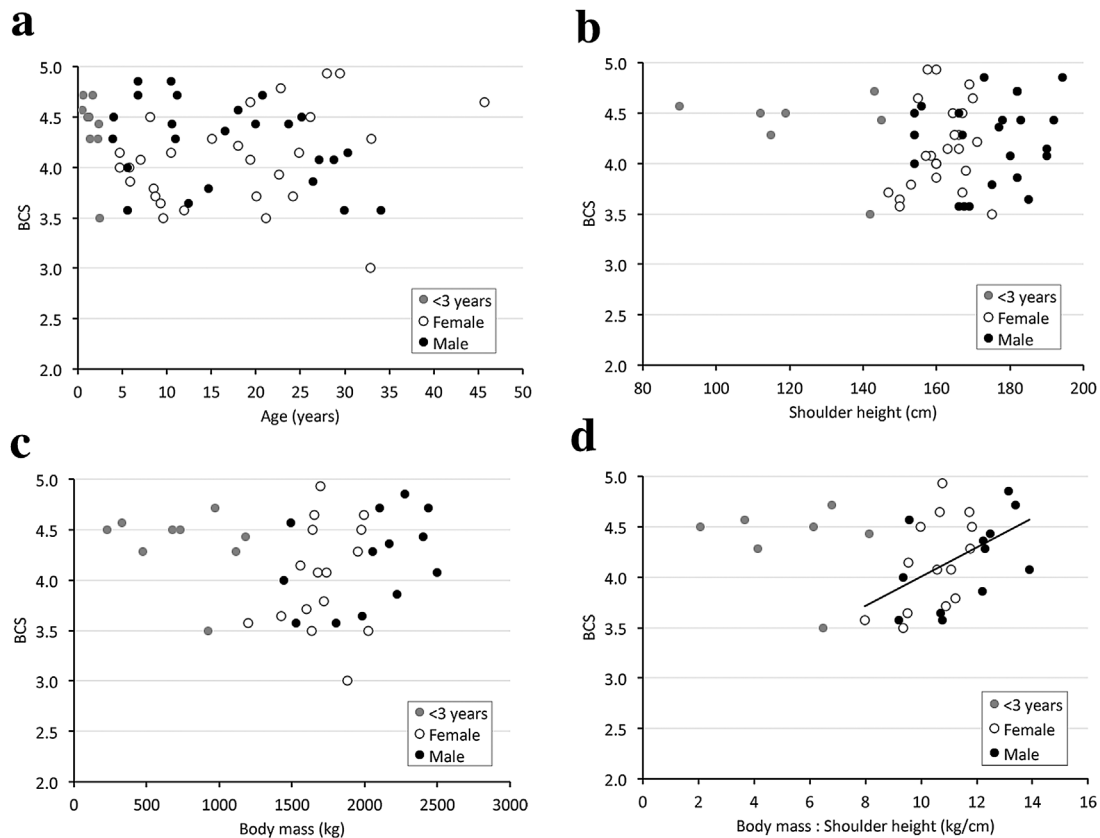


Fig. 6. Relationships in greater one-horned rhinoceroses (*Rhinoceros unicornis*) between body condition score (BCS) and a) age, b) shoulder height, c) body mass, and d) the body mass:shoulder height ratio.

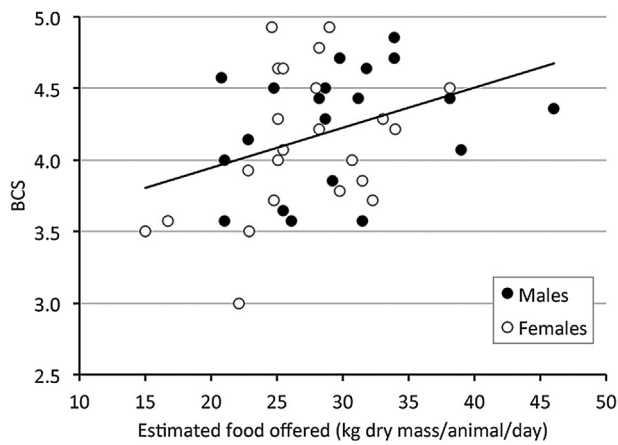


Fig. 7. Relationship between the daily amount of food offered per animal (estimated from the diet survey) and the body condition score (BCS) of the individual male and female greater one-horned rhinoceroses (*Rhinoceros unicornis*) of this study.

represents the most objective approach to condition monitoring; the widespread use of BCS is not due to a methodological superiority but to the imperative of the logistics involved.

Unfortunately, a validation by ultrasound was beyond the capacities of our study. This would have allowed a quantification of the subcutaneous fat layer [Domecq et al., 1995; Alapati et al., 2010; Morfeld et al., 2014], and possibly also allowed to differentiate between subcutaneous fat and muscle tissue, which could have helped explain differences in regional BCS scores observed between the sexes (Table 2). Such validation would be welcome in the future, as would be a routine comparison of BCS scored immediately prior to the death of an animal and body condition as assessed by necropsy [e.g., Lane et al., 2014]. Additionally, a survey of BCS of free-ranging GOH-rhinos would be valuable for comparison.

Male GOH-rhinos had significantly higher scores for the neck, the shoulder, and the rump (Table 2), presumably due to the natural sexual dimorphism. Males in the wild have massive neck and upper shoulder muscles; because they fight with their incisors, these muscles are needed to deliver the necessary strength and force for fighting. They also show enlarged skin folds around the neck (so-called “bibs”), which are used for display in interaction with rival males and serve as a guard for wounds inflicted by the incisors [Laurie et al., 1983; Dinerstein, 1991]. Measurements of the neck in wild breeding males are larger than in females, due to greater muscles mass and enlarged skin folds at this site [Dinerstein, 1991]. To our knowledge, a similar difference for the rump area has not been described, and given the lack of ultrasound examinations, we cannot decide whether this reflects more muscle or more subcutaneous fat in this area. On the other hand, females had higher scores than males for the abdomen, and parous females had significantly higher abdomen scores than non-parous females. This is probably due to gestation and the associated stretching of muscles, tissue, and skin.

These findings raise the question whether separate scores should be promoted for male and female GOH-rhinos. Given the overall similarity in BCS in males and females in Table 2, as well as the limited (though significant) magnitude of the difference in scores, we propose that using one general GOH-rhino-BCS represents the most practical option. The slightly elevated values in males could play a role in a general evaluation whether an animal should be considered overweight or of ideal condition, and a differential look at the individual body regions may be warranted in such a case. For monitoring body condition of individuals over time, including assessment of the effect of a change in husbandry or dietary management, such differences will not be relevant. In our view, following a formalized procedure, such as having a person do the scoring that does not have day-to-day contact with the animals (to avoid habituation to gradual changes), and first scoring the individual body regions and then calculating and assessing the average with sex-specific characteristics in mind, will probably increase the consistency and repeatability of the measurements.

Elevated BCS are suggested to be linked to reproductive problems in different species [Audige et al., 1998; Freeman et al., 2009; Morfeld and Brown, 2014; Edwards et al., 2015]; especially females should be kept in ideal condition to reduce reproductive problems. In the GOH-rhinos of this study, BCS did not differ significantly between parous and non-parous females. For this species, the occurrence of leiomyoma is of particular interest. Leiomyoma are benign tumors of the smooth muscle tissue and are rather rare in domestic animals, probably due to the frequent use of ovariohysterectomy in pet animals and the comparatively short lifespan of production animals. These benign tumors of the genital tract are a common finding in GOH-rhinos [Montali et al., 1982; Göltenboth, 1995; Wyss et al., 2012; Hermes et al., 2014], white rhinos [Radcliffe et al., 2000; Hermes et al., 2004, 2006; Wilson et al., 2010], or Sumatran rhinos [Schaffer et al., 1994, 2002]. Investigating 34 individual GOH-rhino females (42% of the captive population in 2011), Hermes et al. [2014] found that while none of the 11 animals up to 12 years of age had leiomyoma, all of the 23 animals older than 12 years did; one of the suggested risk factors is a lack of breeding activity in animals that have become sexually mature.

In humans, obesity is one among the many factors often mentioned to increase the risk for leiomyoma [Ross et al., 1986; Shikora et al., 1991; Sato et al., 1998; Faerstein et al., 2001; Wise et al., 2005; Takeda et al., 2008; Yang et al., 2014; Sommer et al., 2015]. Parous women appear to have a lower risk of uterine leiomyoma than nulliparous women [Ross et al., 1986; Parazzini et al., 1988, 1996; Wise et al., 2004]. One study showed that the incidence rate was only lower in parous women with a normal or low body mass index, which leads to the assumption that obesity may extenuate the positive effect of parity [Wise et al., 2004]. Given that in those 11 animals investigated by Hermes et al. [2014] that were also available for body condition scoring in the present study, a difference in BCS between animals with and without

leiomyoma was evident, it appears reasonable to suggest that maintaining GOH-rhinos at an intermediate BCS of 3–3.5 might be an additional prophylactic strategy to supplement other efforts to reduce the occurrence of leiomyoma in this species. However, the rationality of this approach notwithstanding, such a concept cannot be considered evidence-based from the results of our study, given its limitations. In particular, the difference in time points of diagnosing leiomyoma and/or parity and scoring BCS must be considered. According to the logic of the link between obesity and reproductive problems, it should be the BCS *before* the diagnosis of the problem that is the relevant correlate, but such BCS were not available for this study. Taking BCS scores in rhinos, elephants and other animals in which reproductive health is investigated should be considered as an additional important measure in future studies. While it appears desirable to breed young mature GOH-rhino females shortly after puberty, managing interbreeding intervals to resemble those in the wild (which are longer than in breeding captive females) is a valid option to prevent an overproduction of GOH-rhino calves without impairing the long-term reproductive success [Pluháček et al., 2016].

Chronic pododermatitis (CP) is a multifactorial disease, where suboptimal husbandry (especially inadequate flooring and a lack of pools) is probably the most influential etiologic factor, as this condition is not described in free-ranging animals and the incidence in the captive population is high; cracks, non-healing fissures, ulcers between the sole of the central toe and the adjacent pad, and pad overgrowth characterize this condition [von Houwald, 2001, 2016; Atkinson et al., 2004]. Obesity is considered a contributing factor once the disease is established, delaying the healing of the affected feet. At one facility with very intensive monitoring of foot health, an improvement and prophylactic effect with a change from hard substrate to a deep layer of woodchips in both the indoor and outdoor enclosure was observed [von Houwald, 2016], and a different questionnaire than the one used in the present study, filled in by eight zoological institutions, indicated fewer foot problems in those facilities that had instigated similar changes [von Houwald, 2016]. By contrast, in the present study, BCS and enclosure characteristics (such as the proportion of soft and hard substrate) did not differ for animals without and with mid- to long-term foot problems. The discrepancy between the two studies may be explained with the larger sample size in the present one, and in the questions used that did not ask for comments on changes in the problem with a change of substrate. A possible reason for the lack of a correlation is the chronic nature of CP, where adjustments in the enclosure, such as increasing the amount of soft substrates, have been made for animals that still have the problem. In order to document the status of CP in the captive GOH-rhino population, and potential correlates with husbandry measures, a more detailed study including standardized scoring of GOH-rhino feet, similar as in von Houwald [2001], would be required.

The BCS was significantly correlated to the total estimated dry amount of all diet items. For animals that ingest high proportions of roughage, it is impossible to estimate the energetic content of the diet without nutrient analyses, and therefore, a closer evaluation of the effect of individual roughages was outside of the scope of the present study. Clauss et al. [2005] found that even on roughage-only diets, some individuals had an energy intake well above their estimated metabolic requirements. The BCS could be used to adjust amounts fed or the ingredients chosen. If a reduction of the overall amount of food offered is not considered a good option because of behavioral considerations, then a roughage (grass hay or straw) of impeccable hygienic but lower nutritional quality should be chosen. It should be remembered that in the wild, GOH-rhinos mainly consume grasses [Laurie, 1982], and that observations on the consumption of wild fruit should be viewed with the actual quantity in mind [see Clauss and Hatt, 2006 for an example calculation]. Recently, Pradhan et al. [2008] did not report any fruit consumption in free-ranging GOH-rhinos, but showed that grass always represented the majority of the diet (from 53% in the cool dry season to 87% in the monsoon season), with browse representing the only relevant other diet component. Although the very recent nutrient analyses of diet items of free-ranging GOH-rhinos from Thakur et al. [2014] must be considered with caution (as nutrients add up to more than 100% dry matter), the high fiber levels indicate that such a low-quality diet is probably not mimicked by grass hay of a high nutritional quality. Commercial fruits and also most commercial vegetables typically contain much higher levels of sugar and lower levels of fiber than wild fruit [Schmidt et al., 2005; Schwitzer et al., 2009]. A diet based on grass hay (possibly mixed with straw) of a low nutritional quality, with a restricted small proportion of a pelleted compound feed (to ensure mainly mineral, but not energy provision), and a possible addition of browse, in the form of branches, is probably the best diet recommendation from both an enrichment and a health point of view [Clauss and Hatt, 2006]. Consultation of the feeding guidelines mentioned in the EAZA best practice guidelines [von Houwald, 2015] is strongly recommended.

CONCLUSIONS

1. We present a body condition scoring (BCS) system (from 1 to 5) for greater one-horned rhinoceros (GOH-rhinos) based on the evaluation of several body regions. The BCS was correlated, in animals above 4 years of age, with the ratio of body mass to shoulder height, supporting its use as a tool to estimate body condition.
2. In a survey with 62 animals from 27 facilities, the average BCS indicated that animals ranged from an ideal to an obese body condition.
3. While differences in the scores of individual body regions were evident between the sexes, the general BCS did not

differ between males and females, between animals with or without foot problems, or between parous and non-parous females. In a very limited sample of animals with and without leiomyoma, animals without leiomyoma had a lower BCS.

- There was a correlation between the BCS and the amount of food offered (as estimated from survey results). Adjusting both the amount and the nutritional quality of the feeds used for GOH-rhinos is an evident option to adjust their BCS.

ACKNOWLEDGMENTS

We thank all responding zoological facilities for their participation in the study, and two anonymous reviewers for markedly improving the manuscript with their comments.

REFERENCES

- Alapati A, Kapa SR, Jeepalyam S, Rangappa SM, Yemireddy KR. 2010. Development of the body condition score system in Murrah buffaloes: validation through ultrasonic assessment of body fat reserves. *J Vet Sci* 11:1–8.
- Atkinson MW, von Houwald F, Gairhe KP, Gandolf AR, Blumer ES. 2004. Veterinary observations of wild greater one-horned rhinoceros (*Rhinoceros unicornis*) in the Royal Chitwan national park: implications for captive management. Proceedings AAZV, AAWV, WDA Joint Conference 130–133 pp.
- Audige L, Wilson P, Morris R. 1998. A body condition score system and its use for farmed red deer hinds. *New Zeal J Agr Res* 41:545–553.
- Barthelme EL, Phillips ML, Schuckers ME. 2006. The value of bioelectrical impedance analysis vs. condition indices in predicting body fat stores in North American porcupines (*Erethizon dorsatum*). *Can J Zool* 84:1712–1720.
- Bray RE, Edwards MS. 2001. Application of existing domestic animal condition scoring systems for captive (zoo) animals. Proceedings of the Conference of the AZA Nutrition Advisory Group 4:25–28 pp.
- Cabezas S, Calvete C, Moreno S. 2006. Vaccination success and body condition in the European wild rabbit: applications for conservation strategies. *J Wildl Manag* 70:1125–1131.
- Clauss M, Polster C, Kienzle E, et al. 2005. Energy and mineral nutrition and water intake in the captive Indian rhinoceros (*Rhinoceros unicornis*). *Zoo Biol* 24:1–14.
- Clauss M, Hatt J-M. 2006. The feeding of rhinoceros in captivity. *Int Zoo Yearbook* 40:197–209.
- Clauss M, Wilkins T, Hartley A, Hatt J-M. 2009. Diet composition, food intake, body condition, and fecal consistency in captive tapirs (*Tapirus spp.*) in UK collections. *Zoo Biol* 28:279–291.
- Dinerstein E. 1991. Sexual dimorphism in the greater one-horned rhinoceros (*Rhinoceros unicornis*). *J Mammal* 72:450–457.
- Domecq JJ, Skidmore AL, Lloyd JW, Kaneene JB. 1995. Validation of body condition scores with ultrasound measurements of subcutaneous fat of dairy cows. *J Dairy Sci* 78:2308–2313.
- Edwards KL, Shultz S, Pilgrim M, Walker SL. 2015. Irregular ovarian activity, body condition and behavioural differences are associated with reproductive success in female eastern black rhinoceros (*Diceros bicornis michaeli*). *Gen Comp Endocrinol* 2014:186–194.
- Faerstein E, Szklo M, Rosenshein N. 2001. Risk factors for uterine leiomyoma: a practice-based case-control study. I. African-American heritage, reproductive history, body size, and smoking. *Am J Epidemiol* 153:1–10.
- Fernando P, Janaka HK, Ekanayaka SKK, Nishantha HG, Pastorini J. 2009. A simple method for assessing elephant body condition. *Gajah* 31:29–31.
- Flores-Miyamoto K, Clauss M, Ortmann S, Sainsbury AW. 2005. The nutrition of captive lowland anoa (*Bubalus depressicornis*): a study on ingesta passage, intake, digestibility, and a diet survey. *Zoo Biol* 24:125–134.
- Freeman EW, Guagnano G, Olson D, Keele M, Brown JL. 2009. Social factors influence ovarian acyclicity in captive African elephants (*Loxodonta africana*). *Zoo Biol* 28:1–15.
- Göltenboth R. 1995. Zuchtprobleme bei panzernashörnern. Tagungsbericht Arbeitstagung der Zootierärzte im deutschsprachigen Raum 5:24–27.
- Hermes R, Hildebrandt TB, Göritz F. 2004. Reproductive problems directly attributable to long-term captivity-asymmetric reproductive aging. *Anim Reprod Sci* 82:49–60.
- Hermes R, Hildebrandt TB, Walzer C, et al. 2006. The effect of long non-reproductive periods on the genital health in captive female white rhinoceroses (*Ceratotherium simum simum*, *C.s. cottoni*). *Theriogenology* 65:1492–1515.
- Hermes R, Goritz F, Saragusty J, Stoops MA, Hildebrandt TB. 2014. Reproductive tract tumours: the scourge of woman reproduction ails Indian rhinoceroses. *PLoS ONE* 9:1–10.
- Keep ME. 1971. Observable criteria for assessing the physical condition of the white rhinoceros *Ceratotherium simum* in the field. *Lammergeyer* 13:25–28.
- Labocha MK, Schutz H, Hayes JP. 2014. Which body condition index is best? *Oikos* 123:111–119.
- Lane EP, Clauss M, Kock ND, et al. 2014. Body condition and ruminal morphology responses of free-ranging impala (*Aepyceros melampus*) to changes in diet. *Eur J Wildl Res* 60:599–612.
- Laurie A. 1982. Behavioural ecology of the Greater one-horned rhinoceros (*Rhinoceros unicornis*). *J Zool (Lond)* 196:307–341.
- Laurie WA, Lang EM, Groves CP. 1983. *Rhinoceros unicornis*. *Mamm Species* 211:1–6.
- Montali RJ, Mann PC, Jones DM, et al. 1982. Leiomyomas in the genital tract of large zoo mammals. *Verhandlungsbericht Erkrankungen der Zootiere* 24:117–122.
- Morfeld KA, Brown JL. 2014. Ovarian acyclicity in zoo African elephants (*Loxodonta africana*) is associated with high body condition scores and elevated serum insulin and leptin. *Reprod Fertil Dev* 28:640–647.
- Morfeld KA, Lehnhardt J, Allia C, Bolling J, Brown JL. 2014. Development of a body condition scoring index for female African elephants validated by ultrasound measurements of subcutaneous fat. *PLoS ONE* 9:1–9.
- Parazzini F, La Vecchia C, Negri E, Cecchetti G, Fedele L. 1988. Epidemiologic characteristics of women with uterine fibroids: a case-control study. *Obstet Gynecol* 72:853–857.
- Parazzini F, Negri E, La Vecchia C, et al. 1996. Reproductive factors and risk of uterine fibroids. *Epidemiology* 7:440–442.
- Pietrobelli A, Faith M, Allison D, et al. 1998. Body mass index as a measurement of adiposity among children and adolescents: a validation study. *J Pediatr* 132:204–210.
- Pluháček J, Steck B, Sinha S, von Houwald F. 2016. Interbirth intervals are associated with age of the mother, but not with infant mortality in Indian rhinoceroses. *Curr Zool (in press)*, DOI 10.1093/cz/zow036
- Pradhan N, Wegge P, Moe S, Shrestha A. 2008. Feeding ecology of two endangered sympatric megaherbivores: Asian elephant *Elephas maximus* and greater one-horned rhinoceros *Rhinoceros unicornis* in lowland Nepal. *Wildlife Biol* 14:147–154.
- Radcliffe R, Hendrickson D, Richardson G, Zuba J, Radcliffe R. 2000. Standing laparoscopic-guided uterine biopsy in a southern white rhinoceros (*Ceratotherium simum simum*). *J Zoo Wildl Med* 31:201–207.
- Reuter HO, Adcock K. 1998. Standardised body condition scoring system for black rhinoceros (*Diceros bicornis*). *Pachyderm* 26:116–121.
- Ross R, Pike M, Vessey M, et al. 1986. Risk factors for uterine fibroids: reduced risk associated with oral contraceptives. *Br Med J (Clin Res Ed)* 293:359–362.
- Sato F, Nishi M, Kudo R, Miyake H. 1998. Body fat distribution and uterine leiomyomas. *J Epidemiol/Jpn Epidemiol Assoc* 8:176–180.
- Schaffer N, Zainal-Zahari Z, Suri M, Jainudeen M, Jeyendran R. 1994. Ultrasonography of the reproductive anatomy in the Sumatran rhinoceros (*Dicerorhinus sumatrensis*). *J Zoo Wildl Med* 25:337–348.
- Schaffer N, Agil M, Bosi E. 2002. Utero-ovarian pathological complex of the Sumatran rhinoceros (*Dicerorhinus sumatrensis*). Schwammer, HM et al. A research update on elephants and rhinos: Proceedings of the International Elephant and Rhino Research Symposium:1–352.
- Schmidt DA, Kerley MS, Porter JH, Dempsey JL. 2005. Structural and nonstructural carbohydrate, fat, and protein composition of commercially available, whole produce. *Zoo Biol* 24:359–373.
- Schwitzer C, Kaumanns W. 2001. Body weights of ruffed lemurs (*Varecia variegata*) in European zoos with reference to the problem of obesity. *Zoo Biol* 20:261–269.
- Schwitzer C, Polowinsky SY, Solman C. 2009. Fruits as foods – common misconceptions about frugivory. In: Clauss M, Fidgett AL, Hatt J-M,

- Huisman T, Hummel J, Janssen G, Nijboer J, Plowman A, editors. Zoo animal nutrition IV. Fürth: Filander Verlag. p 131–168.
- Shikora S, Niloff J, Bistran B, Forse R, Blackburn G. 1991. Relationship between obesity and uterine leiomyomata. *Nutrition* 7.
- Sommer E, Balkwill A, Reeves G, et al. 2015. Effects of obesity and hormone therapy on surgically-confirmed fibroids in postmenopausal women. *Eur J Epidemiol* 30:493–499.
- Stirrat SC. 2003. Body condition and blood chemistry of agile wallabies (*Macropus agilis*) in the wet-dry tropics. *Wildl Res* 30:59–67.
- Takeda T, Sakata M, Isobe A, et al. 2008. Relationship between metabolic syndrome and uterine leiomyomas: a case-control study. *Gynecol Obstet Invest* 66:14–17.
- Talukdar BK, Emslie R, Bist SS, et al. 2008. *Rhinoceros unicornis*. The IUCN Red List of Threatened Species 2008:e.T19496A8928657.
- Thakur S, Upreti C, Jha K. 2014. Nutrient analysis of grass species consumed by greater one-horned rhinoceros (*Rhinoceros unicornis*) in Chitwan national park, Nepal. *Int J Appl Sci Biotechnol* 2:402–408.
- van Strien NJ, Manullang B, Sectionov I, et al. 2008a. *Dicerorhinus sumatrensis*. The IUCN Red List of Threatened Species 2008.
- van Strien NJ, Steinmetz R, Manullang B, et al. 2008b. *Rhinoceros sondaicus*. The IUCN Red List of Threatened Species 2008.
- Versteeg L, van den Houten T. 2011. Body condition scoring of captive white rhinoceros (*Ceratotherium simum*). Proceedings of the International Elephant and Rhino Conservation and Research Symposium 1123–1137.
- Videan EN, Fritz J, Murphy J. 2007. Development of guidelines for assessing obesity in captive chimpanzees (*Pan troglodydes*). *Zoo Biol* 26:93–104.
- von Houwald F. 2001. Foot problems in Indian rhinoceroses (*Rhinoceros unicornis*) in zoological gardens: macroscopic and microscopic anatomy, pathology and evaluation of the causes. Dissertation, University of Zurich.
- von Houwald F, Pagan O, Rieches R. 2014. International studbook for the greater one-horned or Indian rhinoceros, *Rhinoceros unicornis*. Switzerland: Zoologischer Garten, Basel.
- von Houwald F. 2015. EAZA Best Practice Guidelines for the greater one-horned rhinoceros.
- von Houwald F. 2016. Causes and prevention of foot problems in greater one-horned rhinoceros *Rhinoceros unicornis* in zoological institutions. *Int Zoo Yb* 50 (in press), DOI: 10.1111/izy.12116
- Wemmer C, Krishnamurthy V, Shrestha S, et al. 2006. Assessment of body condition in Asian elephants (*Elephas maximus*). *Zoo Biol* 25: 187–200.
- Wilson M, Hermes R, Bainbridge J, Bassett H. 2010. A case of metastatic uterine adenocarcinoma in a southern white rhinoceros (*Ceratotherium simum simum*). *J Zoo Wildl Med* 41:111–114.
- Wise L, Palmer J, Harlow B, et al. 2004. Reproductive factors, hormonal contraception, and risk of uterine leiomyomata in African-American women: a prospective study. *Am J Epidemiol* 159:113–123.
- Wise LA, Palmer JR, Spiegelman D, et al. 2005. Influence of body size and body fat distribution on risk of uterine leiomyomata in US black women. *Epidemiology* 16:346–354.
- Wyss F, Wenker C, Robert N, Clauss M, Houwald FV. 2012. Why do greater one-horned rhinoceros (*Rhinoceros unicornis*) die?—An evaluation of necropsy reports. Proceedings of the International Conference on Diseases of Zoo and Wild Animals 4:54–61.
- Yang Y, He Y, Zeng Q, Li S. 2014. Association of body size and body fat distribution with uterine fibroids among Chinese women. *J Womens Health (Larchmt)* 23:619–626.