

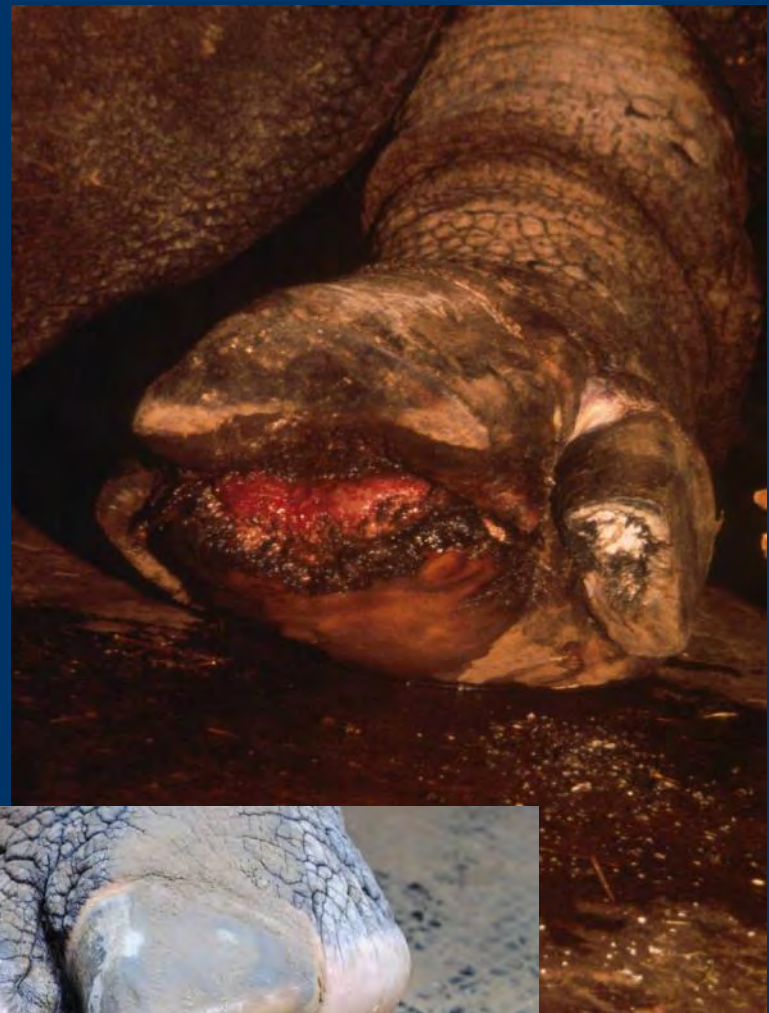Foot problems in Indian Rhinos

A problem solved?

Friederike von Houwald
Zoo Basel

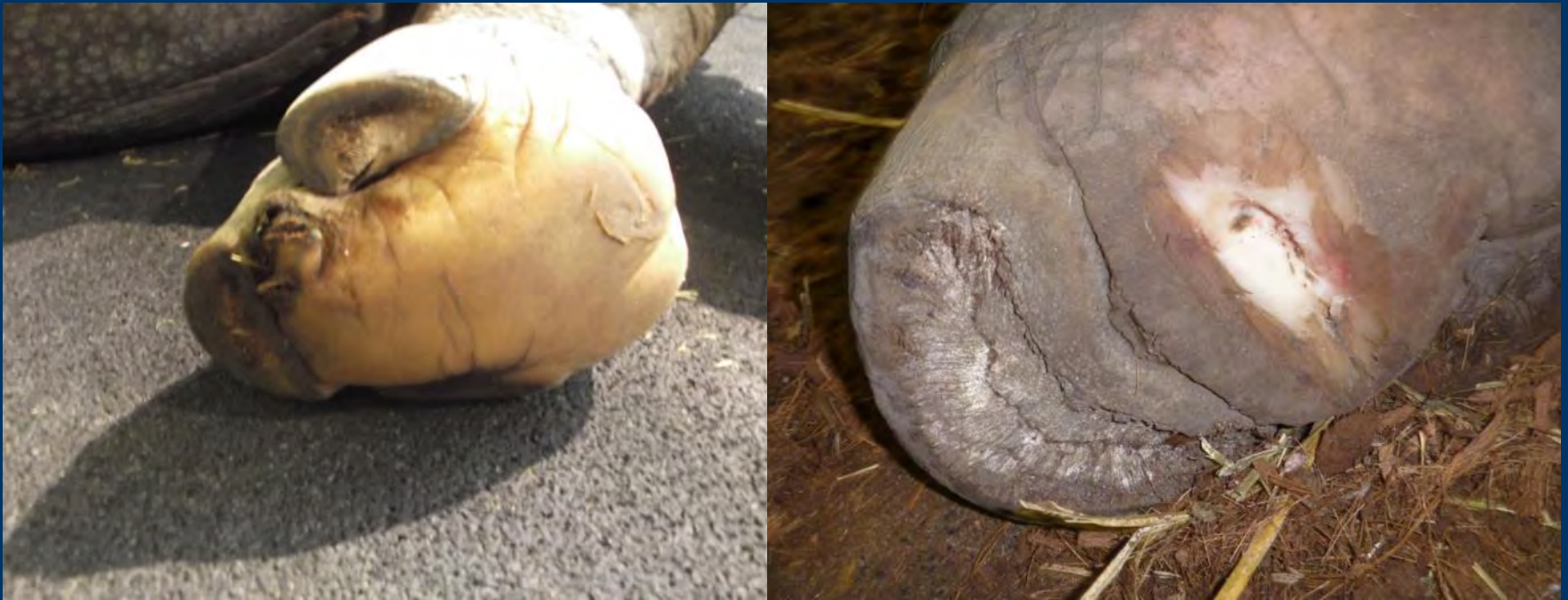History / Pathology

- Chronic Foot Disease



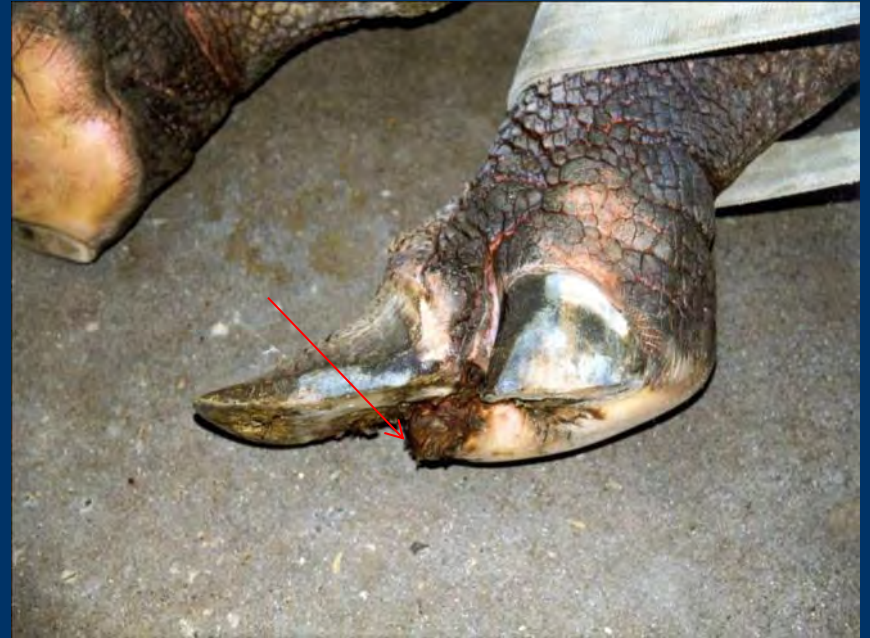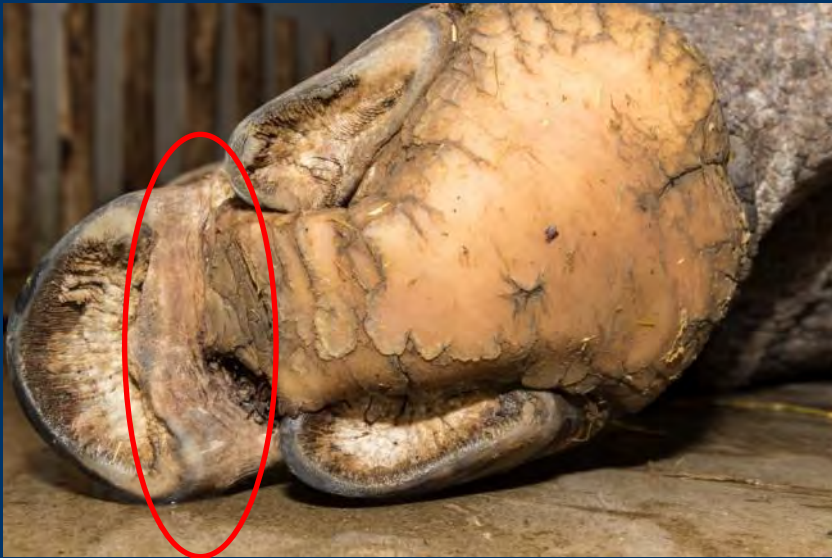History / Pathology

- CFD



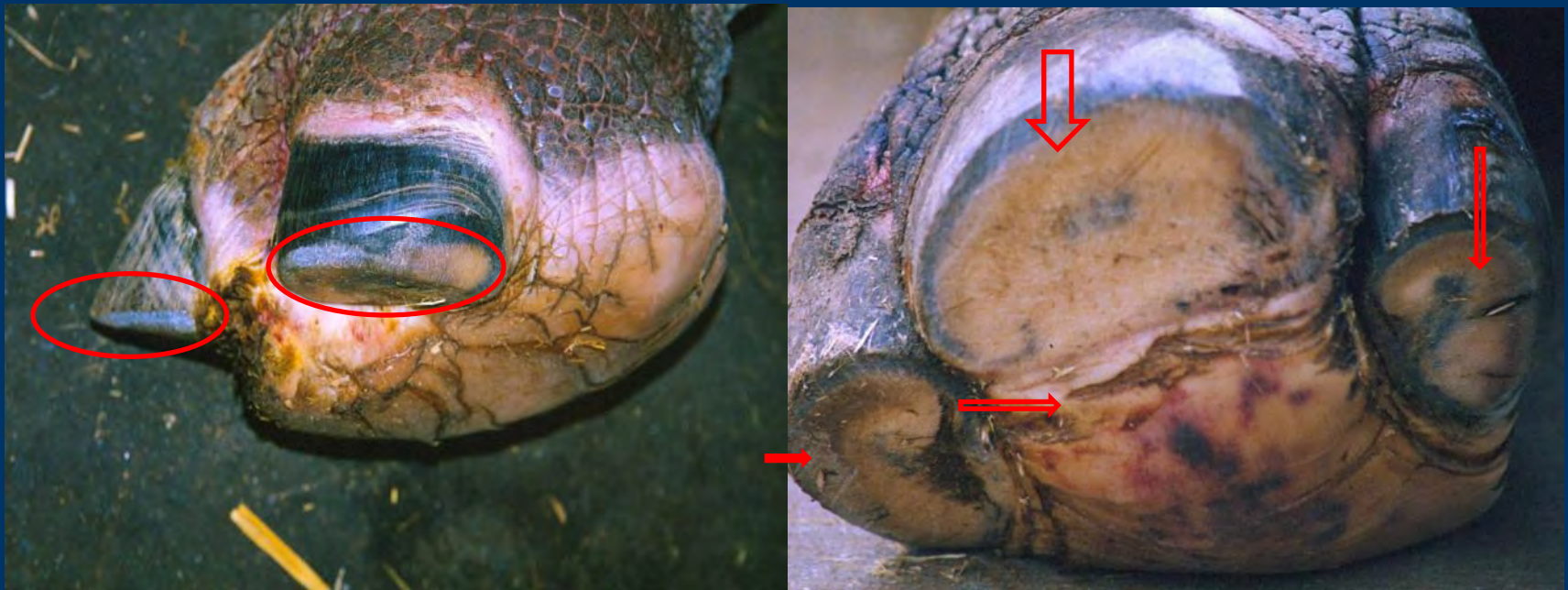
History/ pathology

- Elongated hooves



History / Pathology

- Abraded hoof walls



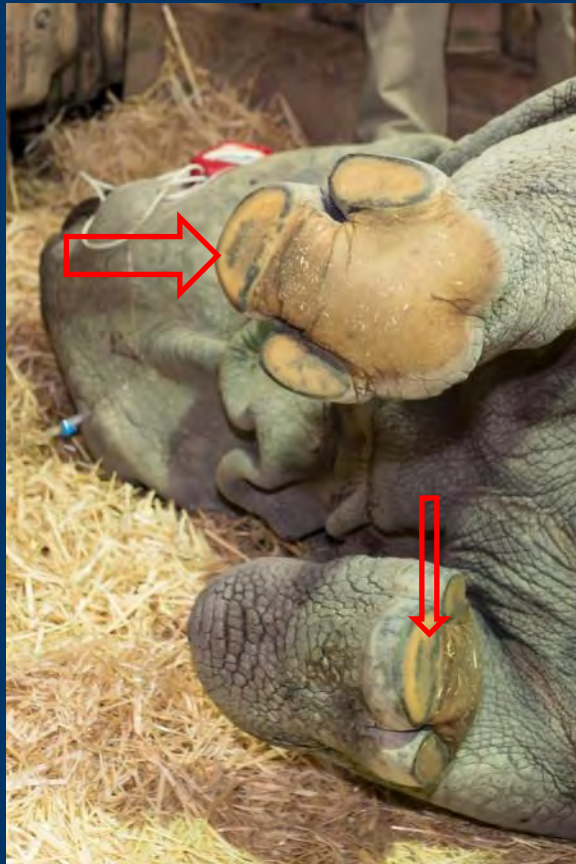
History / Pathology

- Thin pads



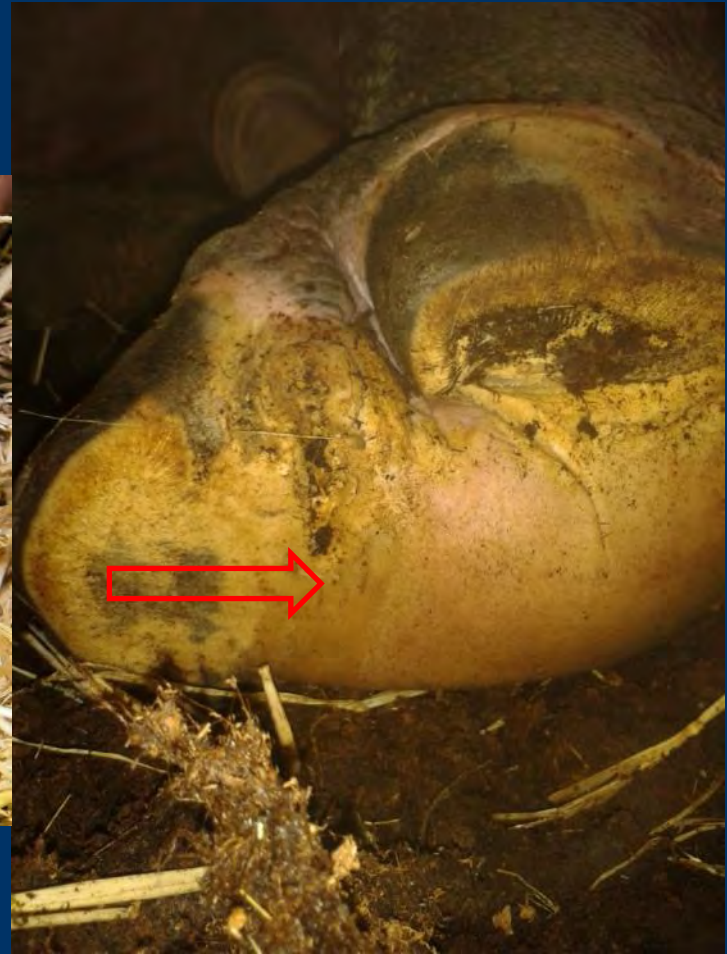History / Patholgy

- Thin pads / soles



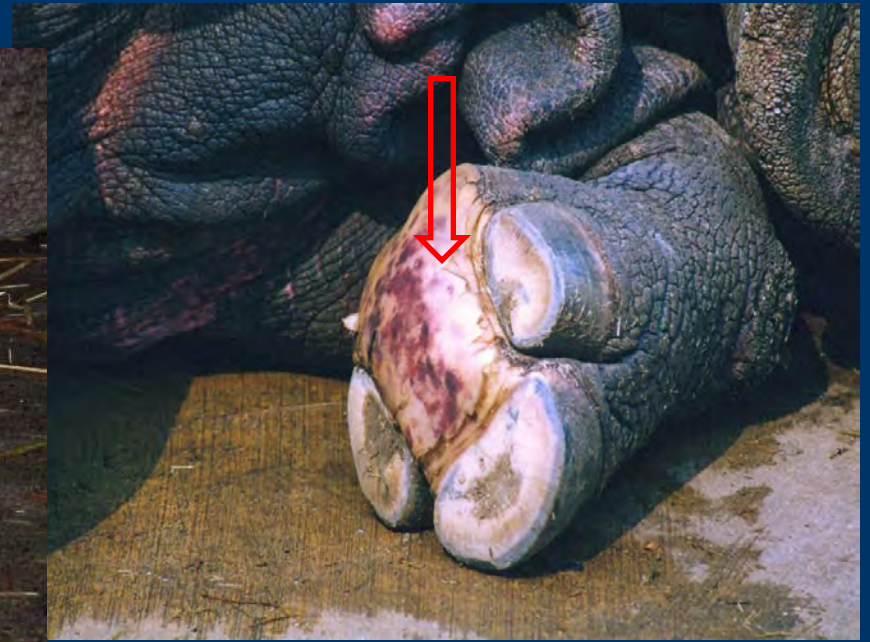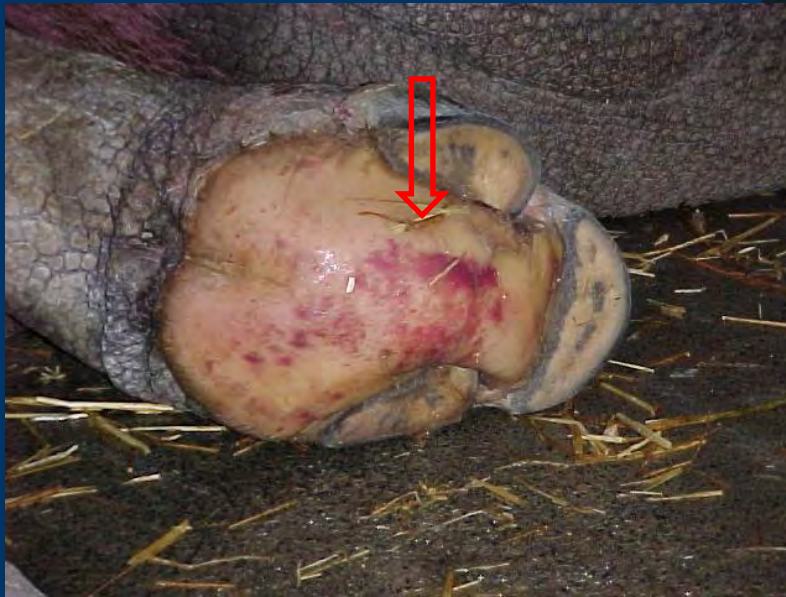History / Patholgy

- Thin horn of the pad



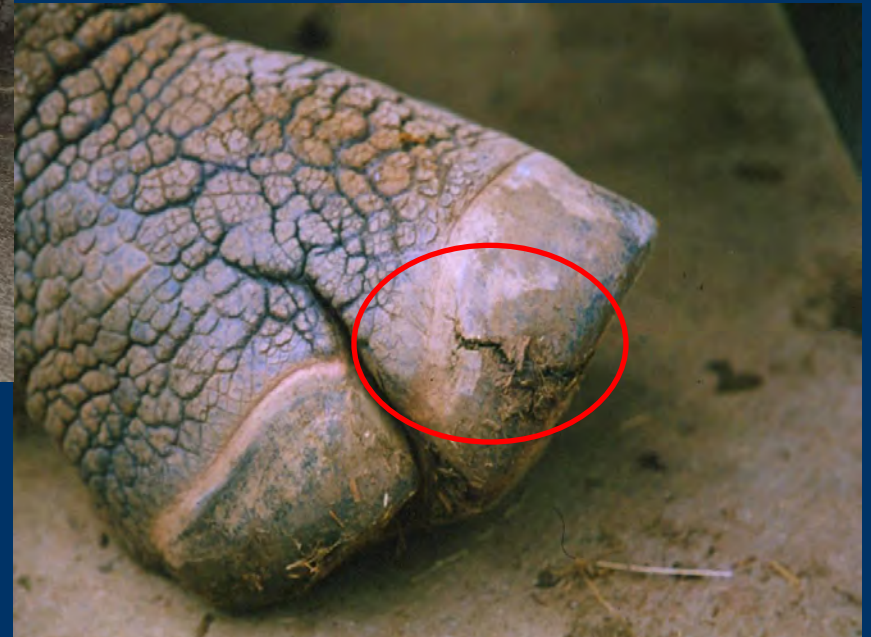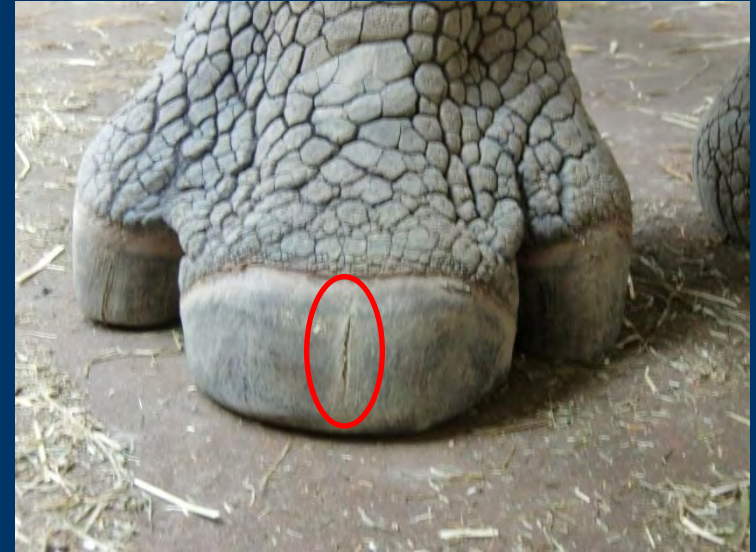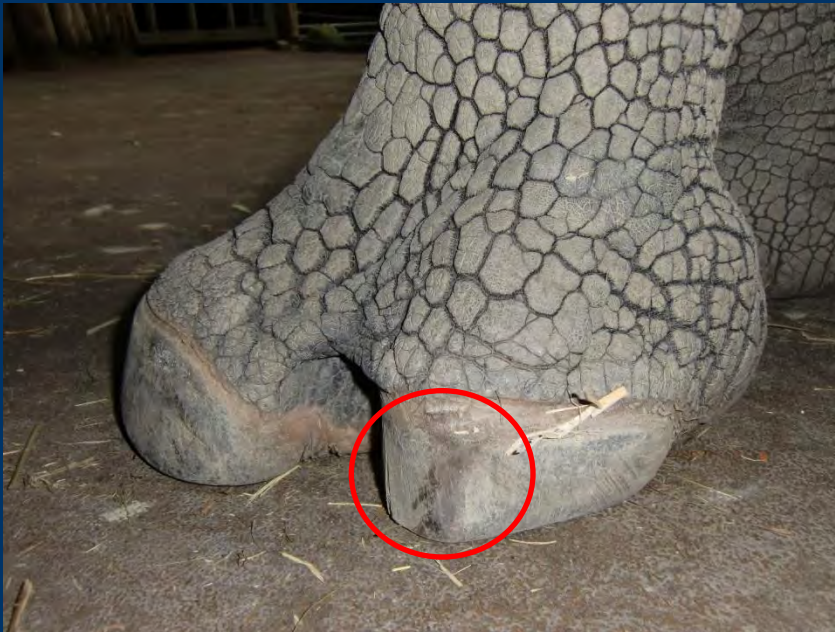History / Pathology

- haematoma



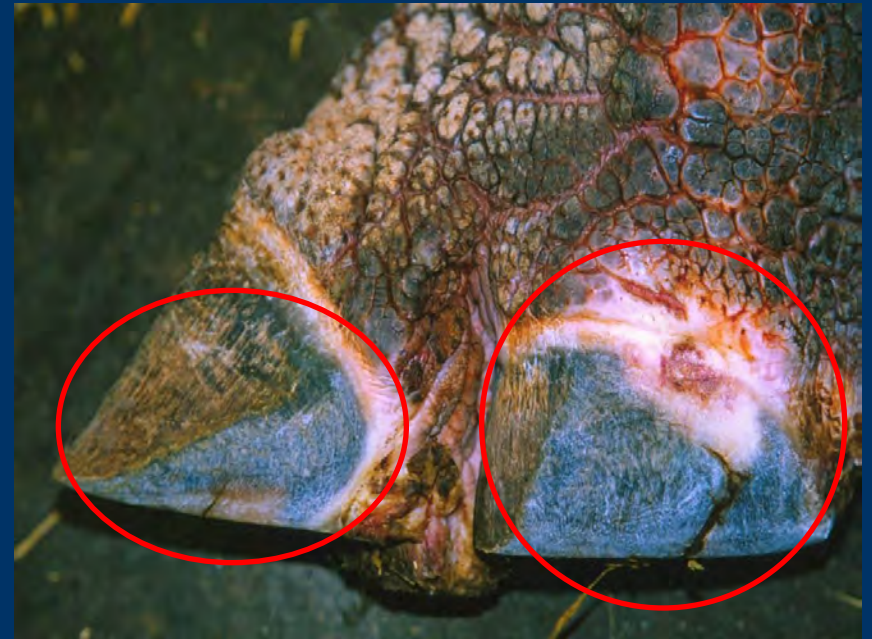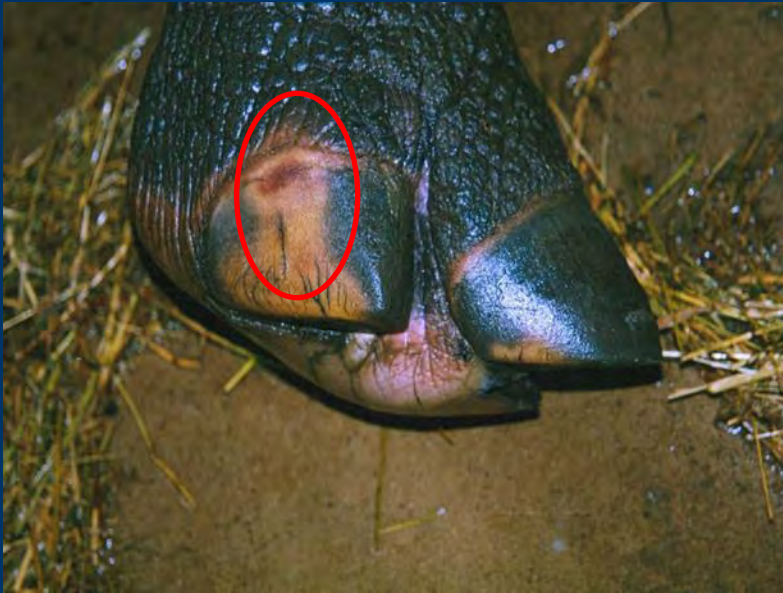History / Pathology

- Cracks in the hoof wall



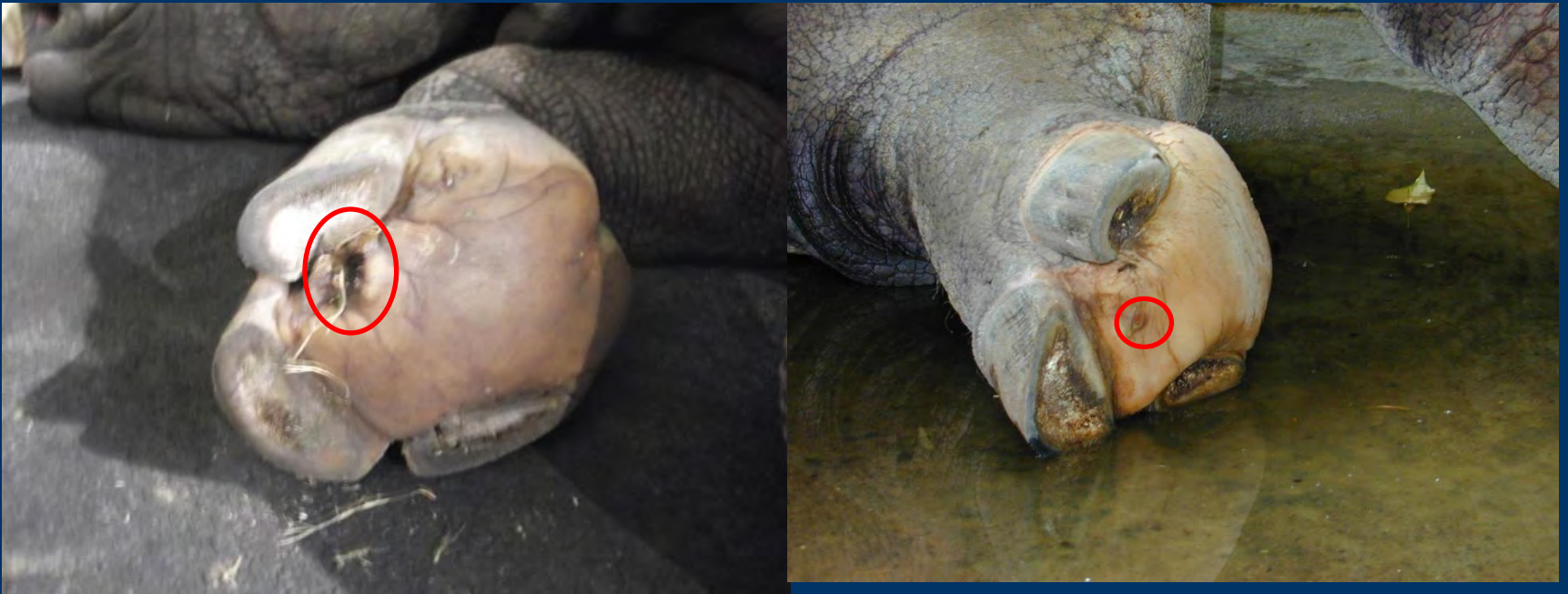History / Pathology

- Abraded side hoof walls

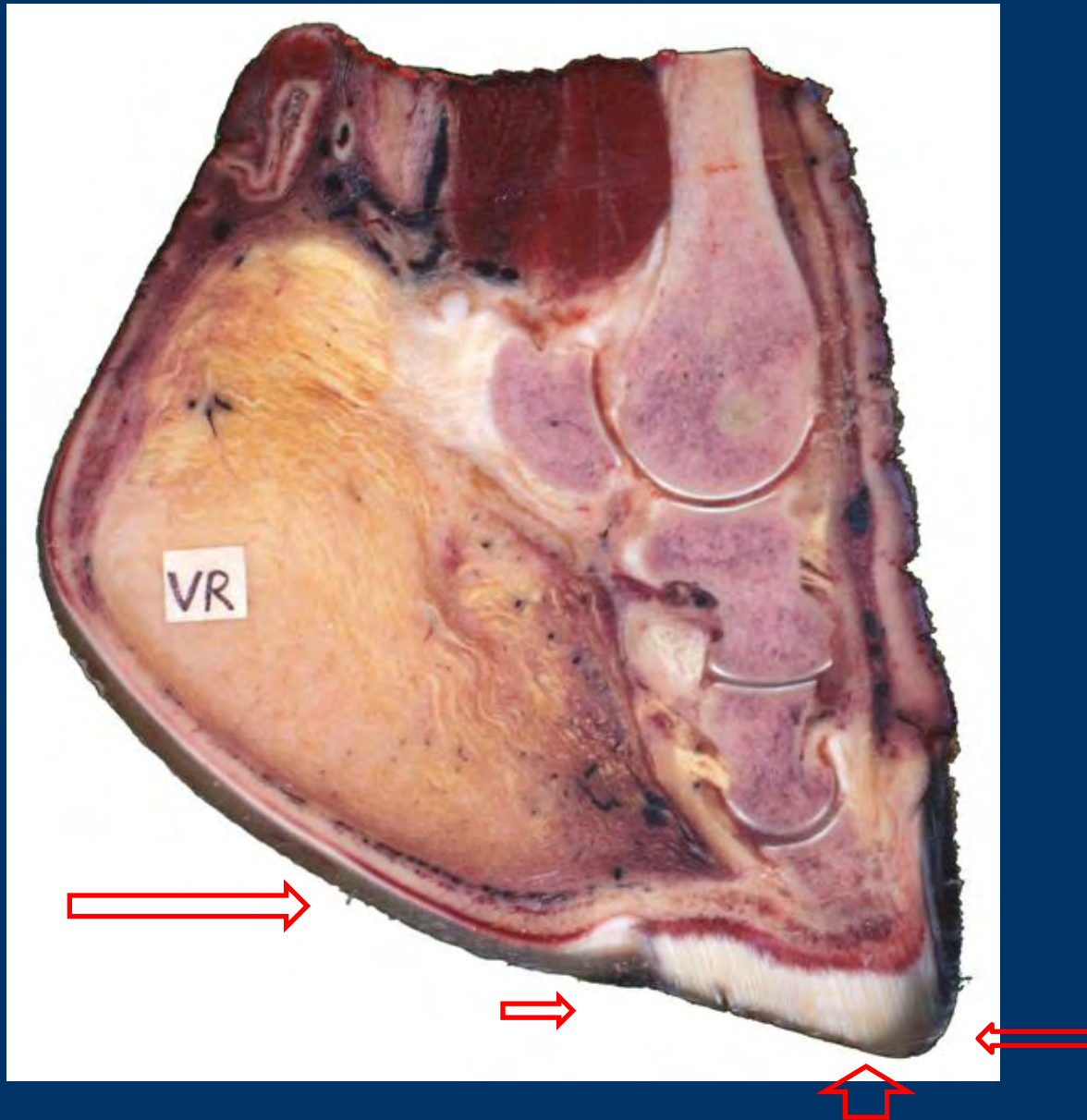


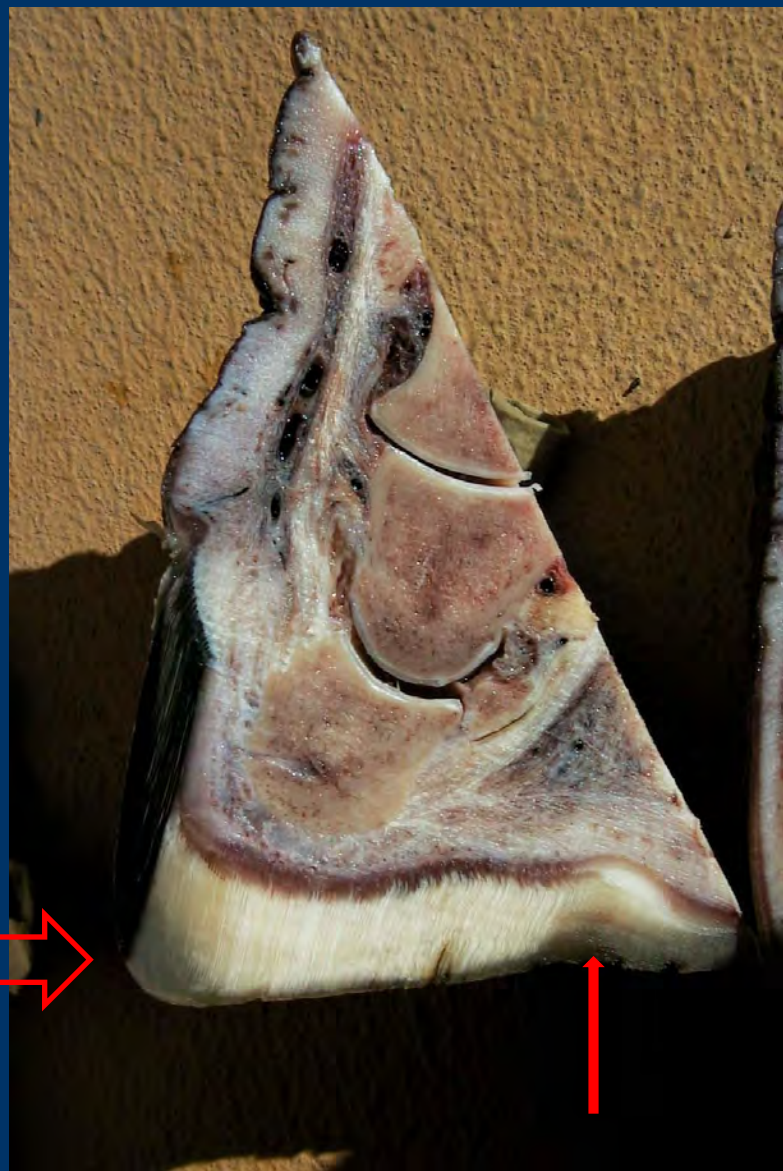
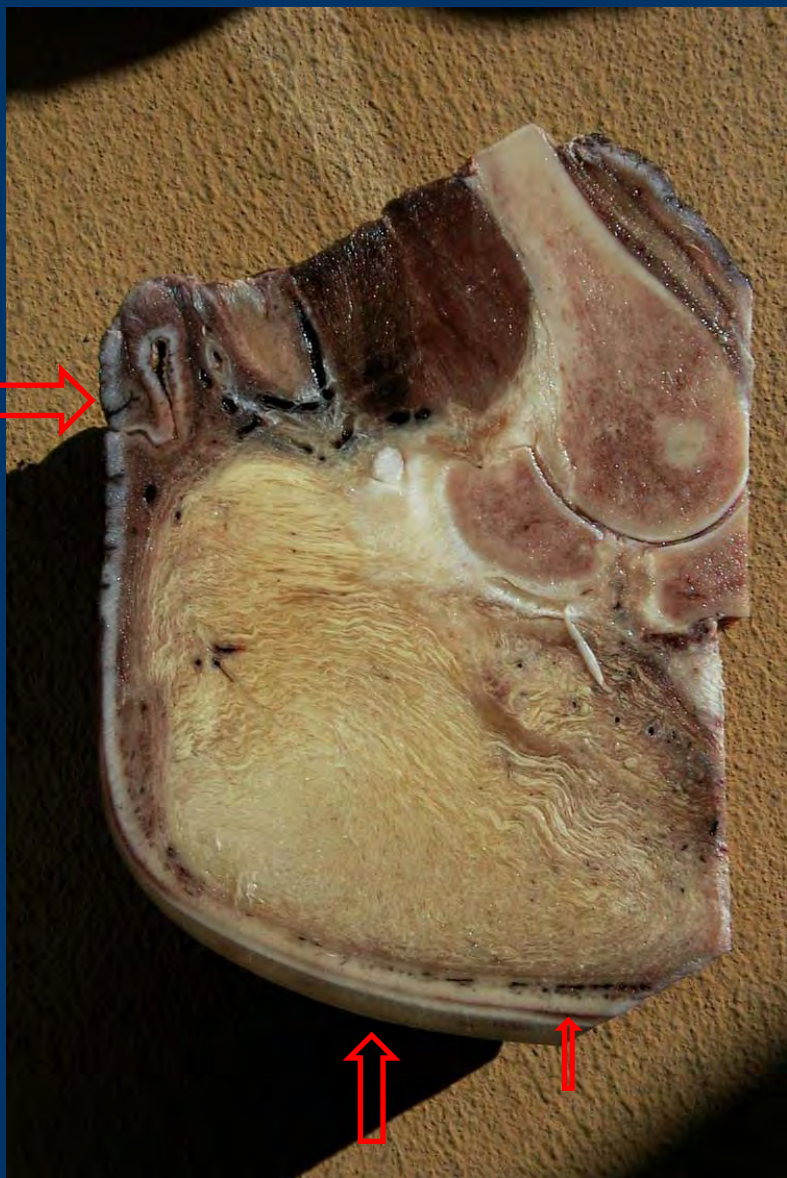
History / Pathology

- Lesions



Cut through a front foot






This is what we should see...



Feet of wild GOH

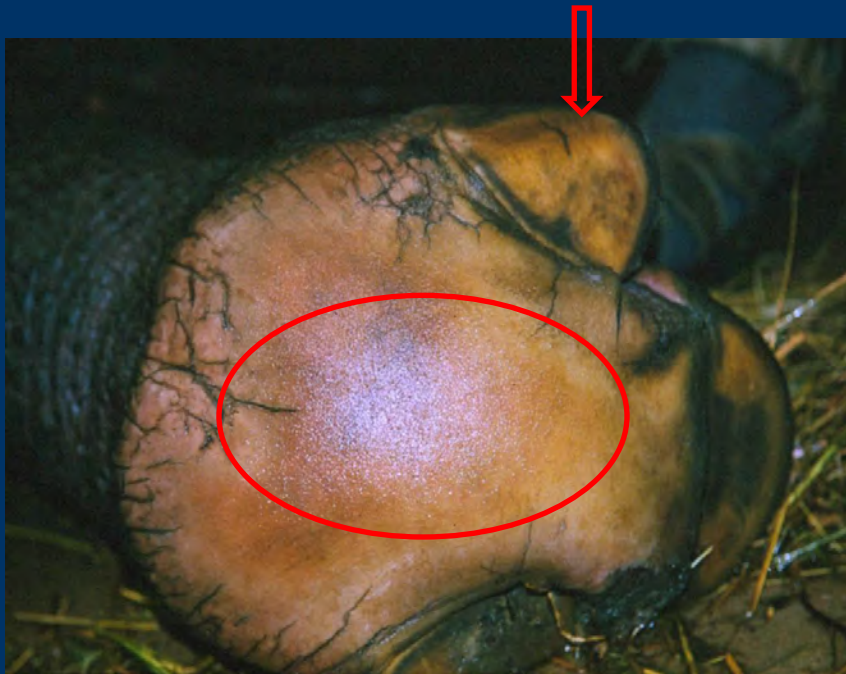hind feet

front foot

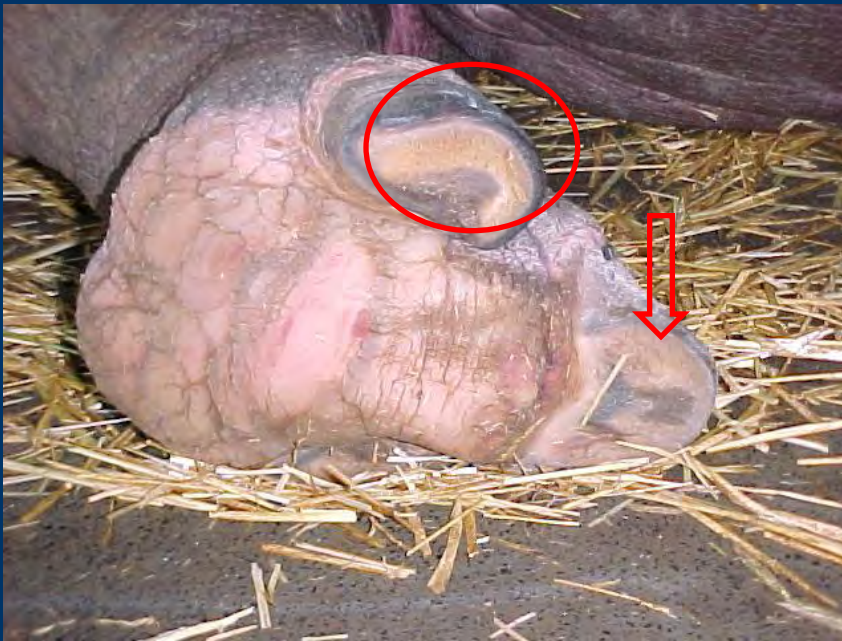

At Zoo Basel we also had CFD. In 2006 we renovated our inside and outside exhibits. After nearly 10 years we can clearly say it works...

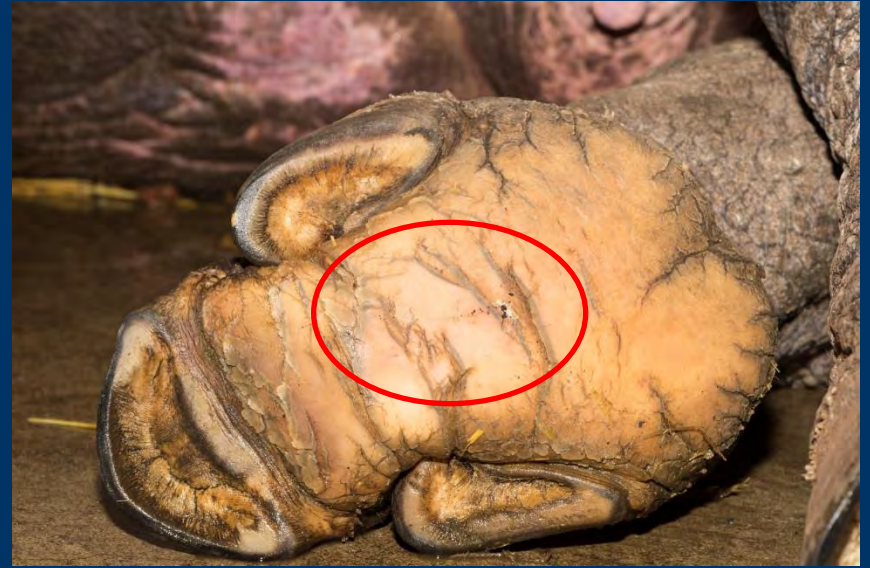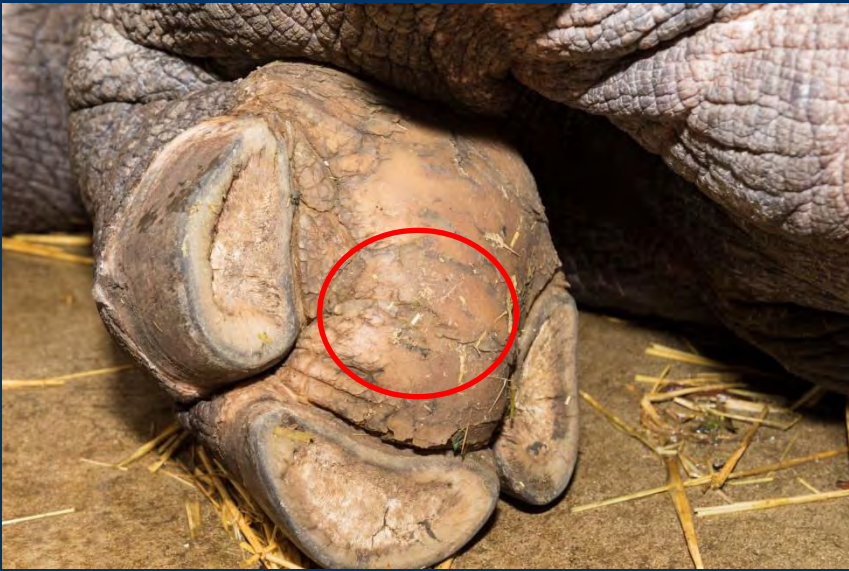Before and after cases (front feet, female)



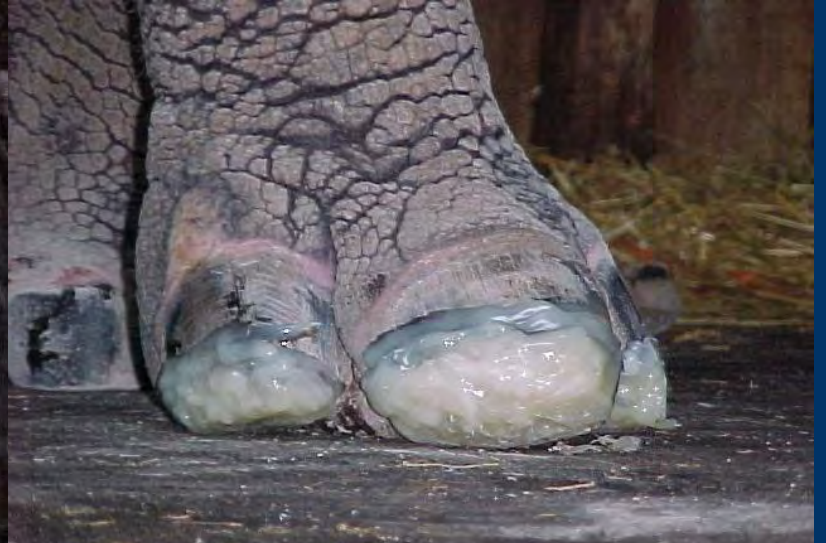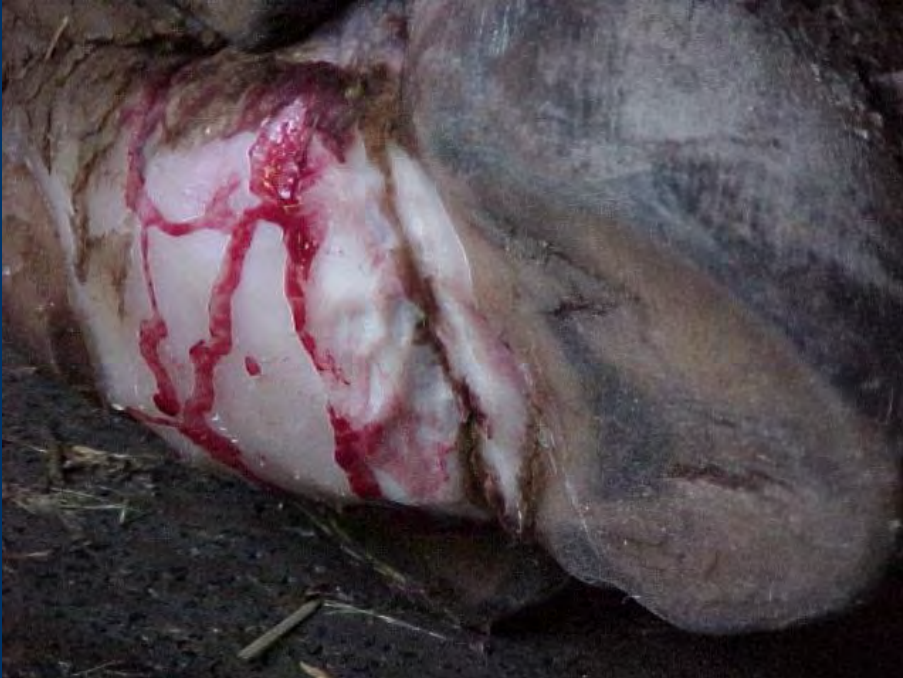Hind feet female



Front and hind foot of an old female



We were also treating the symptoms...



Other solutions

- Custom made leather shoes
- Trimming of central hoof
- Applying wooden blocks
-

Prevention



Outdoor exhibits



outdoor



indoor

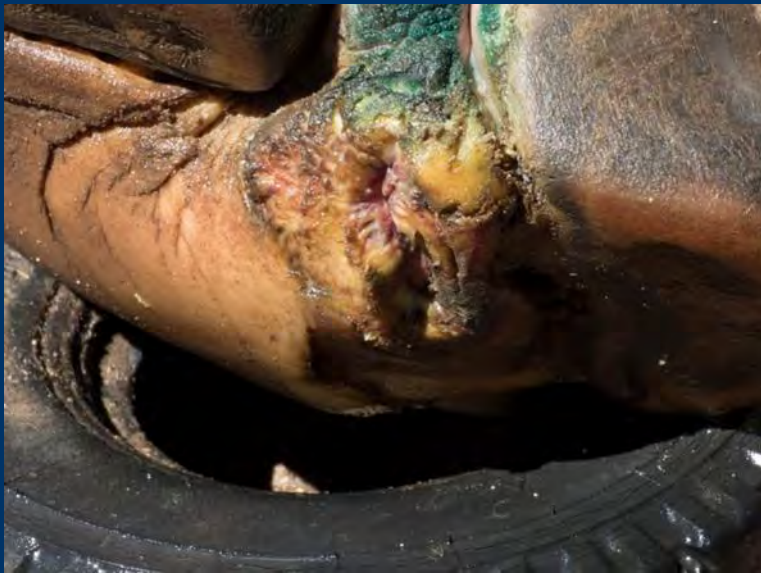



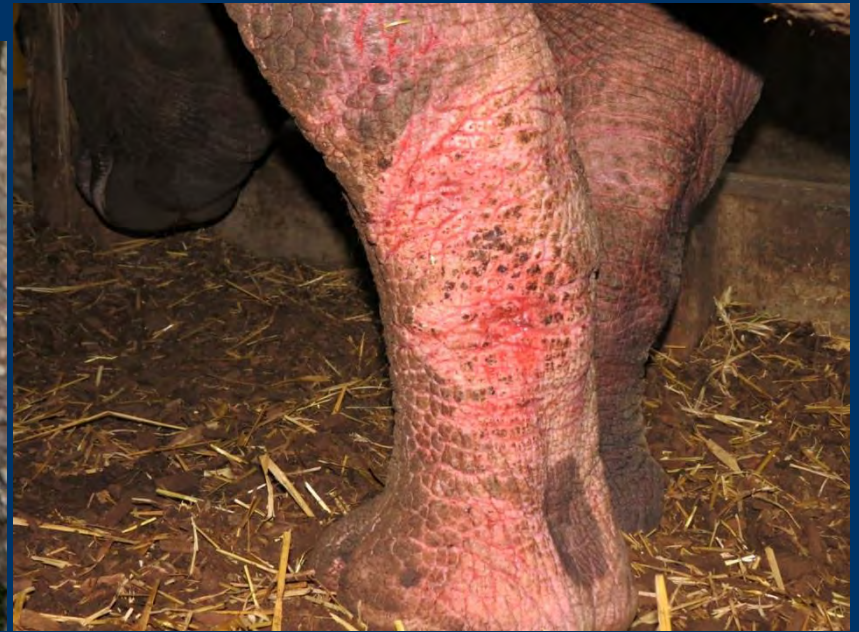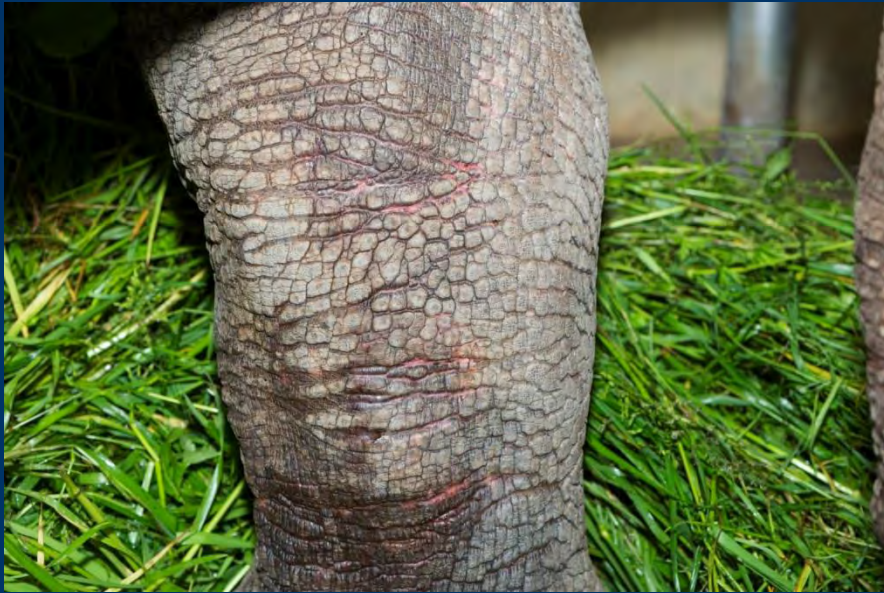Bad and good experience



Bad



Bad: Pine wood



Good: Wood chip - oak



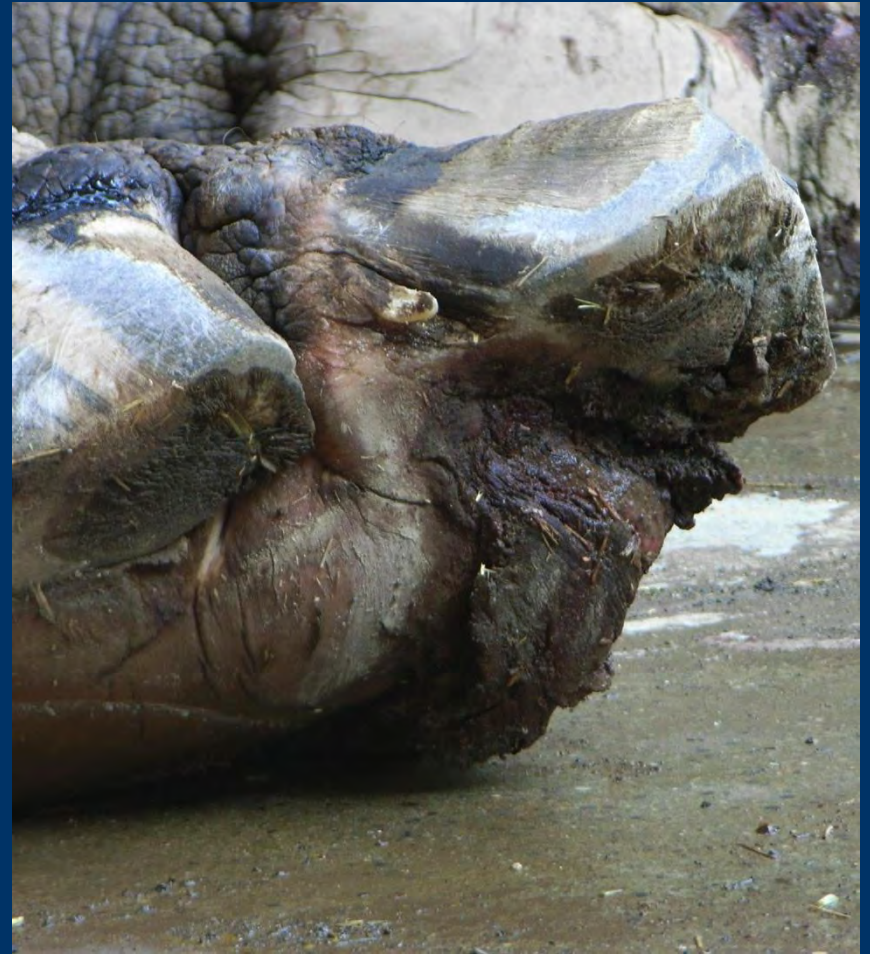
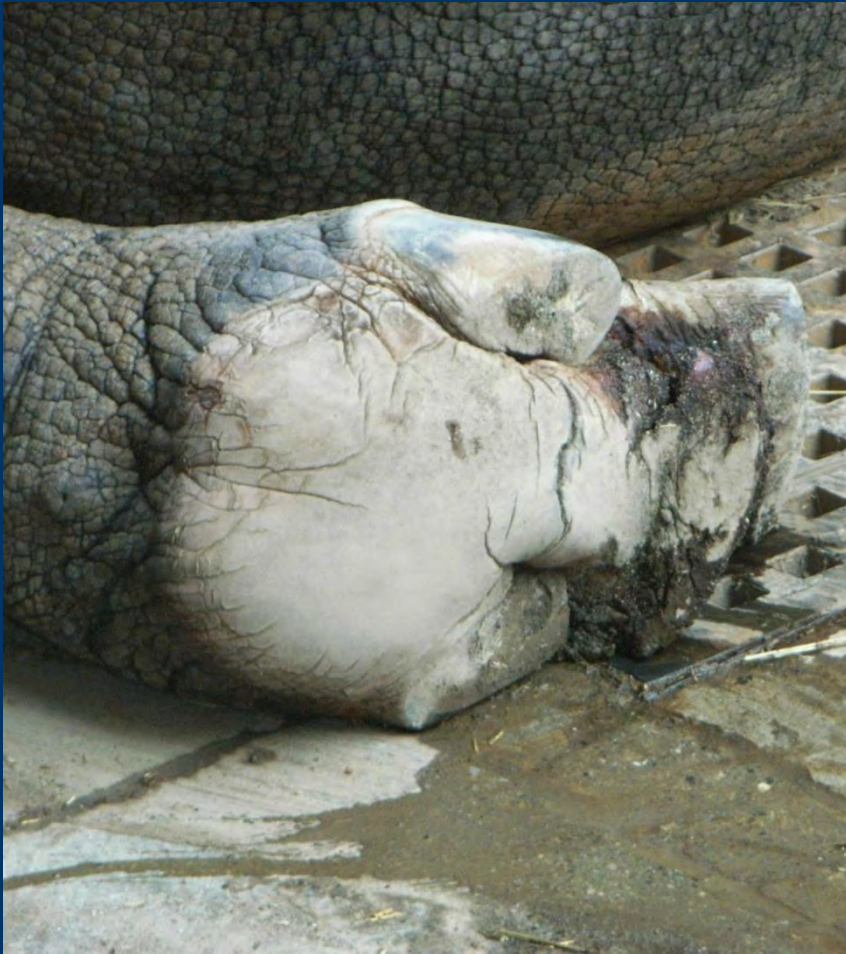Good - cocos



The Japanese experience, a really interesting story



Male rhino Kintaro 2010



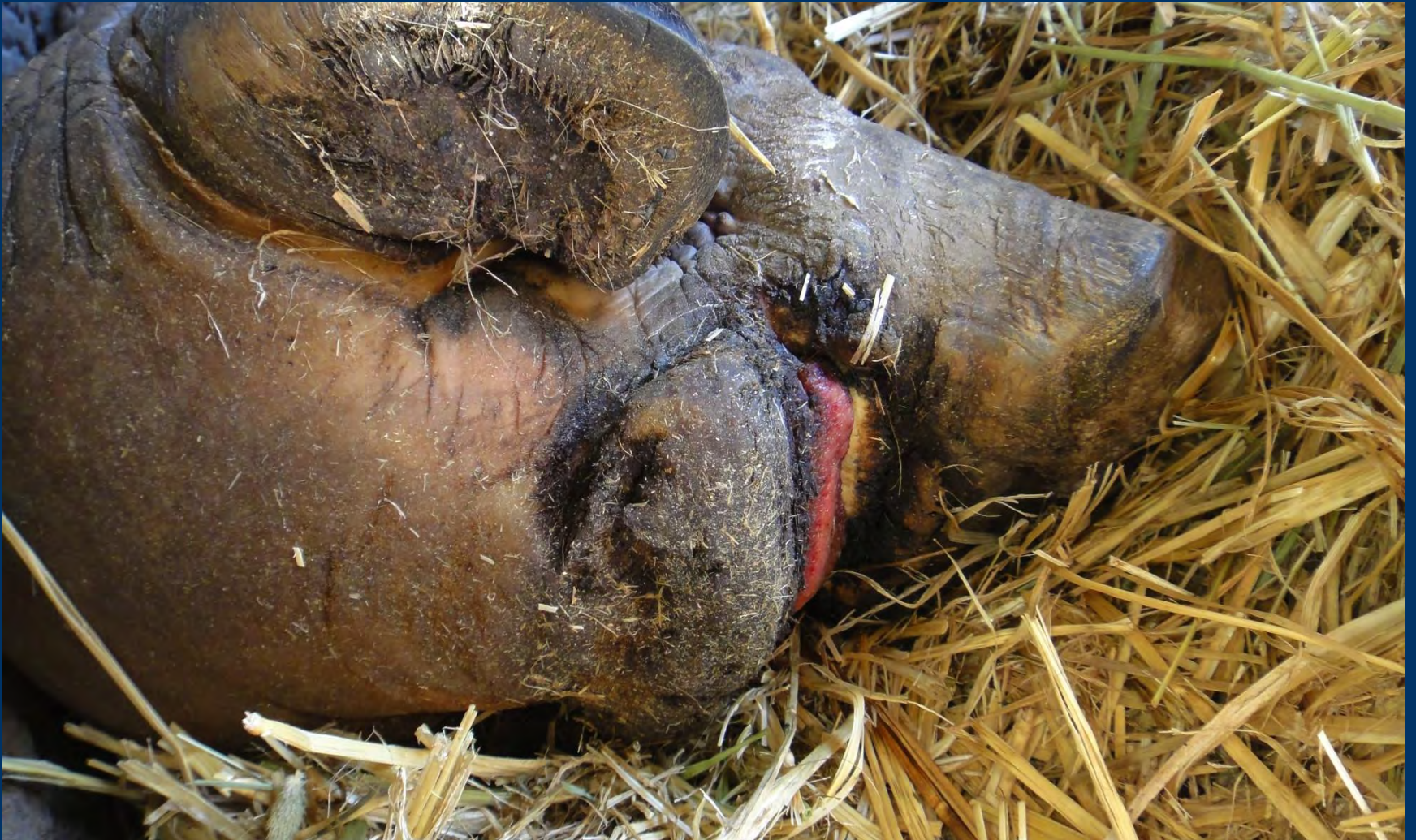Traditional flooring Tatami 2010




By trial and error, they made a soft floor lined with straw



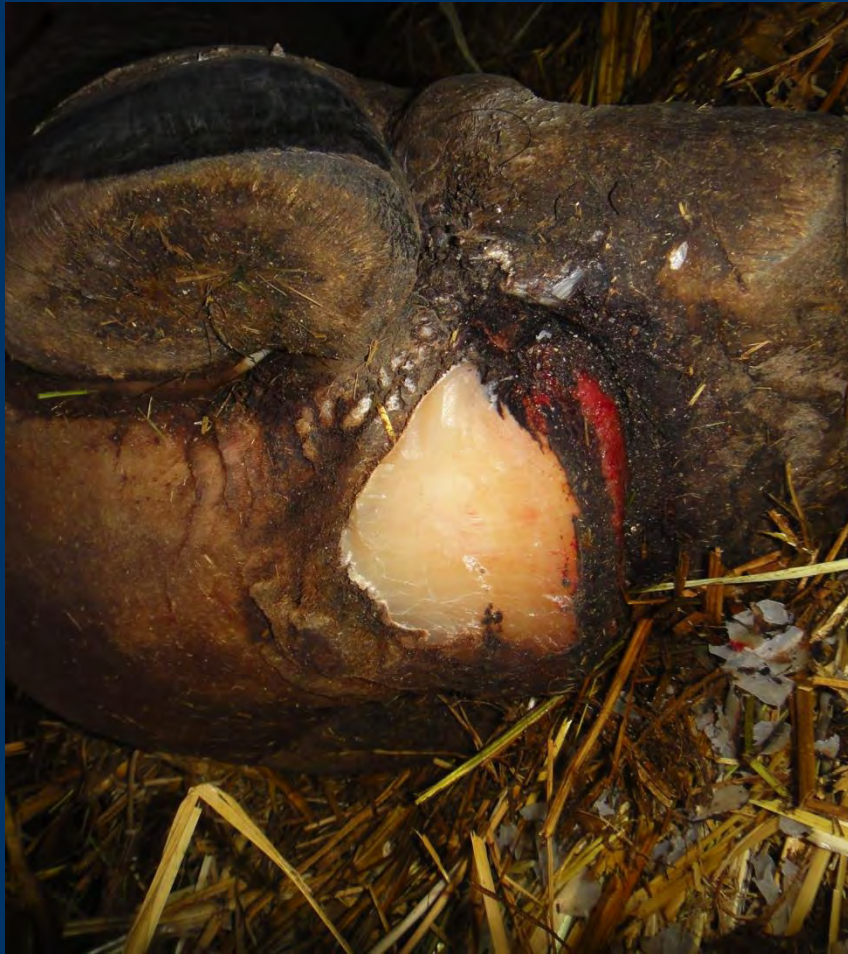
No dramatic improvement in the change of the inside stable only (2010 November)




Floor of the small outside enclosure was changed to wood chip



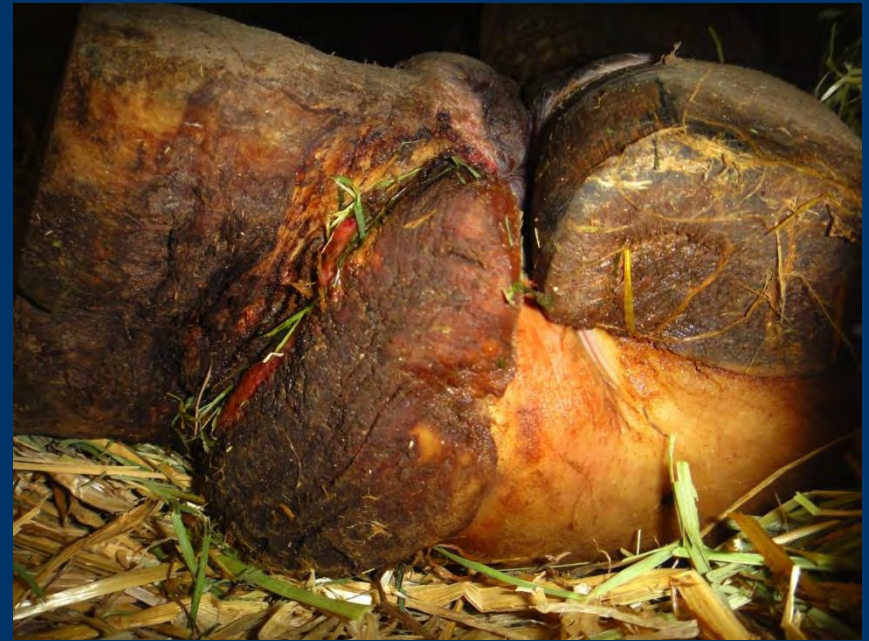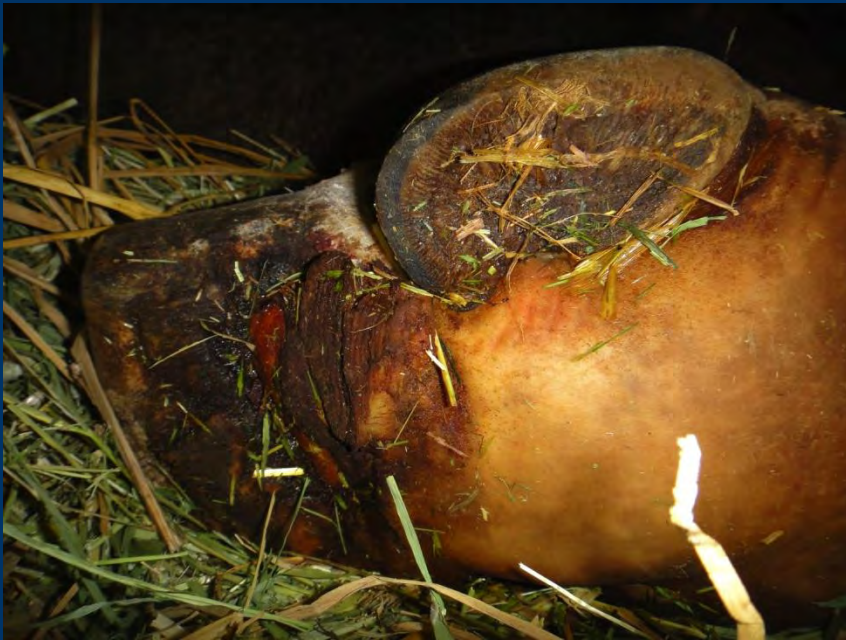Still not a big change 2011 January



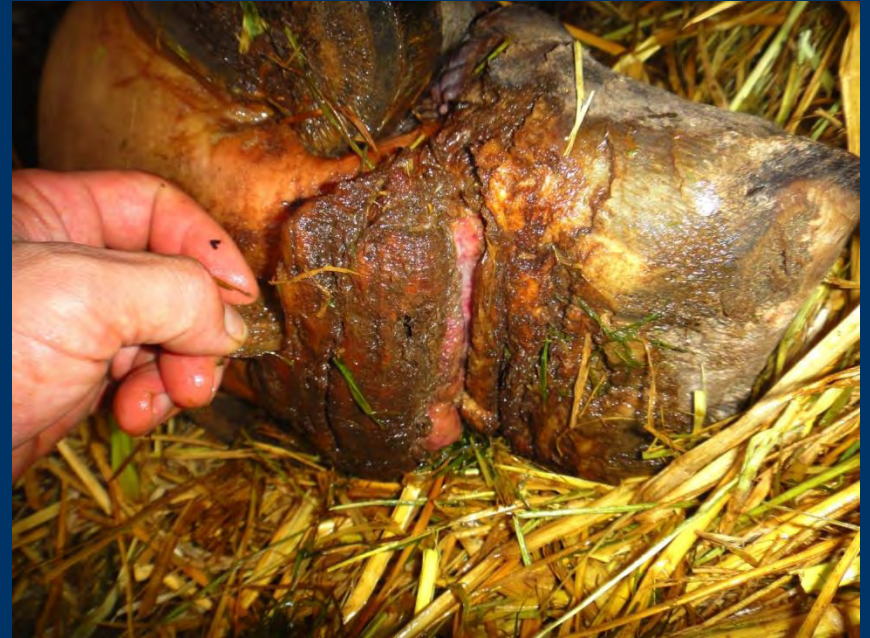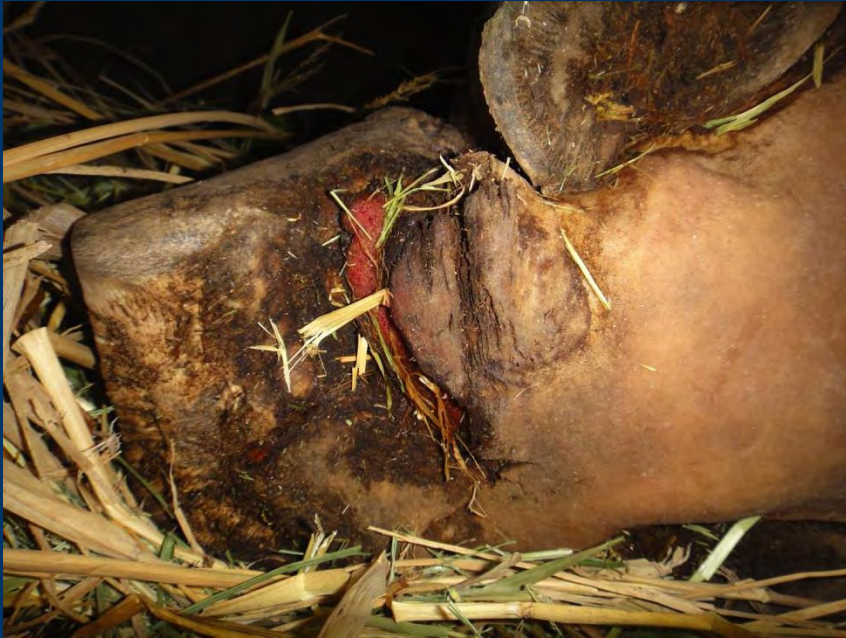The outdoor exhibit was completely changed



After changing to wood chips,
the pad was not thickening
2011 June



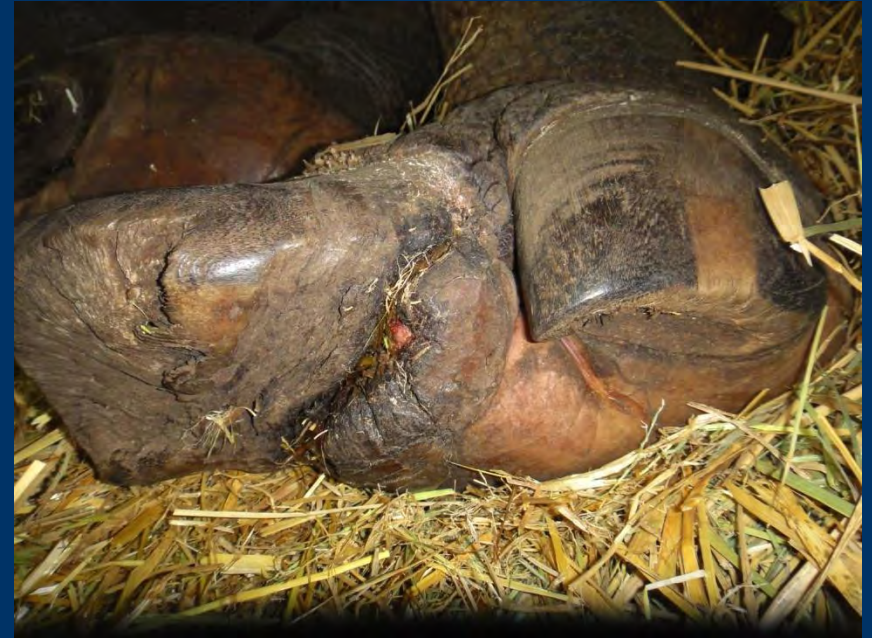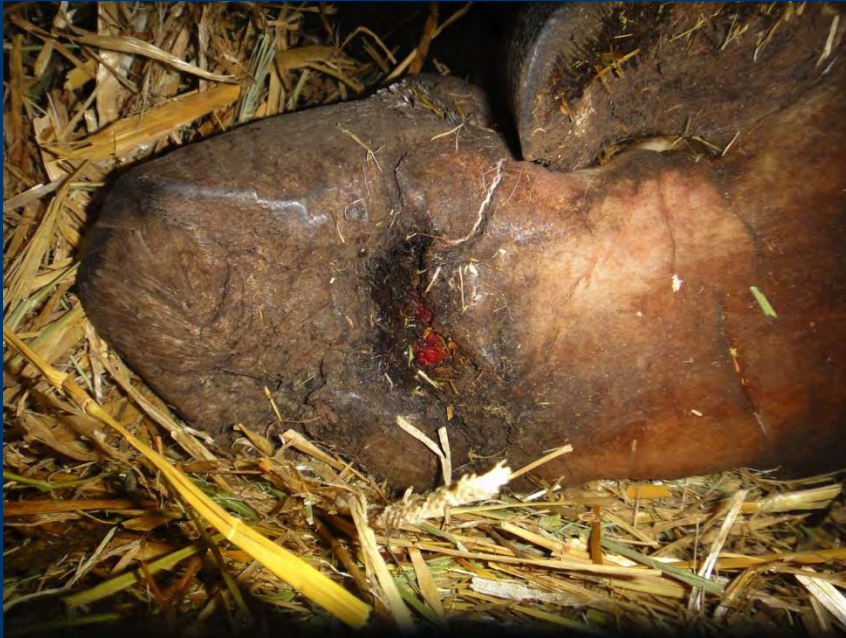Cut in the pad was reduced little
by little
2011 September



Feet improve in spring, difficult in winter (2011 December)



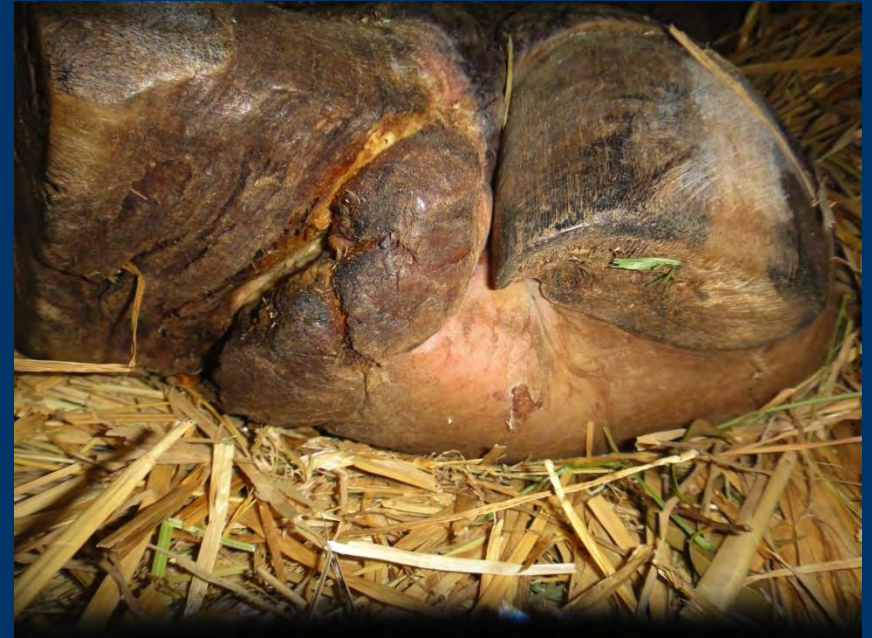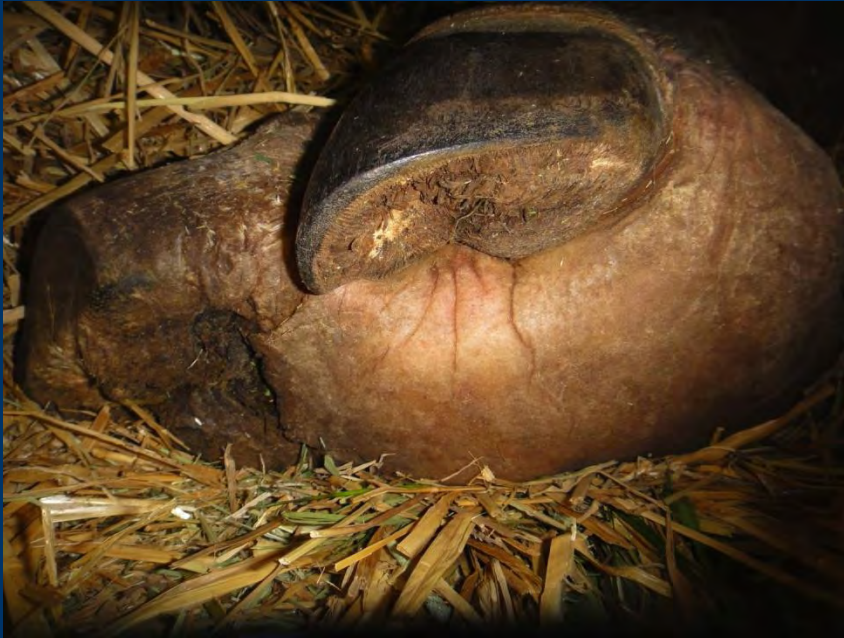Spring 2013 (temperature and humidity?)



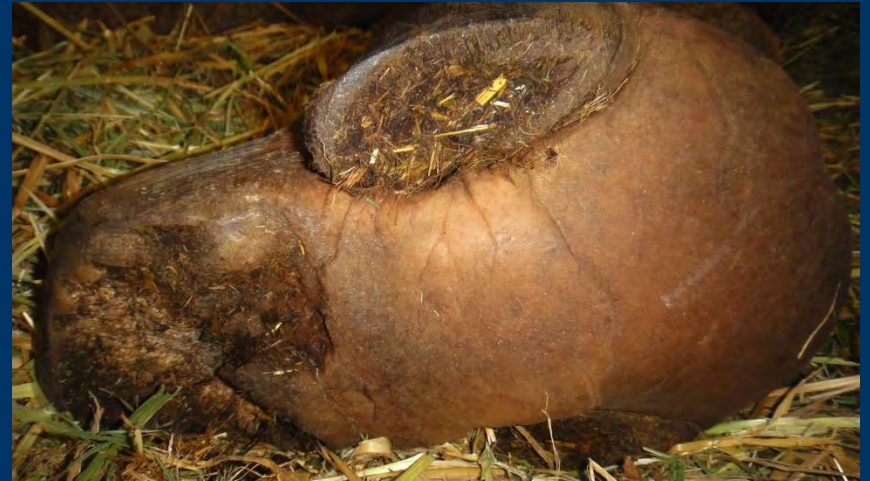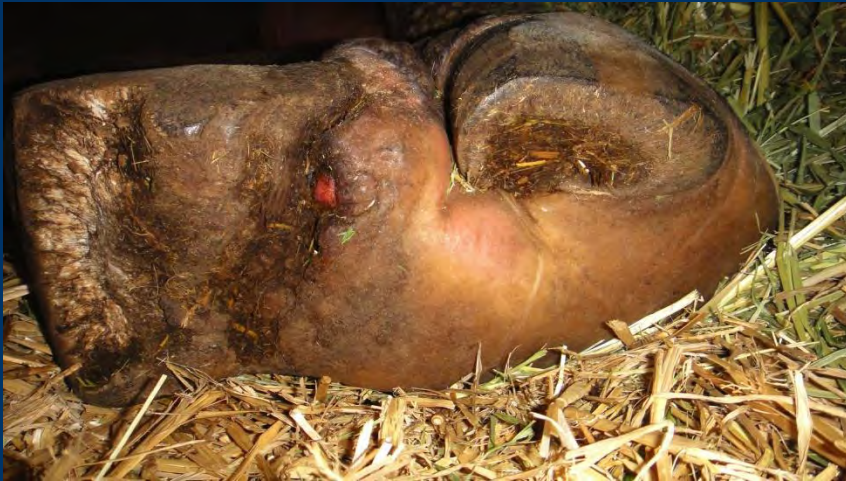Branches were applied under the ground of the outdoor enclosure for drainage and the softness



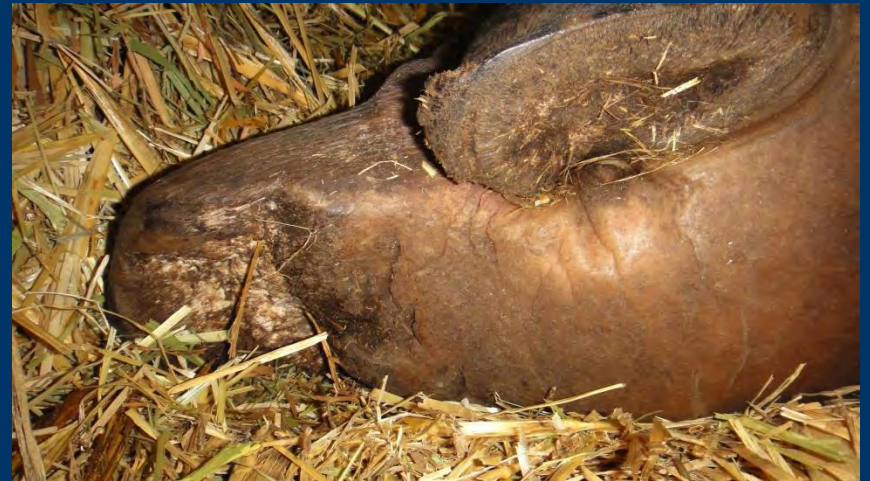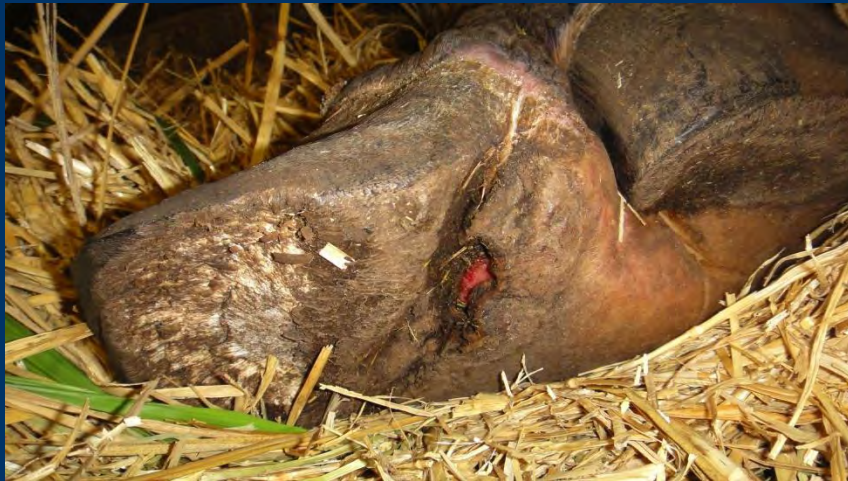After this, the feet became
rapidly well
2013 April



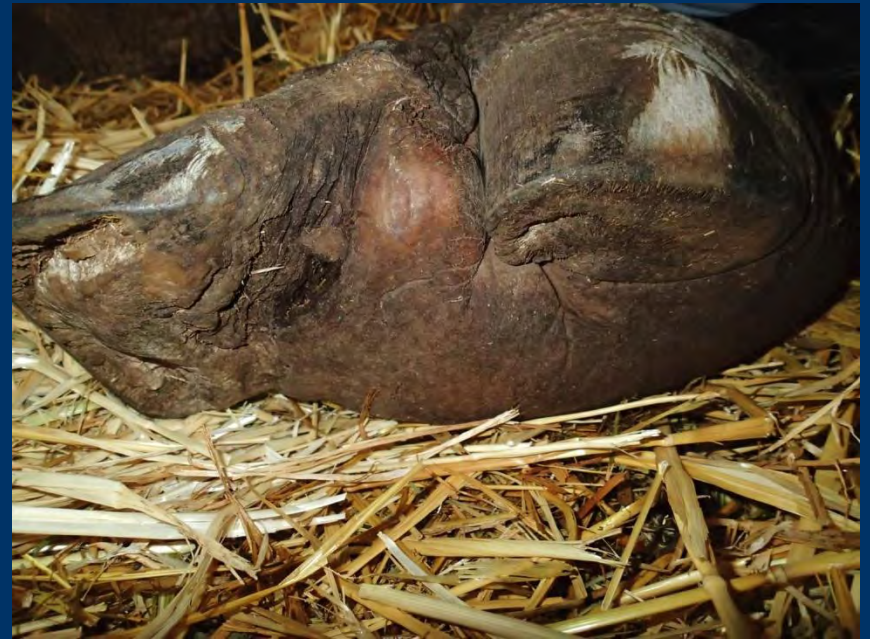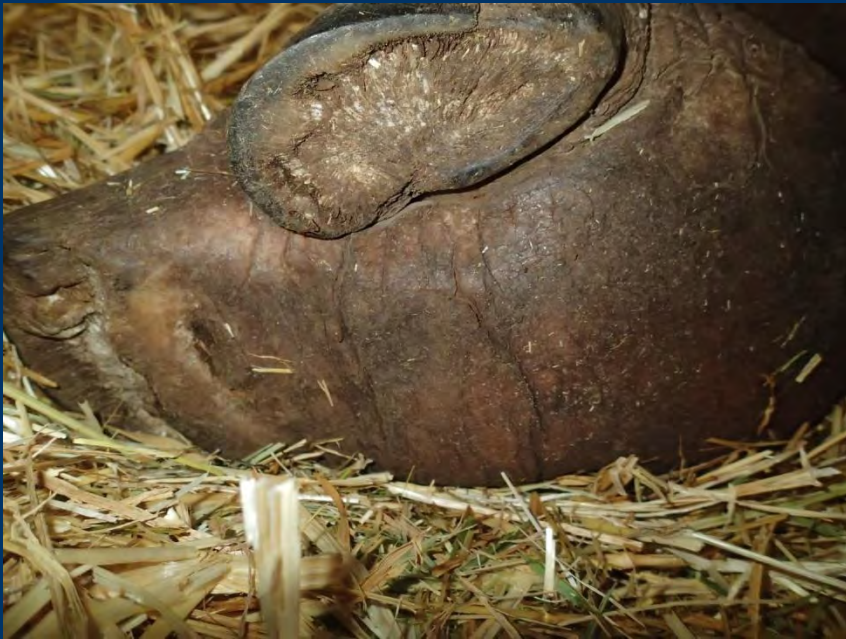2013 July



Right hind foot almost healed 2013 December



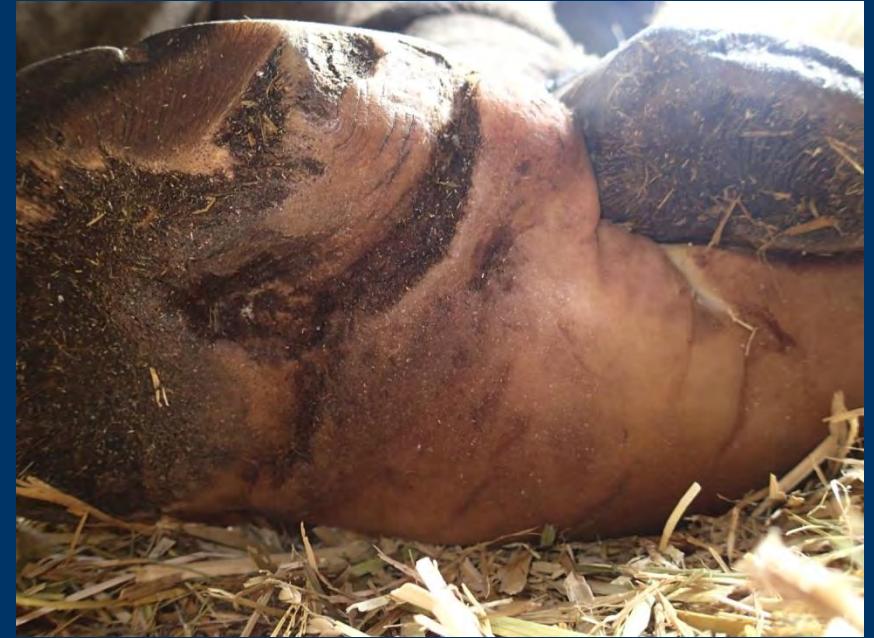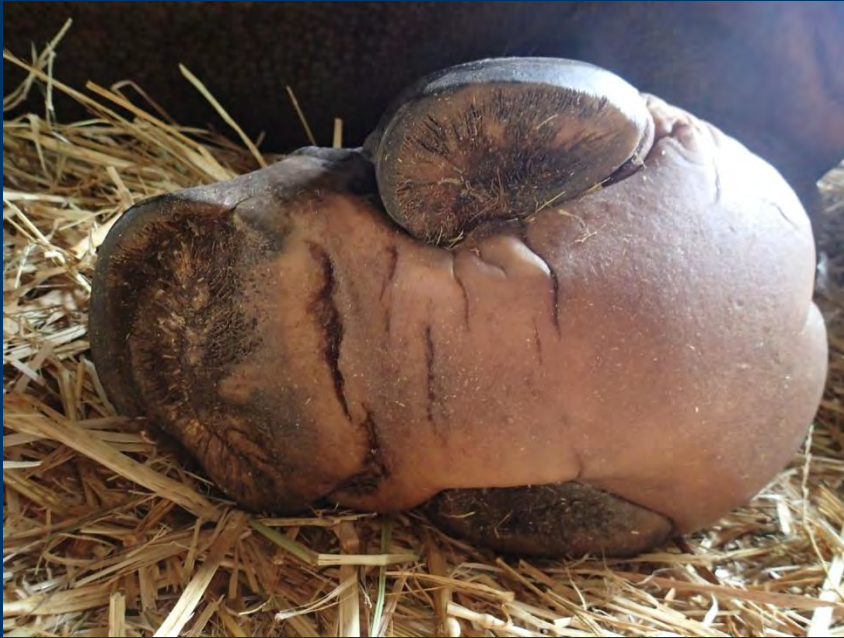Process of healing continues 2014 April



The last wounds were especially slow healing



Finally both hind feet wounds
were gone
2014 December



Masaru Senzaki

rhino keeper from Japan

- With the cooperation of many people, I was finally able to get rid of his pain.
- I want to thank all the
- If you have any questions, please contact this address.
- ma36_sen@yahoo.co.jp

Conclusion

- Yes, we can prevent (and even cure) CFD and all other FP issues by providing Indian Rhinos a natural environment which does not cause any abrasions
- The EEP for GOH recommends now:
- -Outside:
- use wood chips (no sand in feeding areas) and other non abrasive natural material (gras, earth,)
- - Inside
- Use wood chips, cocos, peat (but no rubber) as a long-term prevention method

Thanks for your attention



Questions ? : vonhouwald@zoobasel.ch