

NECROTIZING DERMATITIS IN BLACK RHINO HOW KEEPERS CAN SAVE THEIR ANIMALS

Dr Florence Ollivet Courtois
DVM consultant

Andy Fichet
Head zoo keeper Pont- scorff

Jacob Born the 23rd of June 1991

Dvur Kralove zoo (CZ)

Krefeld zoo (DE)

Zoo Pont Scorff (FR)



Siwa Born the 15th of March 1992



Zurich zoo (CH)

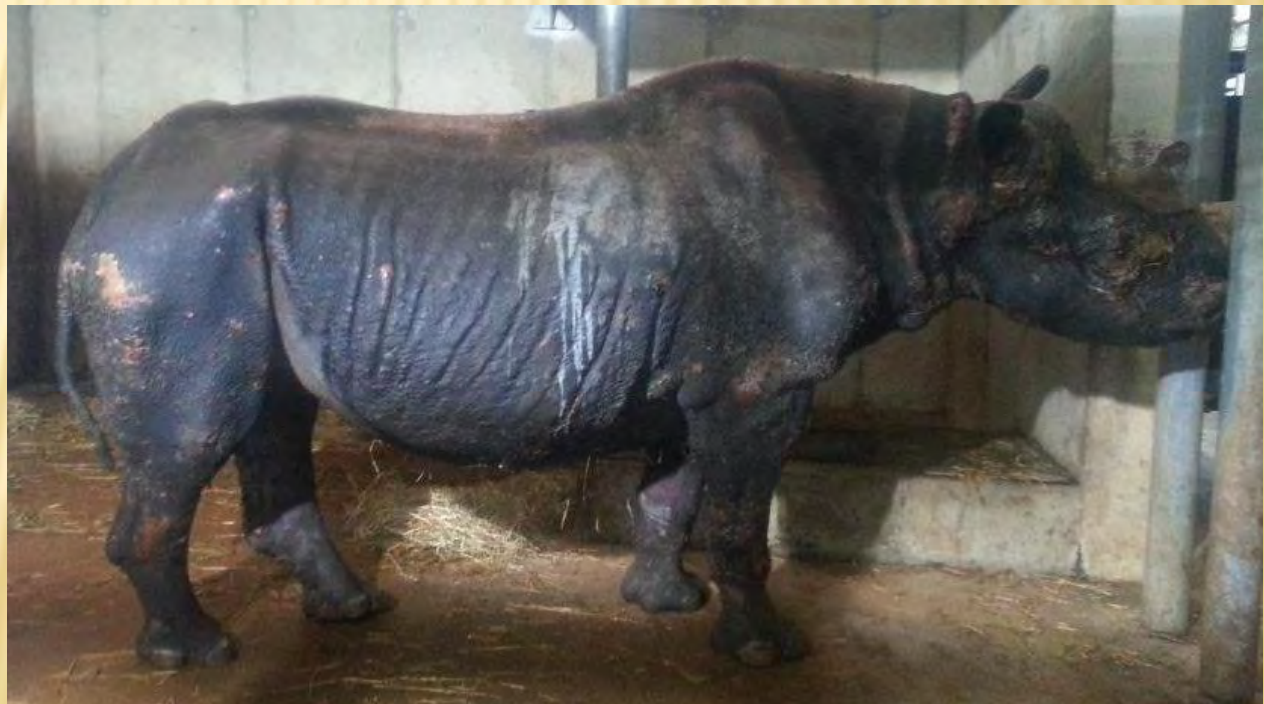Dortmund zoo (DE)

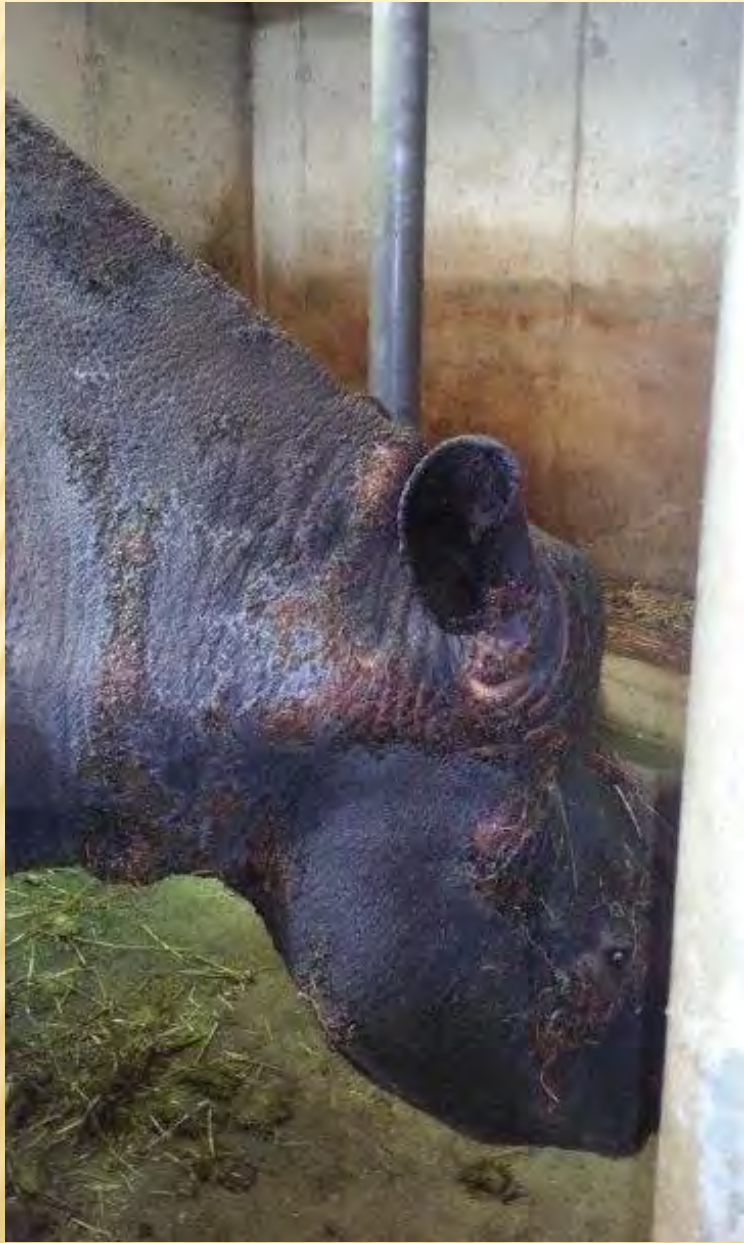Zoo de Pont Scorff (FR)

The disease

- ✘ Major disease with very high prevalence
- ✘ No pathogen isolated
- ✘ Common in Winter (temperature stress)
- ✘ Causes?
 - + Stress (transportation, pregnancy, harassment, diseases)
 - + Diet (vitamin E deficiency, fatty acid deficiency, zinc deficiency, balance calcium/phosphorus....)

- ✘ Cutaneous necrotizing ulcers, no inflammation
- ✘ Bilaterally Symmetrical lesions
- ✘ Pressure points, tips of ears and tail, dorsum, feet
- ✘ Oral lesions and cutaneo mucosal junctions
- ✘ vesicles => ulcers.





Medical history in PontScorff ZOO

- ✘ Every winter for Jacob.
 - Ulcers with secondary infection.
- ✘ Siwa First time in 2012
- ✘ Treatment:
 - Antibiotics : sulfamids TMP.
 - Pain killer NSAID : phenylbutazon
 - Skin Disinfectant + wound healing product.
- ✘ Siwa died 1 month after the first ulcer

Clinical exam

- × Serious burn victim appearance
- × Severe pain
- × Loss of appetite and condition
- × Very acid feces smelling

Siwa necropsy lessons

- ✘ Lung infection resistant to TMP/ Sulfa
- ✘ Ulcers in digestive tract : so NSAID contraindicated
- ✘ Liver disease



Additional exams

- ✘ chemistry: large screening
 - + Low total protein and albumin level : burns, liver disease, diet deficiency in protein
 - + High Potassium : renal deficiency, muscle disease. Can affect heart muscle
 - + AST and LDH elevated: liver and muscle disease
 - + CPK very high : muscles lesions,
 - + Vitamin E : undetectable: 0

Treatment

- ✘ New antibiotics : enrofloxacin instead of Sulfa/TMP
- ✘ Morphine skin patch instead of NSAID (DURAGESIC)
- ✘ Proton pump inhibitors against digestive ulcers : omeprazole
- ✘ Liver protection : methionine choline sorbitol
- ✘ Renal insufficiency treatment: EQUISTRO
ELIMINATION (plants to increase renal function)
- ✘ When labored breathing : clenbuterol
- ✘ Rectal rehydration and medication

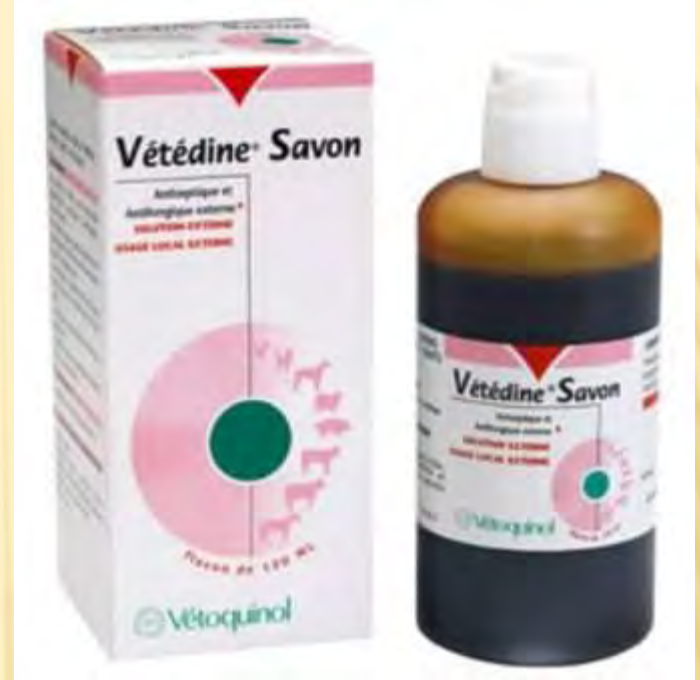NEW DIET

Increase Proteins

- ✘ More vegetables (6kg) and Browser pellets (5kg).
- ✘ Add alfalfa pellets (500g)
- ✘ Better alfalfa hay (TP=17%) (2/3) + hay (1/3)
- ✘ Zinc + biotin
- ✘ Mineral complex with low phosphorus
- ✘ No more fruits (because of fermentation and acidity)
- ✘ Vitamin E: Emcelle (failure to increase vitamin E blood level with classic supplements).

PREVENTIVE SKIN CARE

- Weekly Iodine polyvidone soap

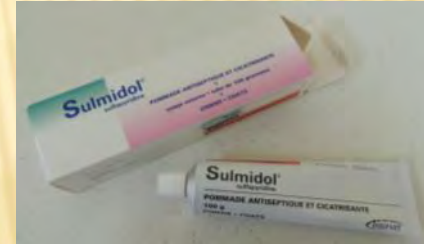



=> Insist in skin folds

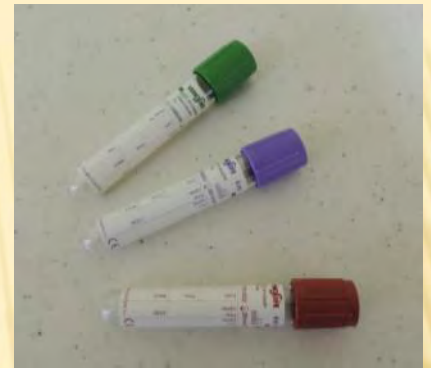

Antibiotic ointments at
first lesions:
Sulmidol
Or Clay




Regular blood sample

Complete chemistry screening (liver, renal)
Complete blood count (anemia, leukocytosis...)
Vitamin E



- 1 keeper in control
- 1 vet
- Protective contact



Rectal Palpation training

for rectal rehydration and clinical exam.



Here : sedated rhino nut possible with training

Laying down

To treat foot lesions



«Jacob, Down! »

OTHER TREATMENTS

- ✘ Stop UV light specially when skin lesions appear
- ✘ Sweet almond oil on skin for better skin hydration, more breathable for skin
- ✘ Since 2012 : no recurrence

Thank YOU