



Chronic perforating foot sole lesions in 2
captive great Indian rhinoceroses
(*Rhinoceros unicornis*).

Willem Schaftenaar, DVM
Rotterdam Zoo





Namaste

Born: Februari 1991 (Stuttgard)

Acquired: July 1993 → old enclosure

1994 → Taman indah









Taman indah in 1993

- Concrete floor with straw bedding; later modified in rubber floor.
- 2 narrow boxes
- 1 small indoor enclosure + bath
- Large outdoor enclosure (sand + moat)















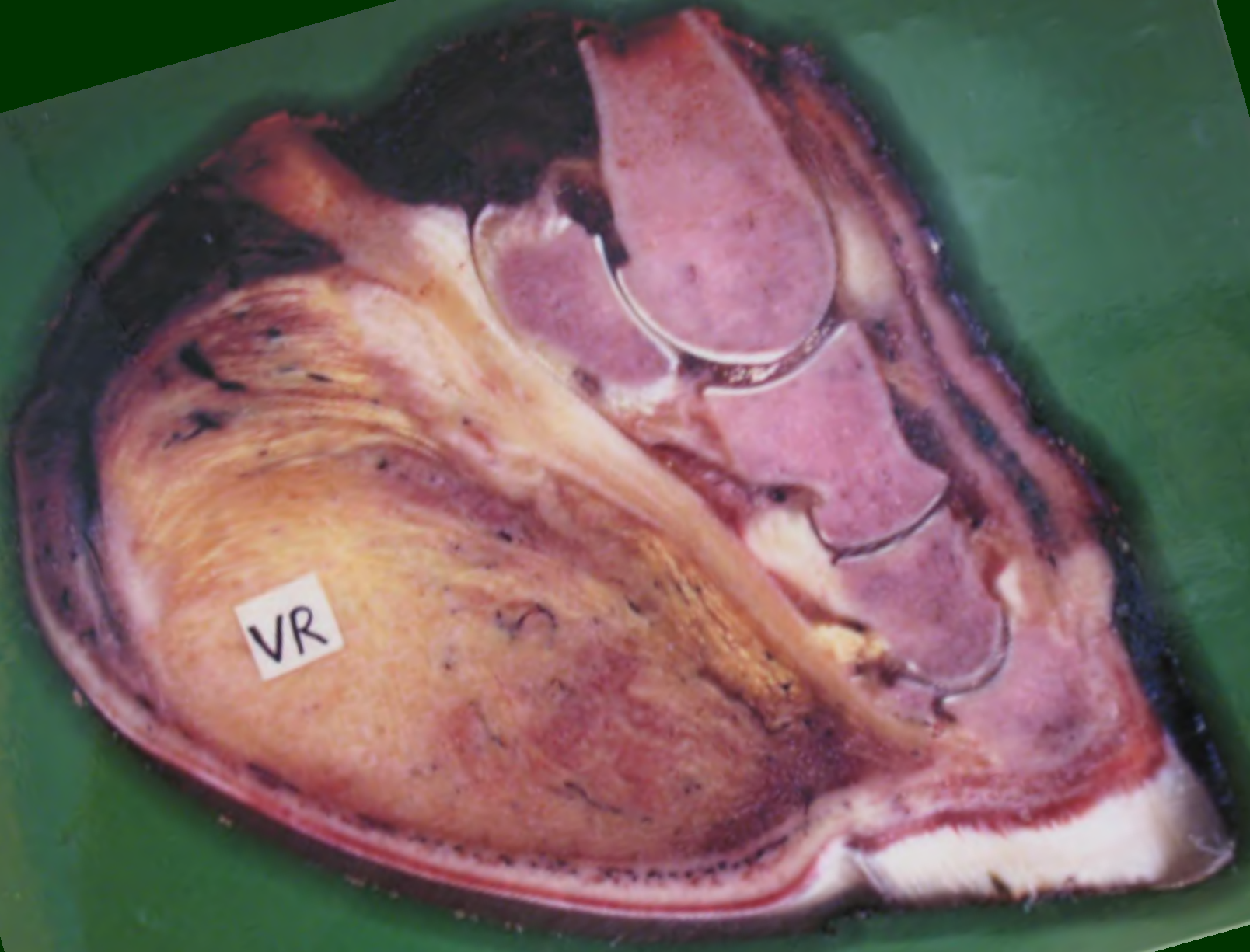




Frederique von Houwald



Frederique von Houwald




Frederique von Houwald



Frederique von Houwald



Res



- SmP
L38



.117

MI

0.5

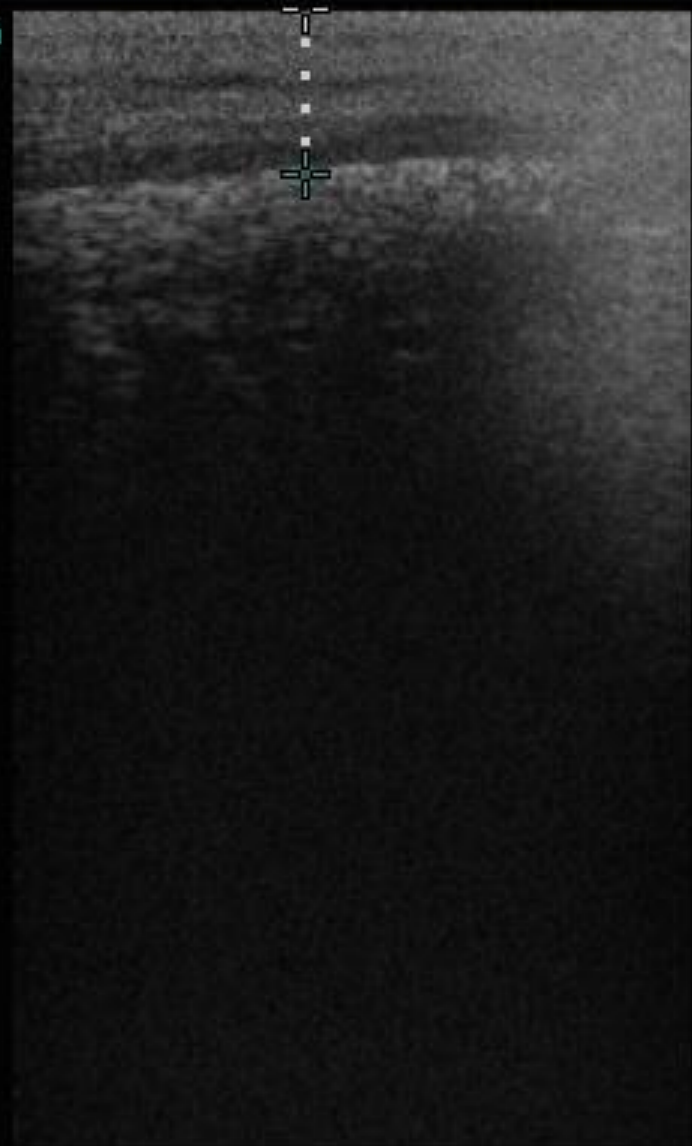

78

3.9

+ 0.41cm

Res



- SmP
L38



45

MI

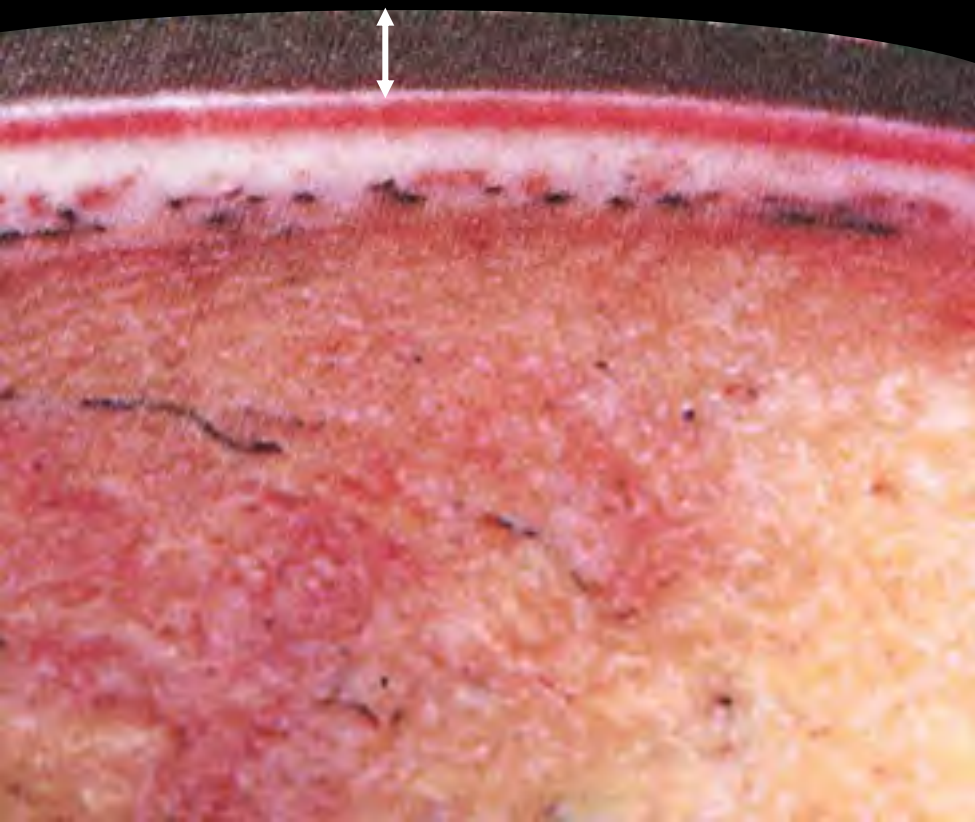
0.4



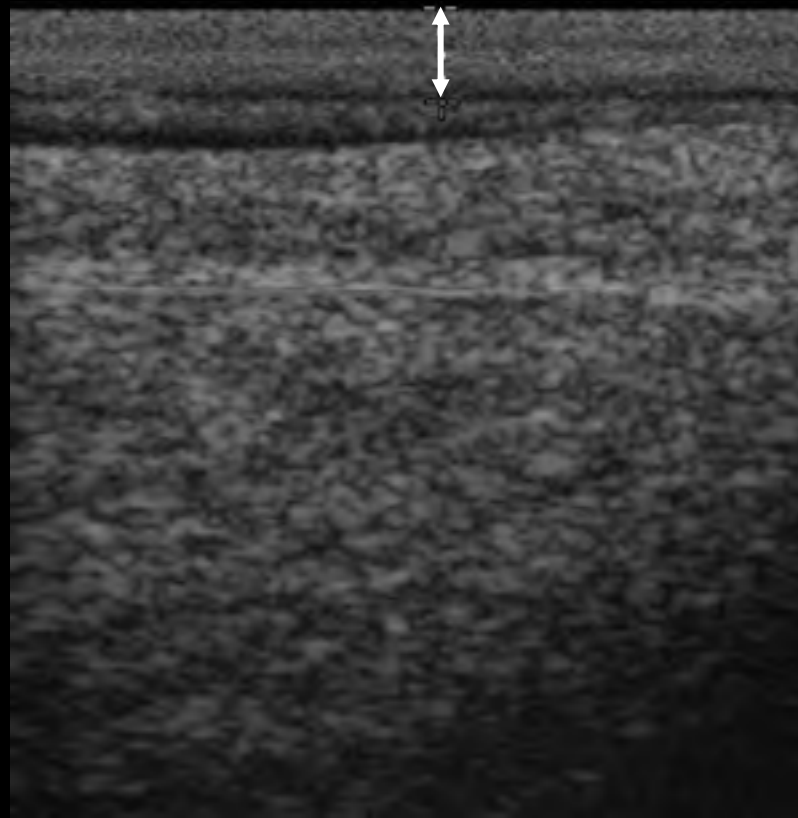
147

6.5

+ 0.93cm



4.3 mm





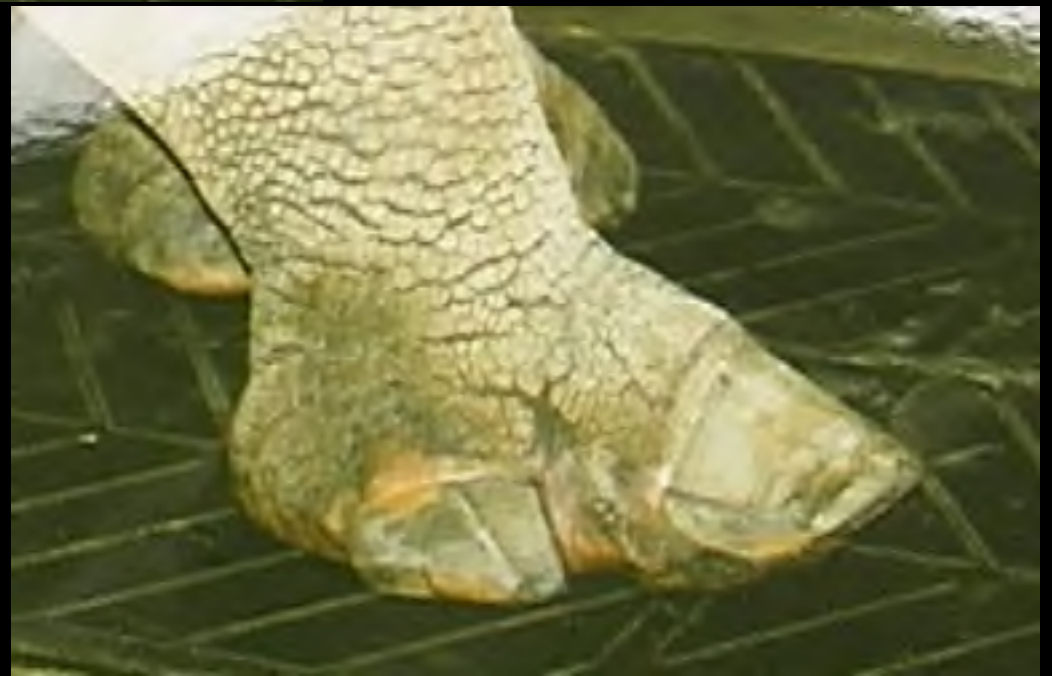1999: Namaste

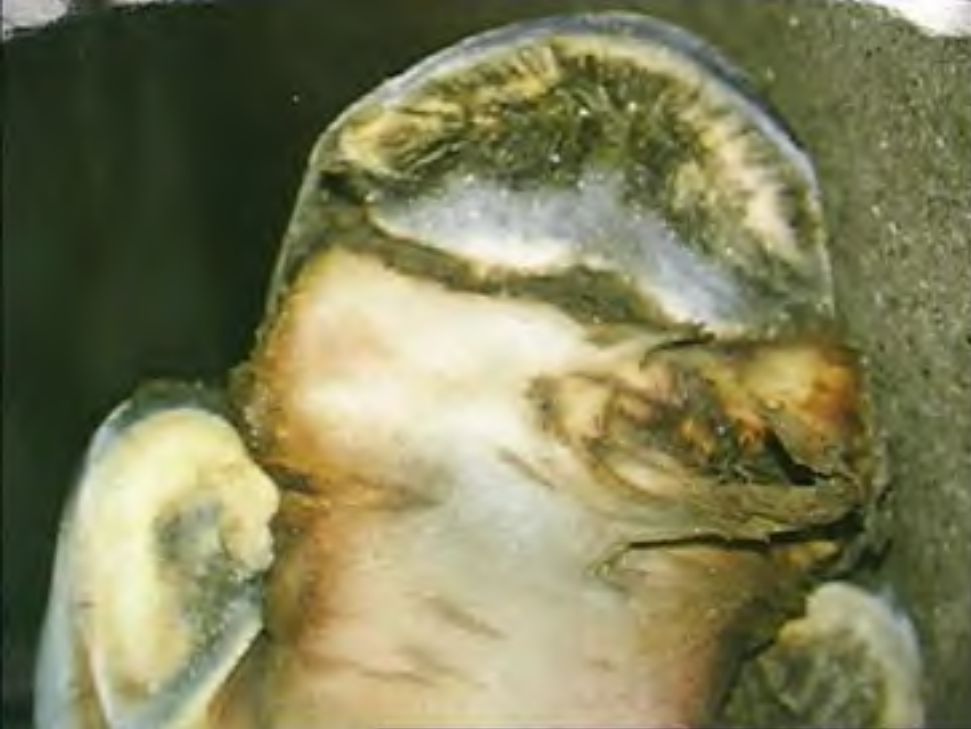- Moderate supporting lameness right hind leg
- Abnormal form of the right hind foot
- D3: nail not touching ground
- Swollen tissue around nail base



Namaste

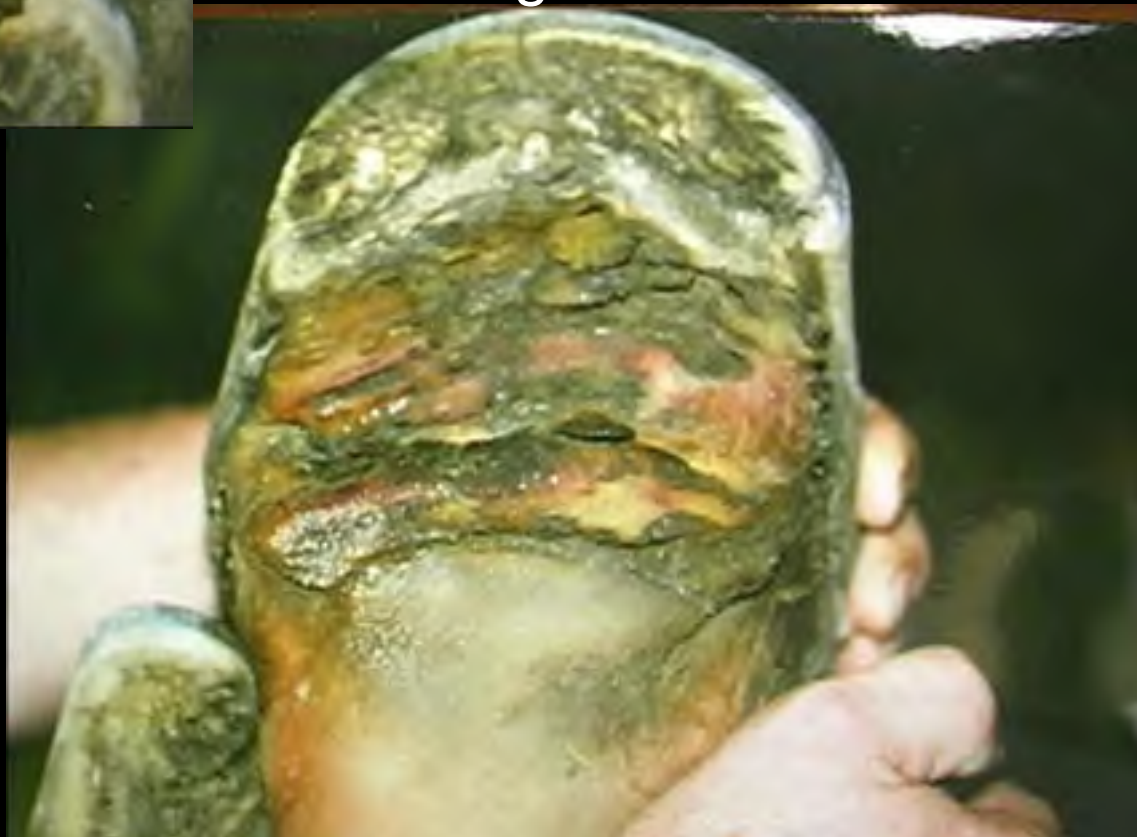1999

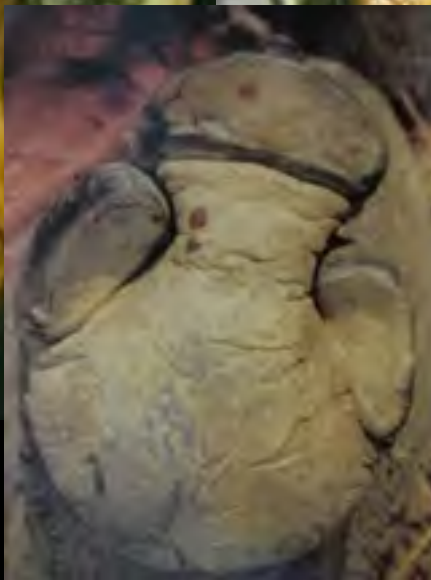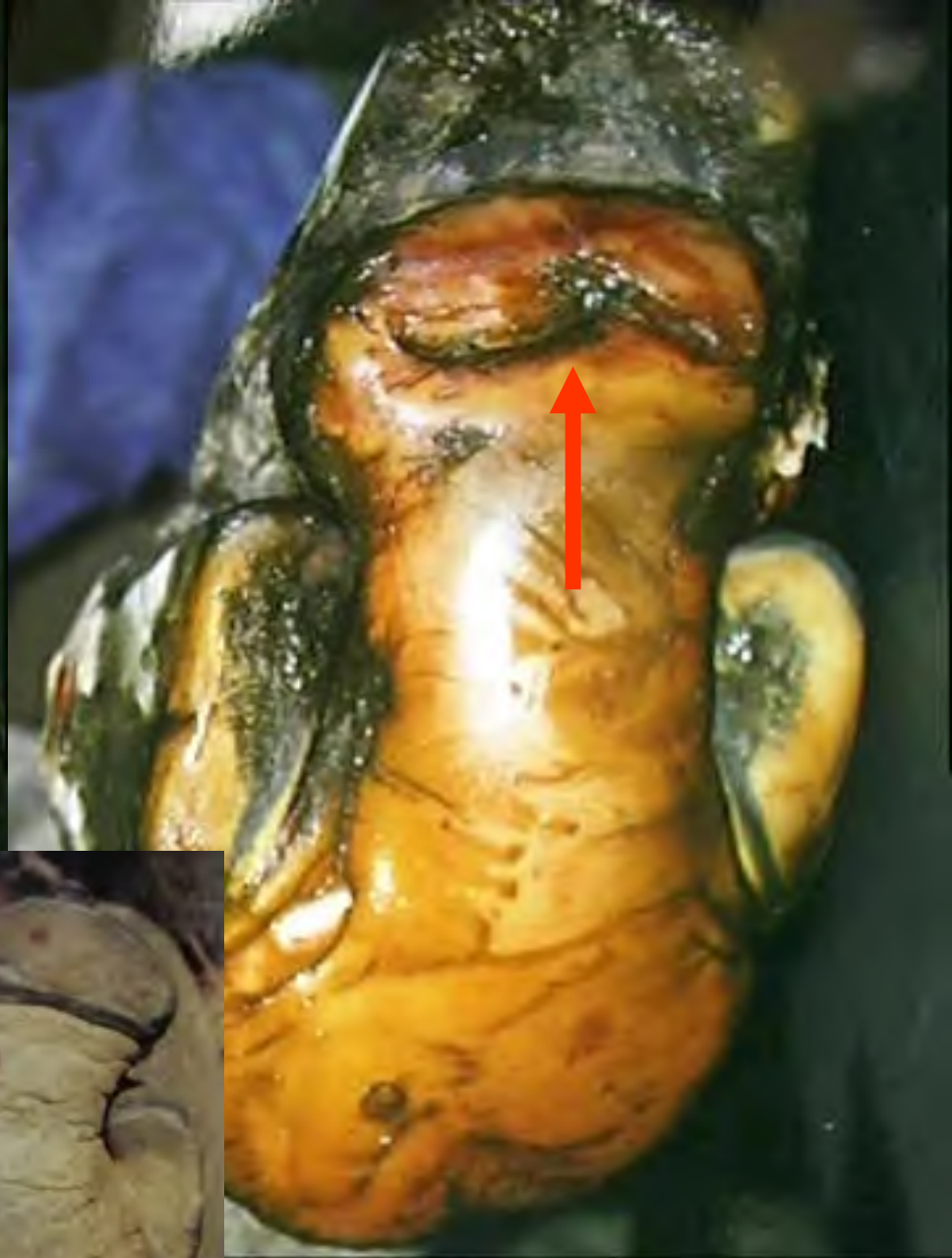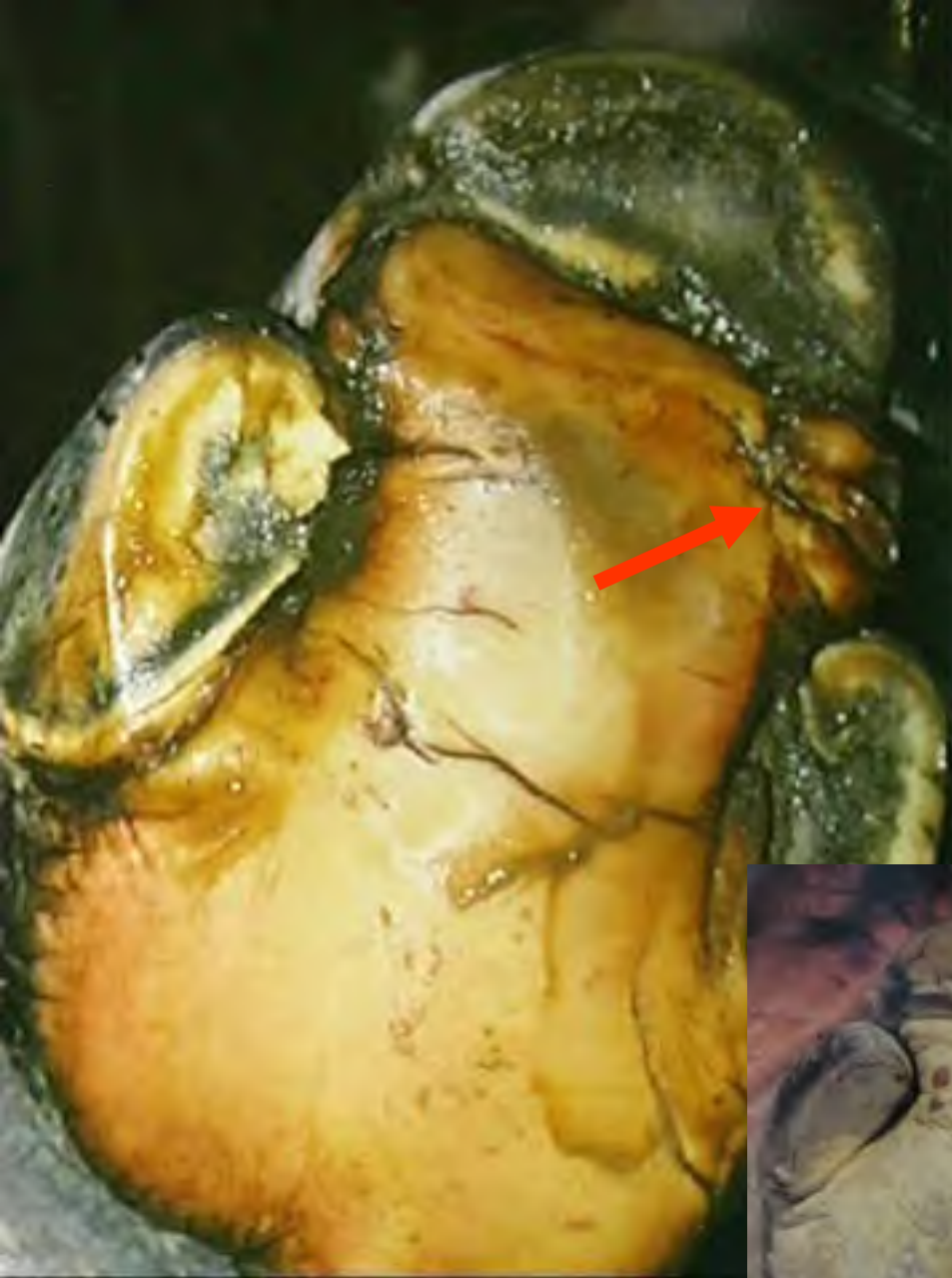




Left

Right 1999

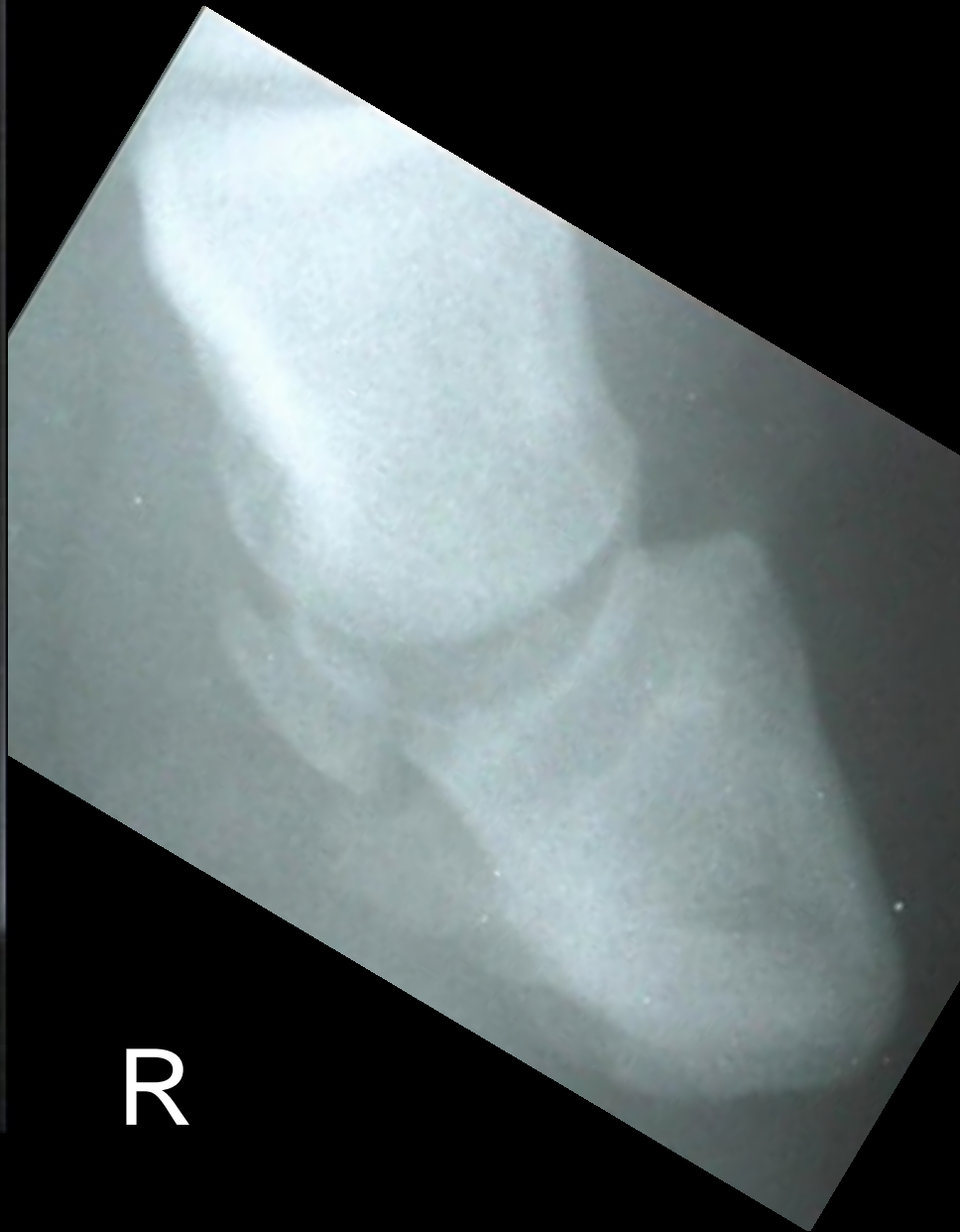
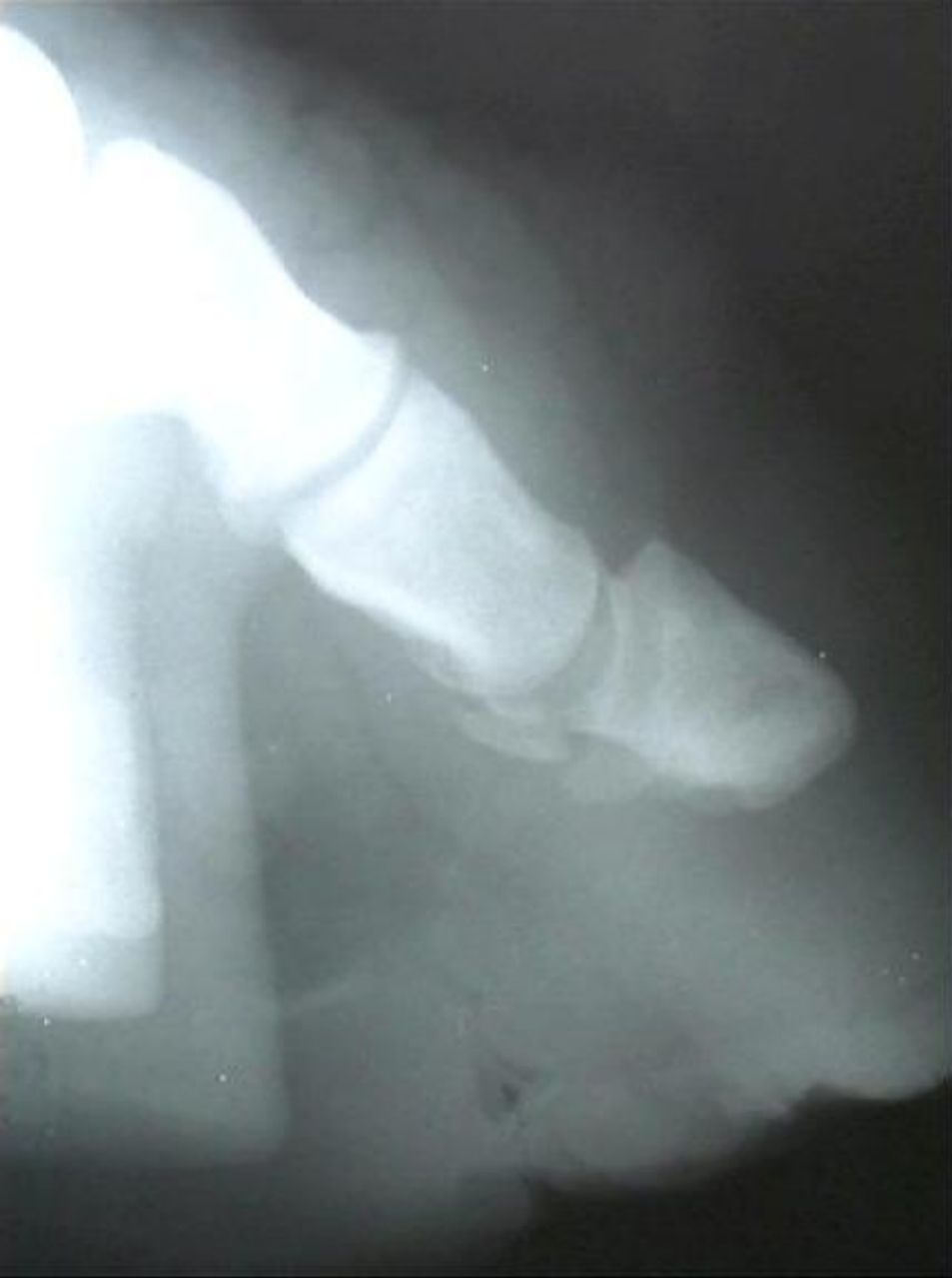


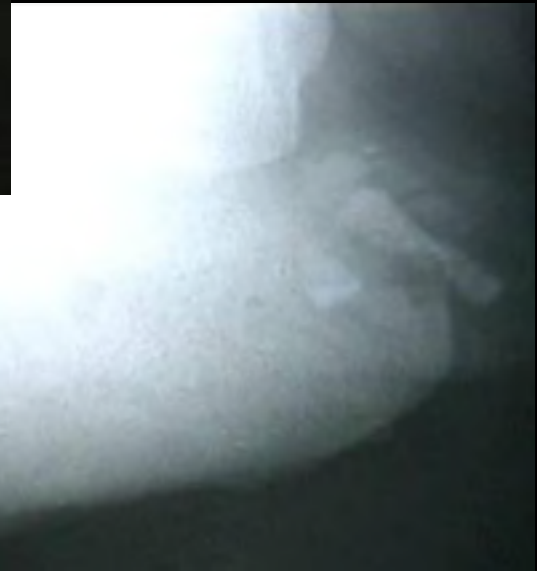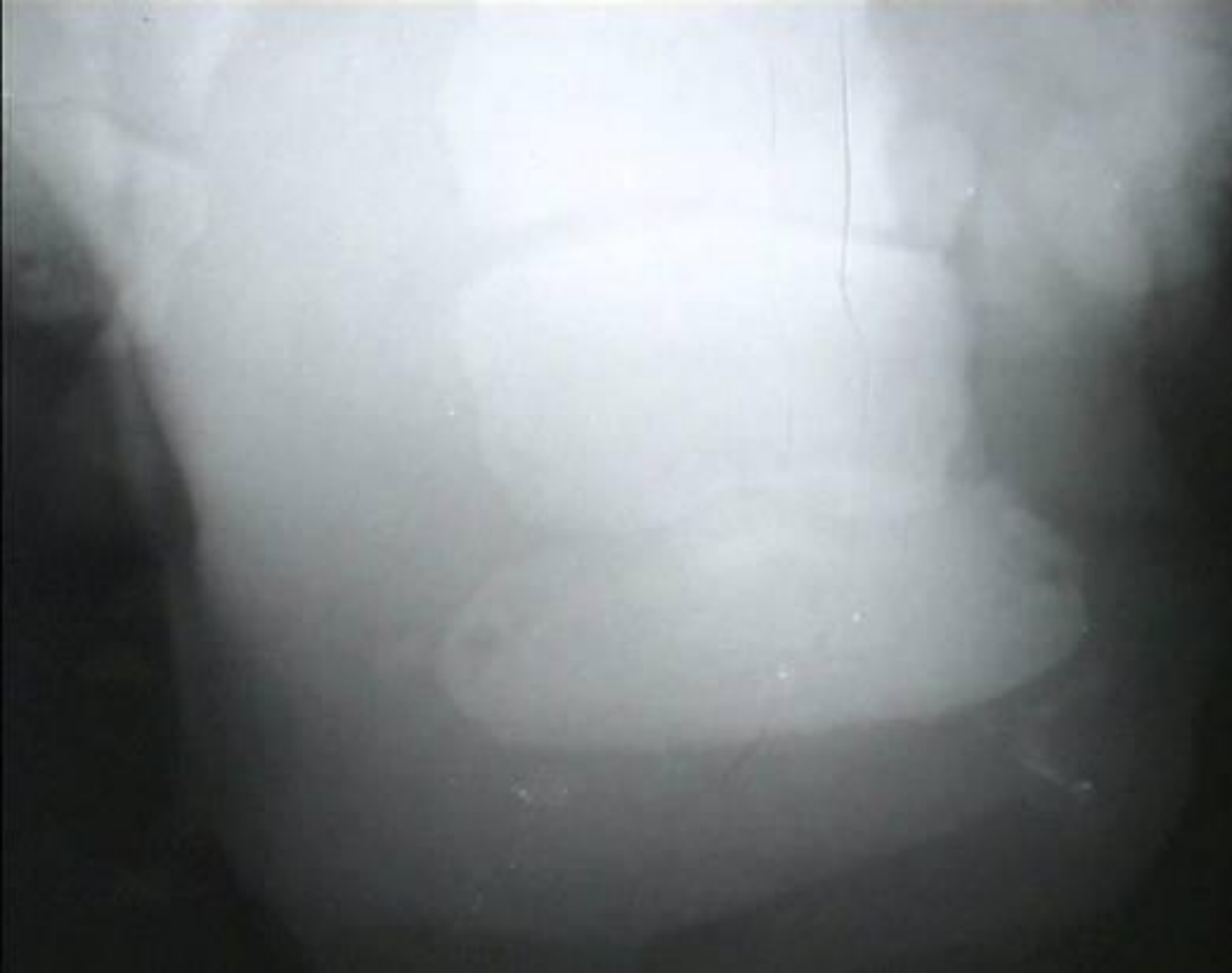


Right 1999





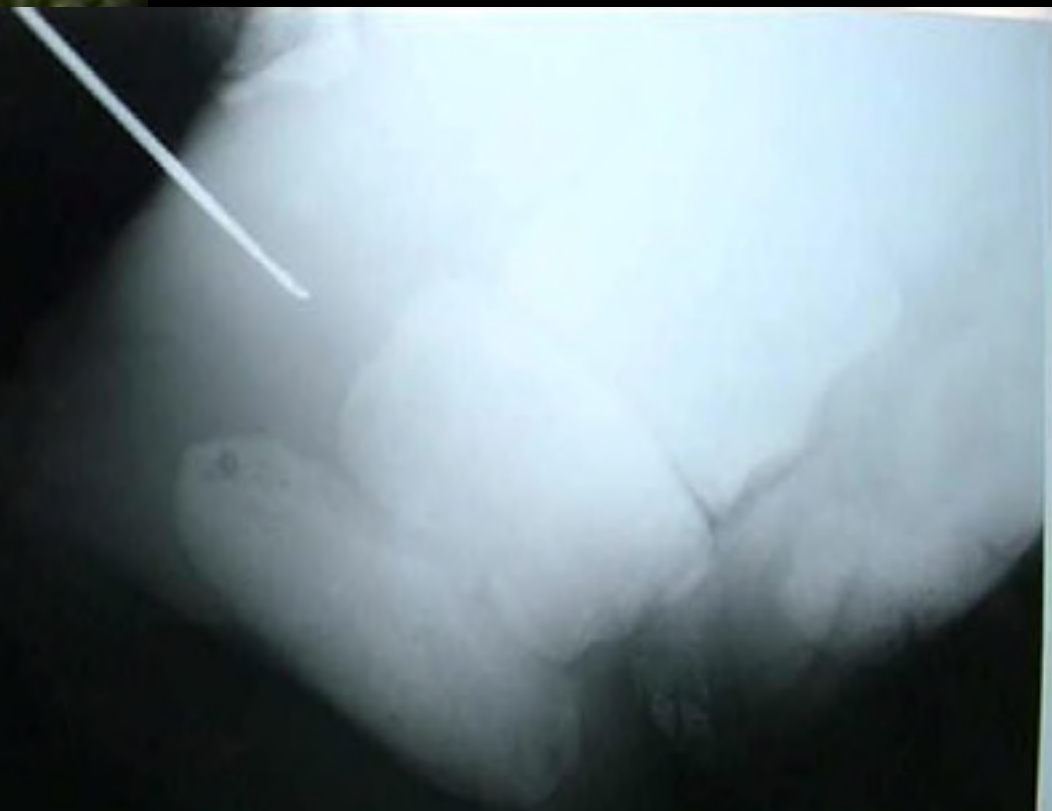R



R



Right 1999



Nico, born at Rotterdam Zoo October 1986





Nico, 2002

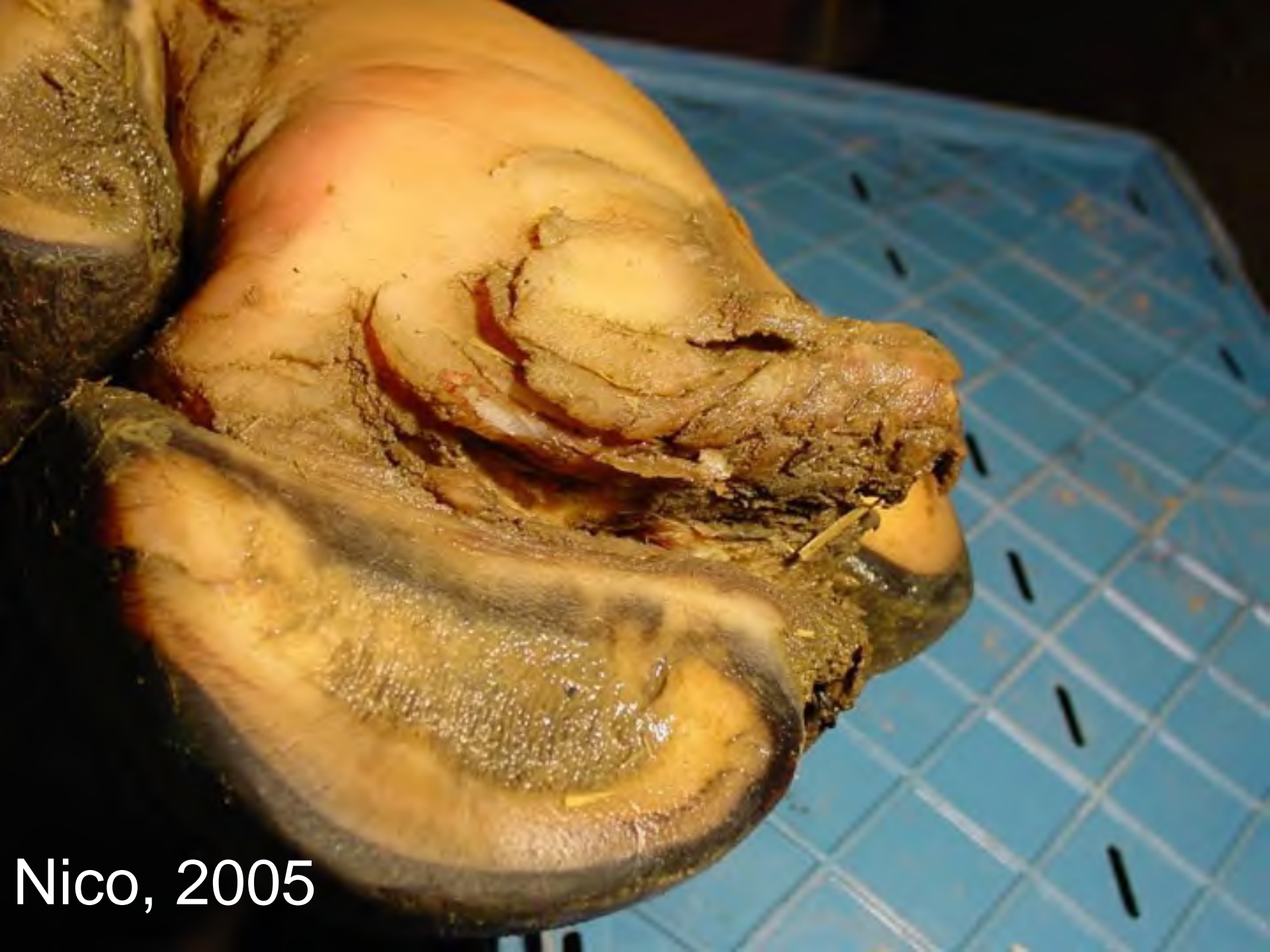

Nico, LH

2002



Nico, RH
2002

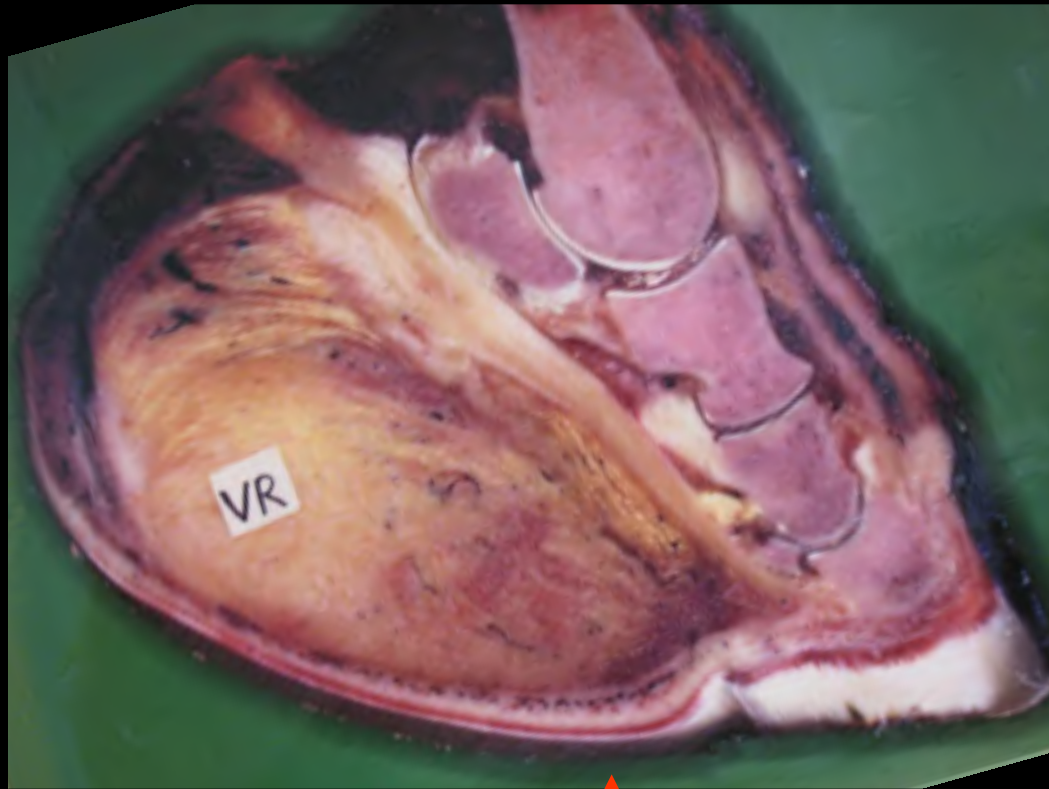


Nico, 2005

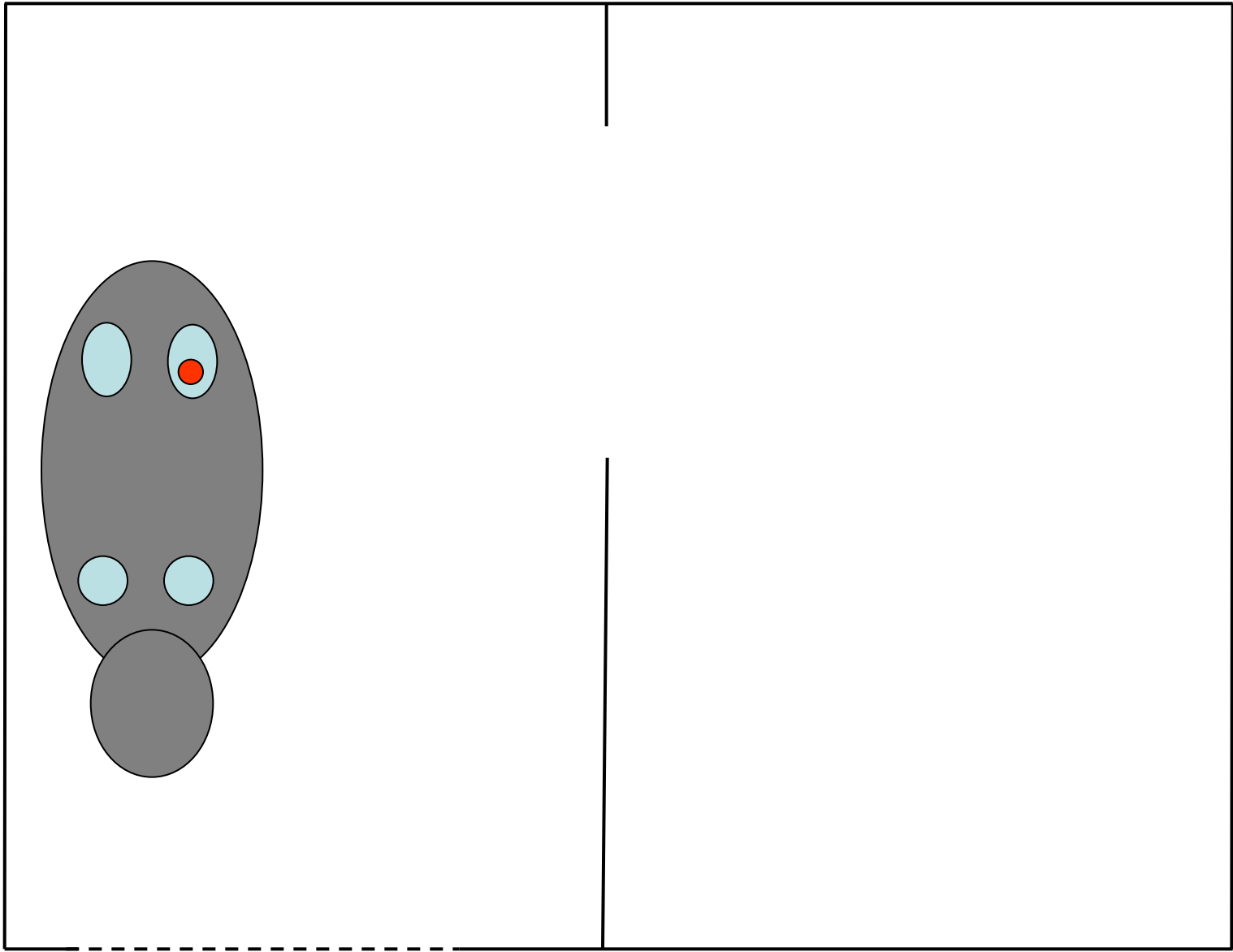


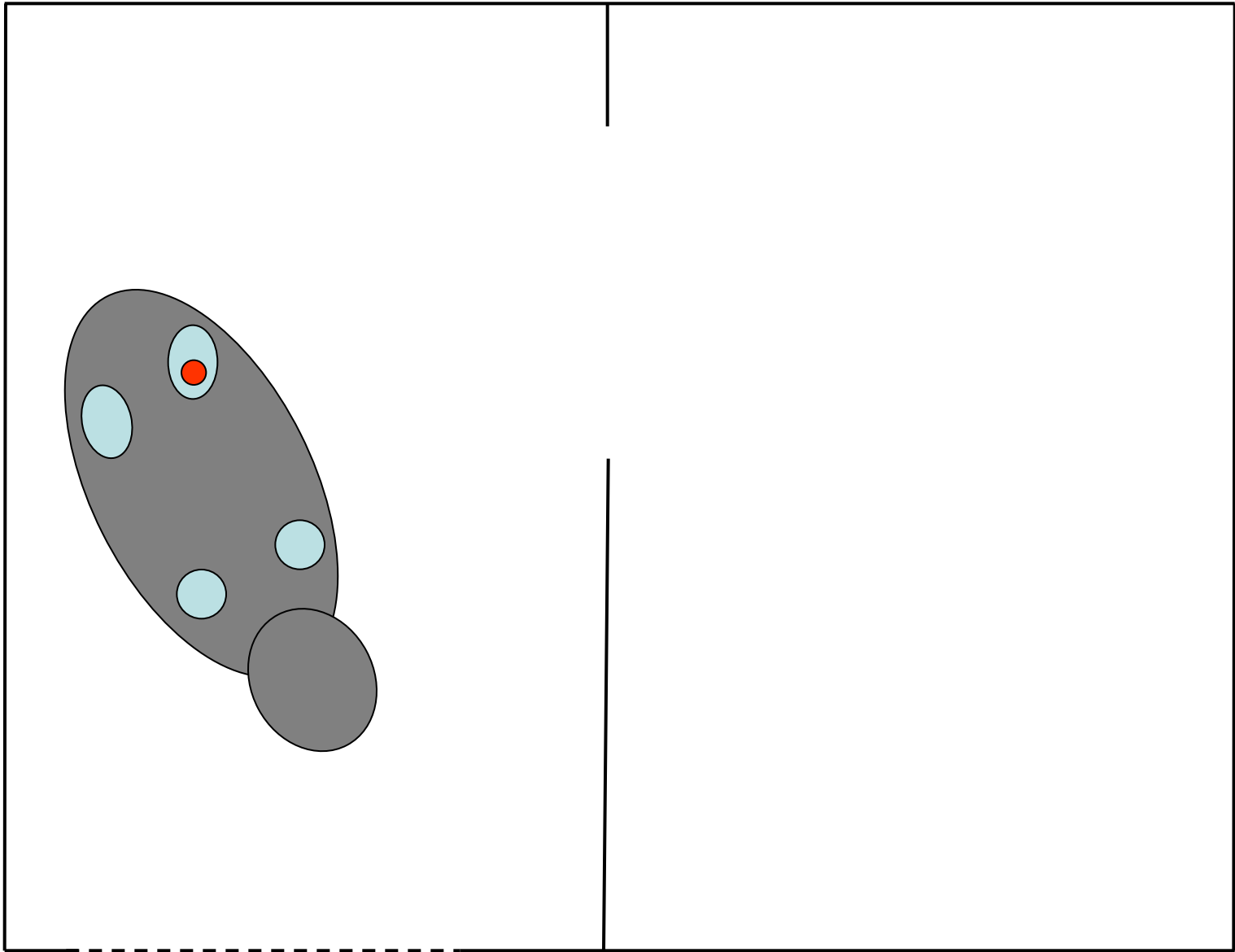
Possible causes?

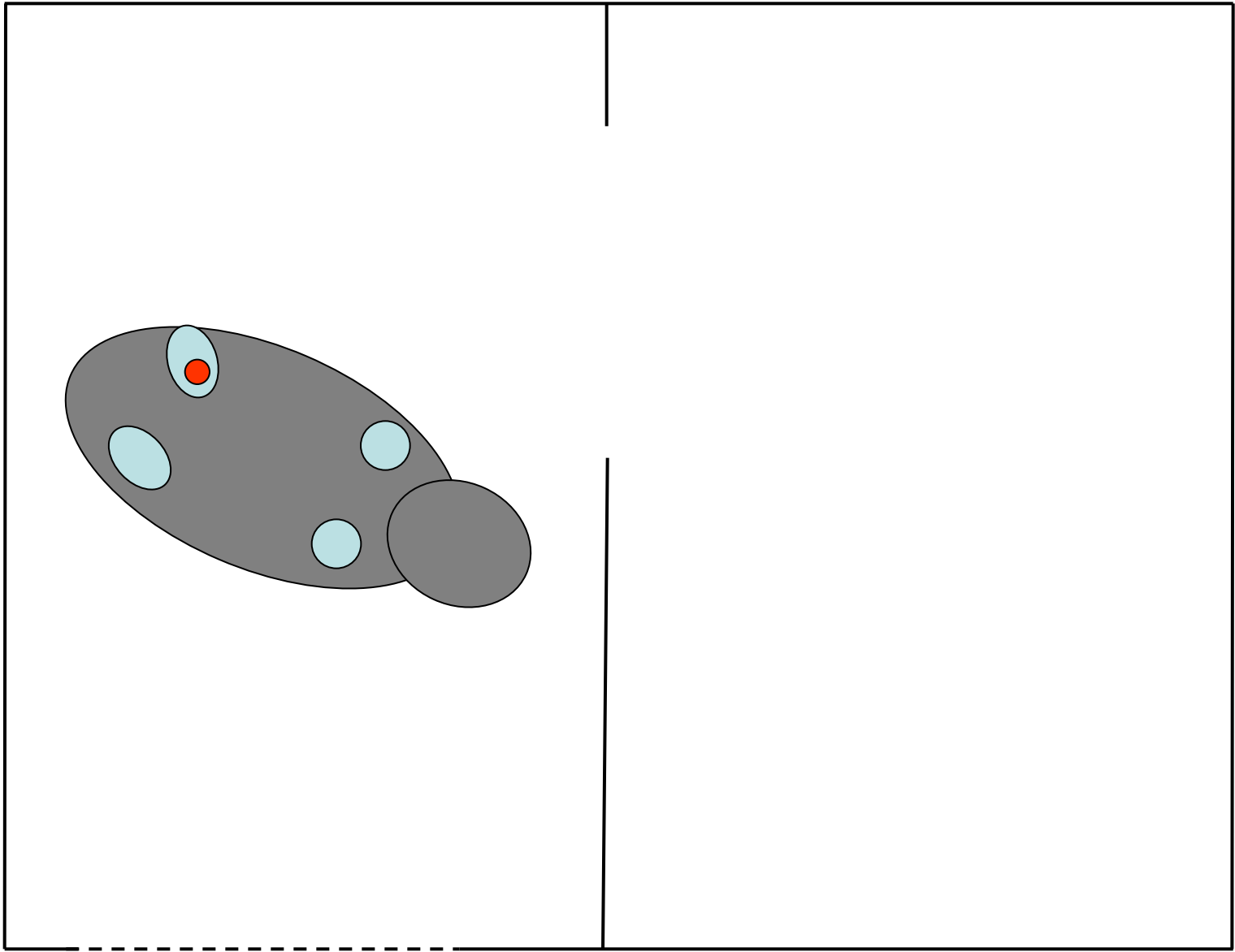
- Micro-climate around the foot - Humidity? Bedding?
- Abnormal compression - Short turning circle?
- (Abnormal position of the leg - dietary minerals?)
- (Poor horn quality - biotin?)

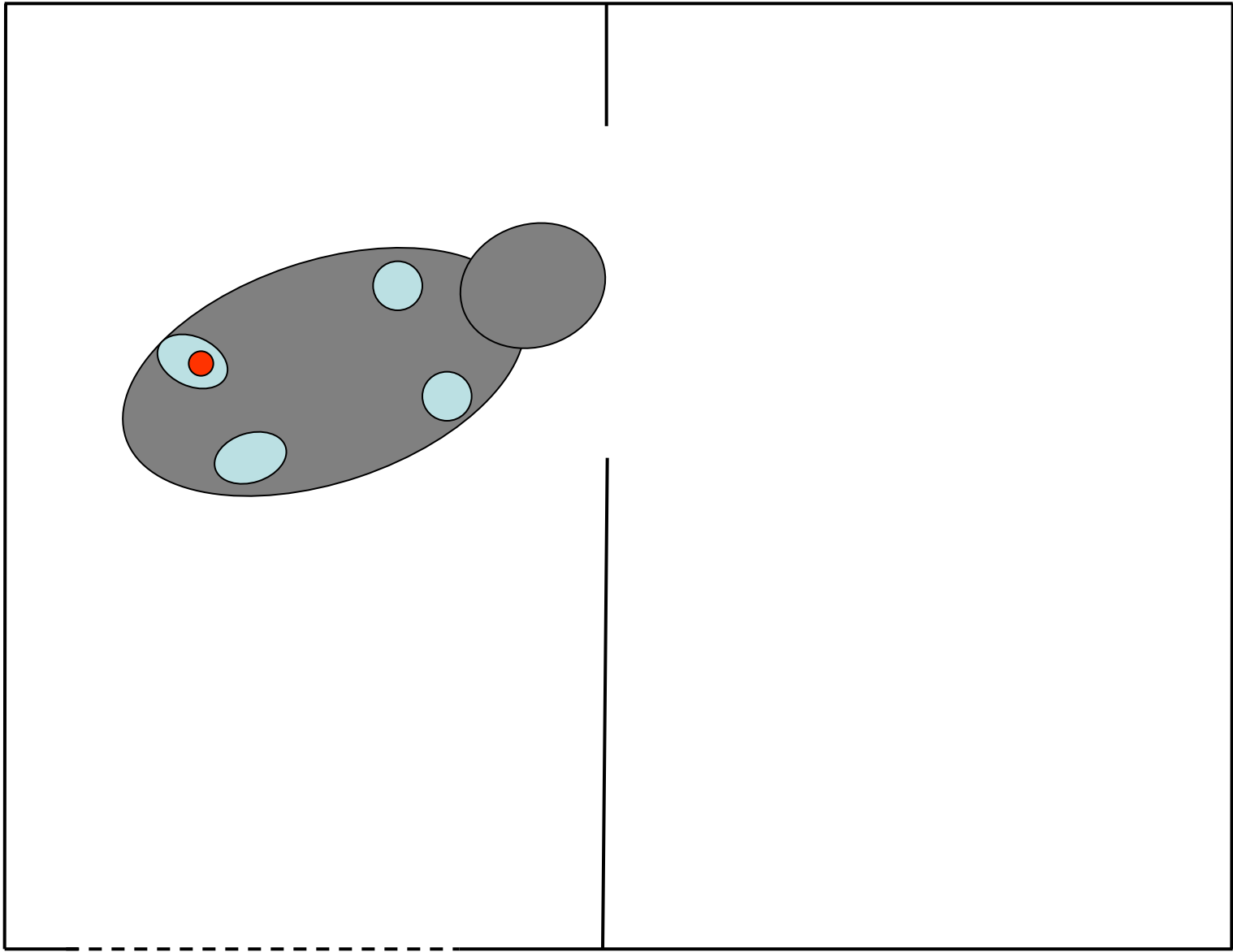


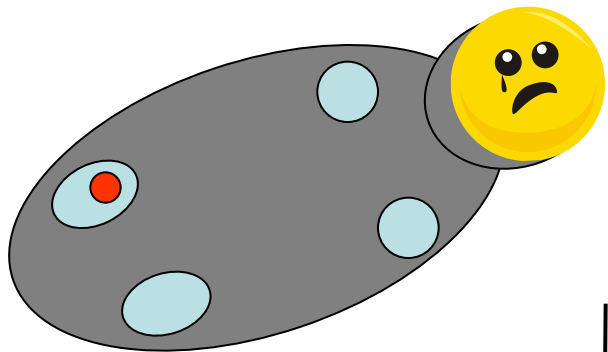














Compression \longrightarrow necrosis

Decompression (pedicure)

Infection \longrightarrow fistle

*Wide opening, flushing
(antibiotics)*



Anesthesia

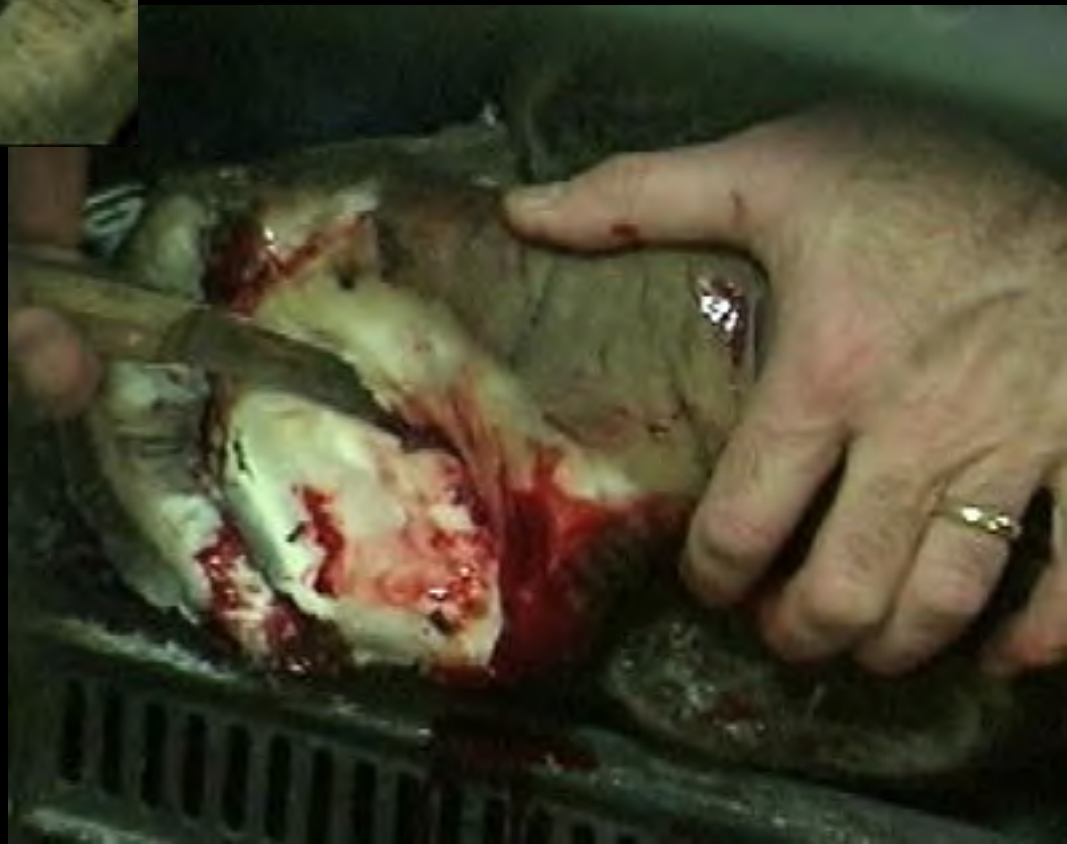

- 24 hours no food
- 15 hours no water
- 1.5 – 1.7 ml Immobilon L.A.* (medial side front leg)
- 0.1 – 0.2 ml Immobilon L.A. i.v. suppl. doses
- 5 l. oxygen flow in nasal cavity
- Pulse-oxymetry monitoring
- Reversal Naltrexone i.v.
- Air-inflated cushions

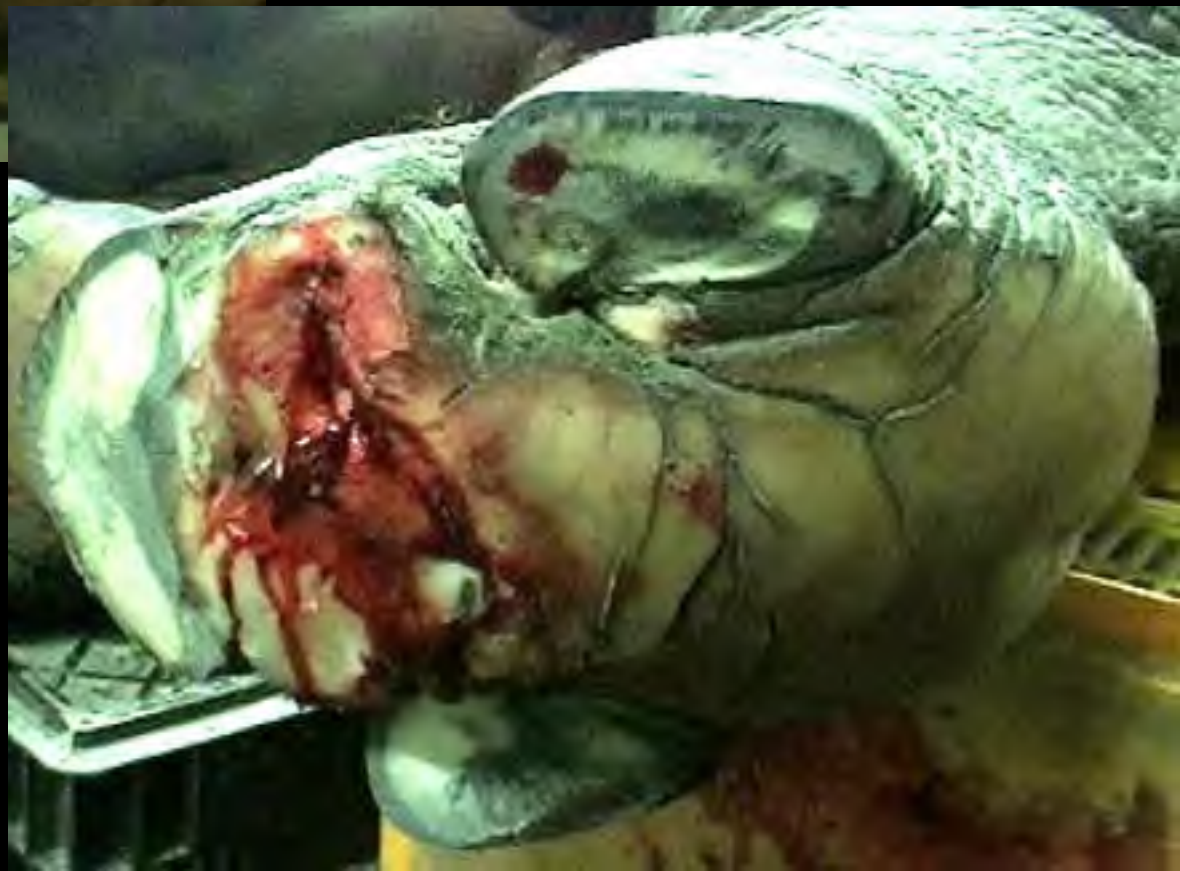* Immobilon: 2.45 mg etorphine + 10 mg acepromazine per ml



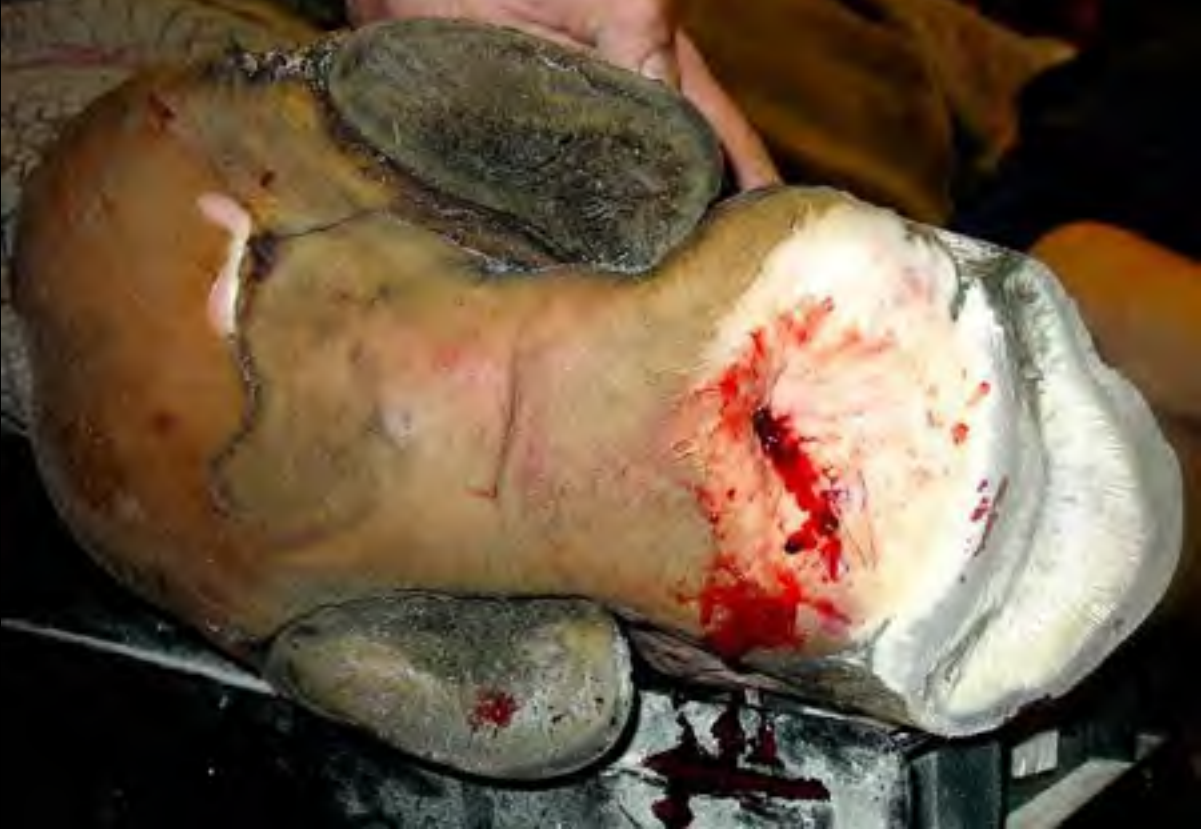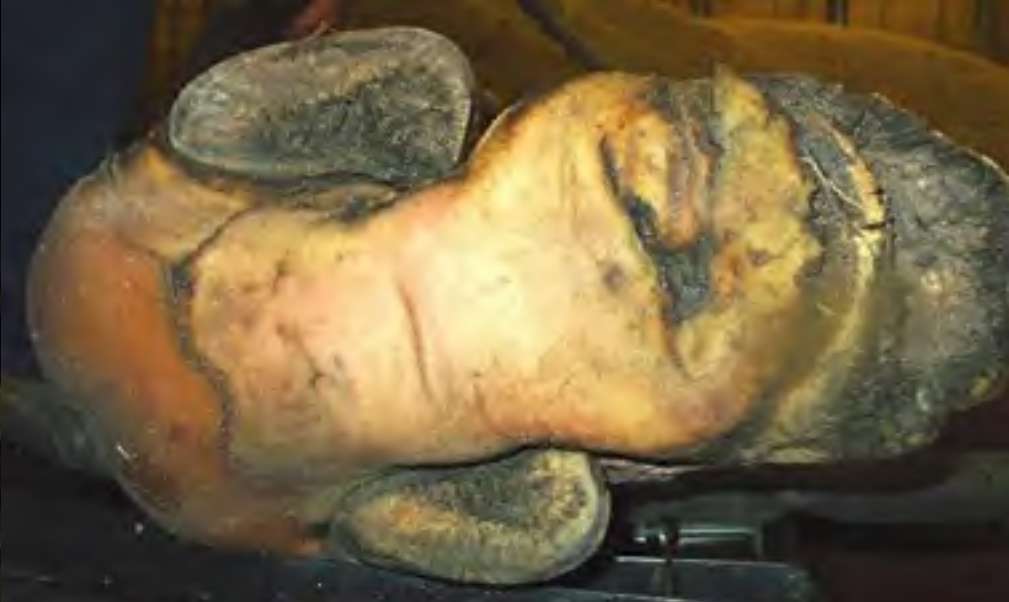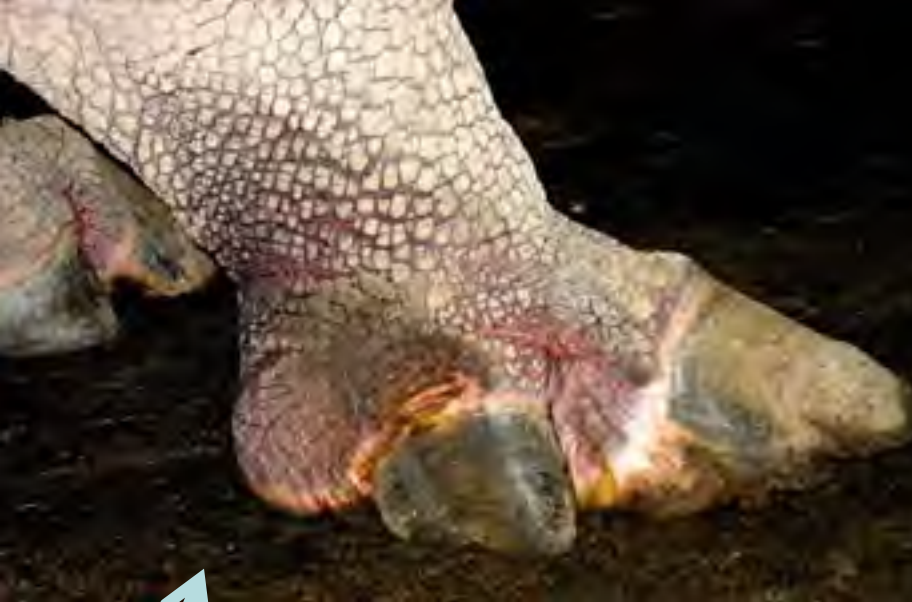Air-inflated positioning bags



Right 2001



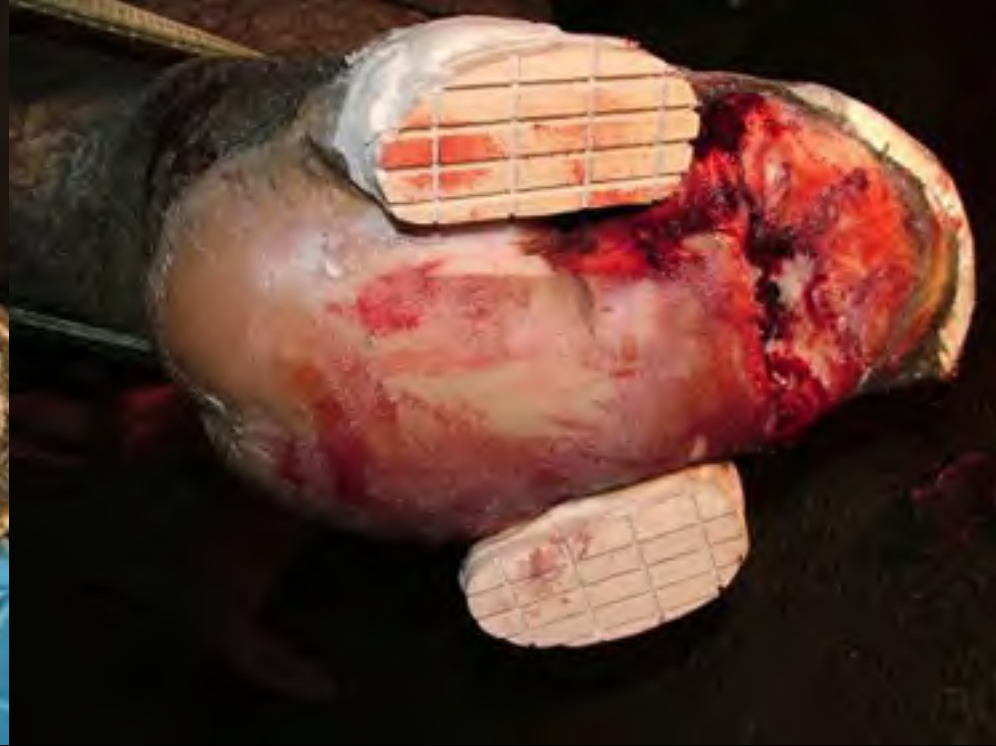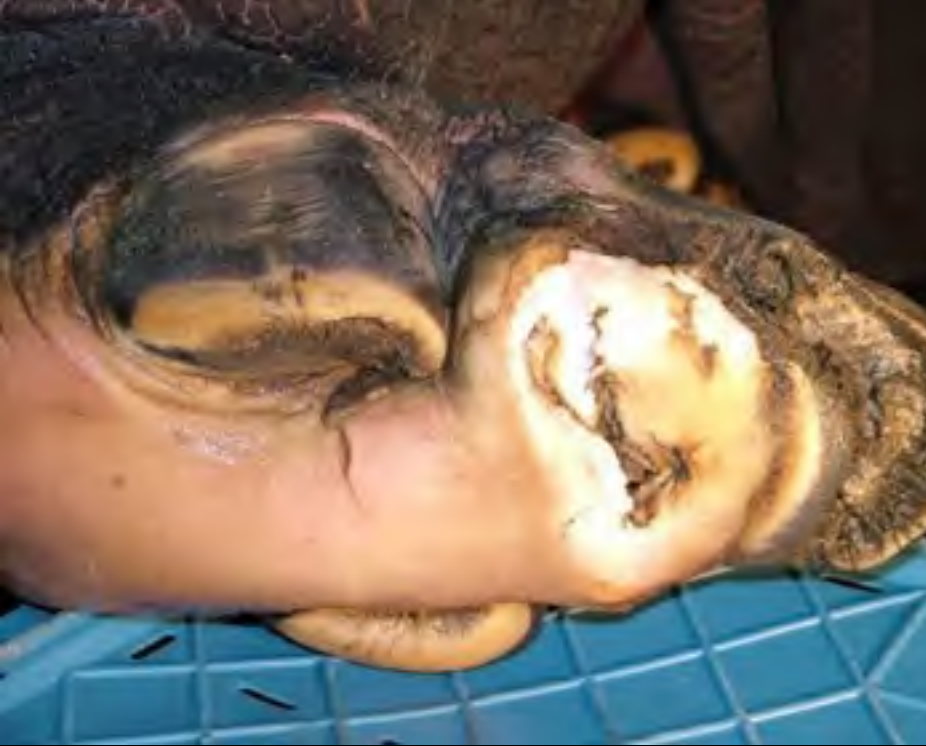Left 2001



Rubber floor

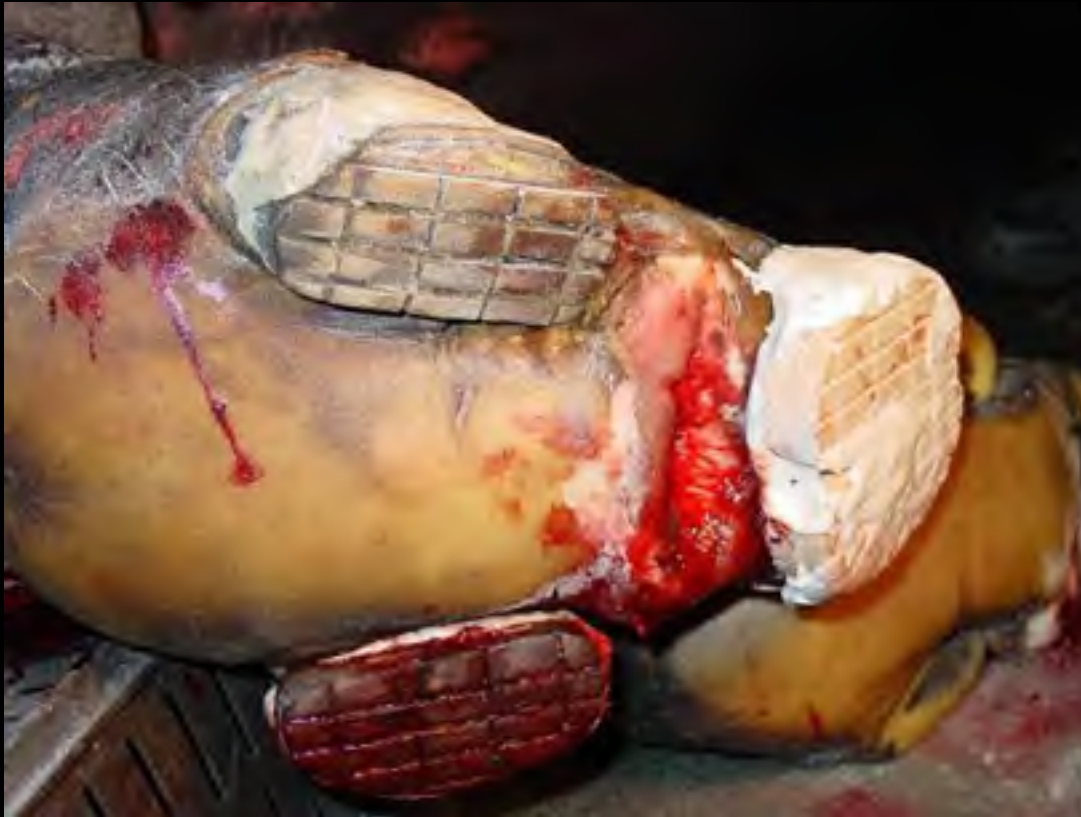Right

21-03-2002



Right

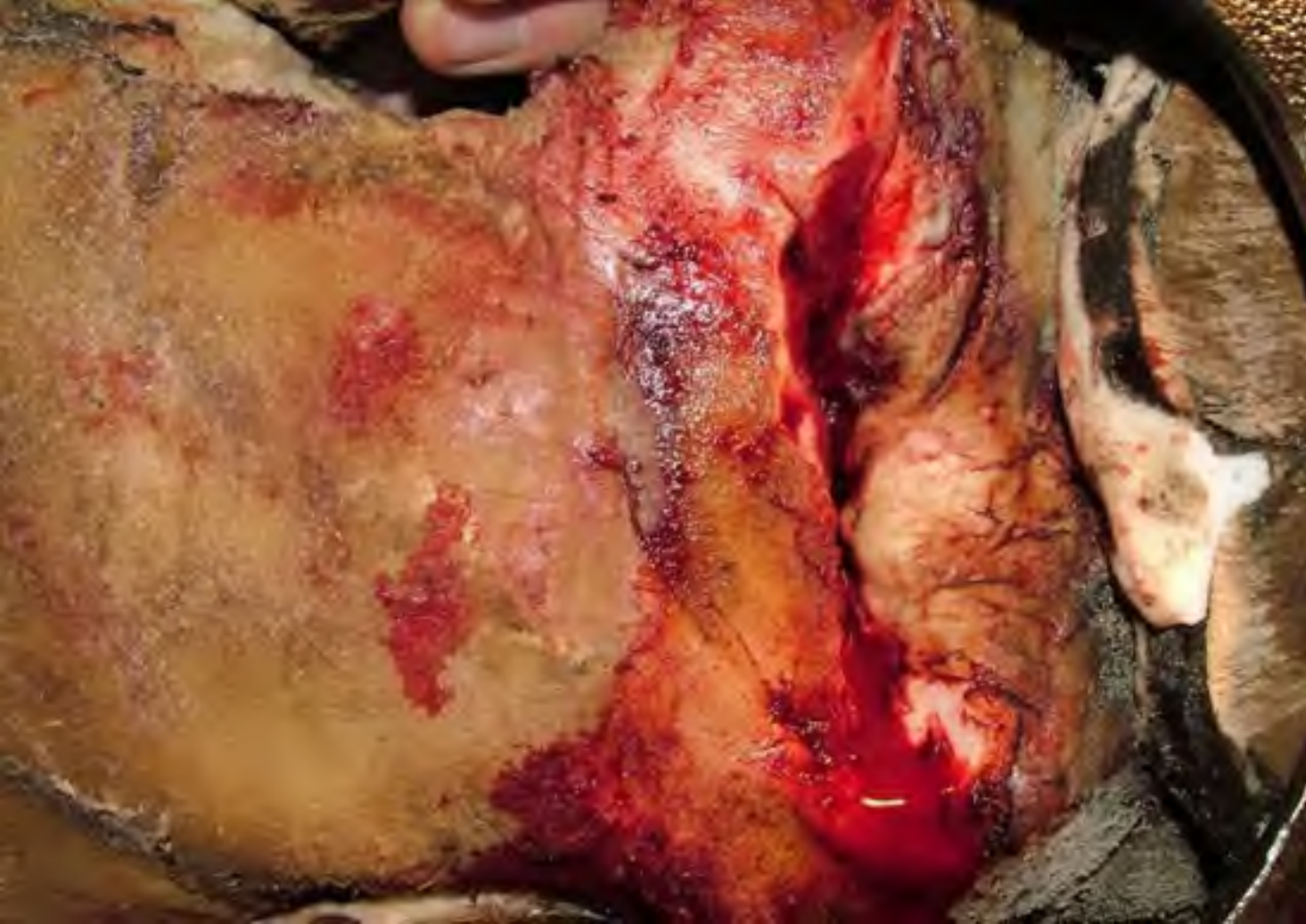19-11-2004



Right

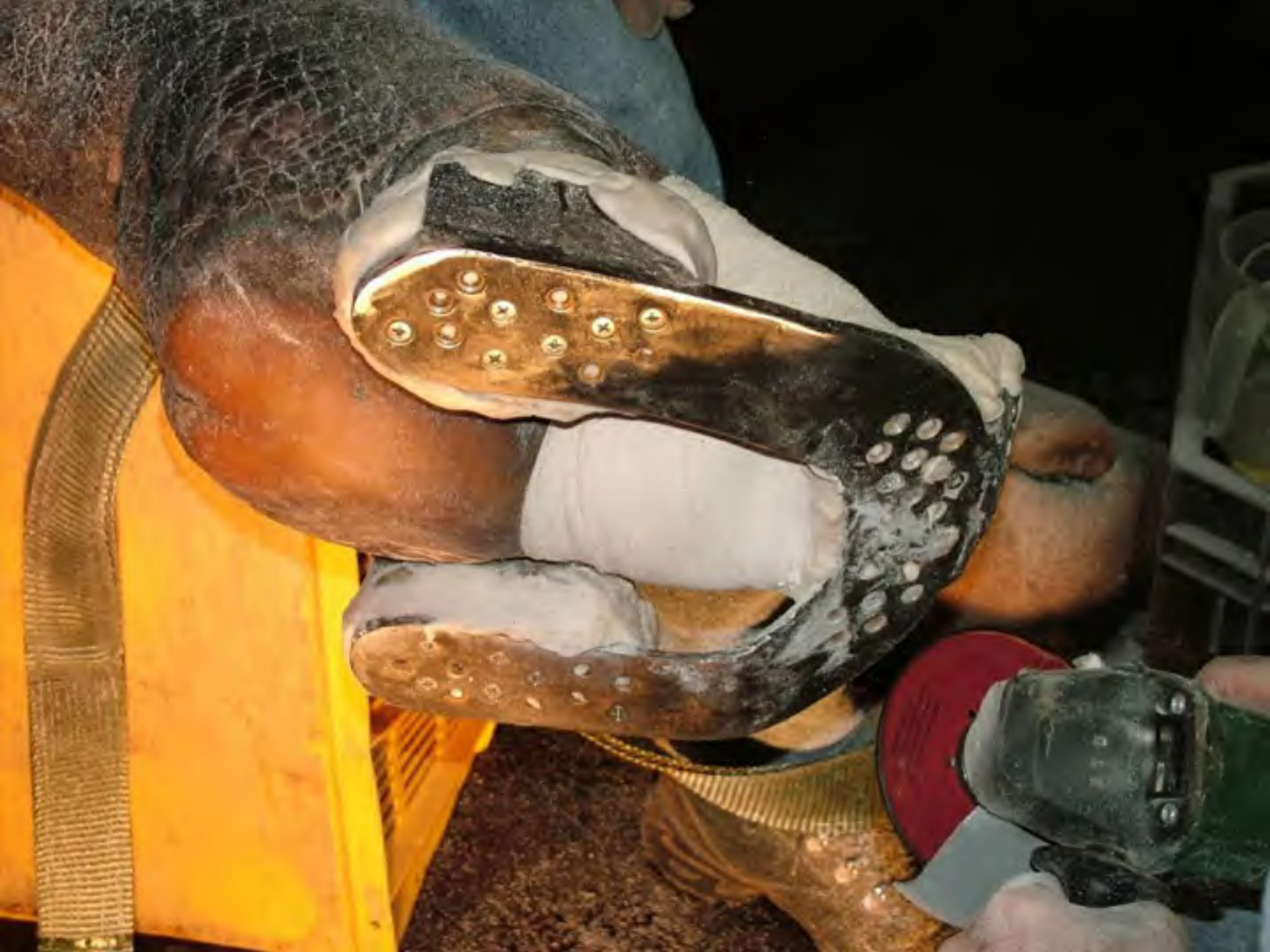25-11-2004





Right

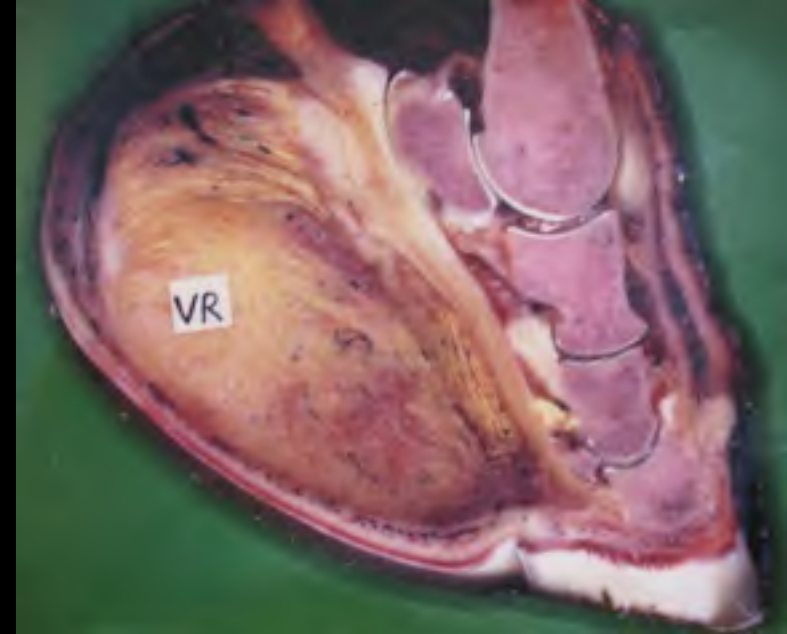
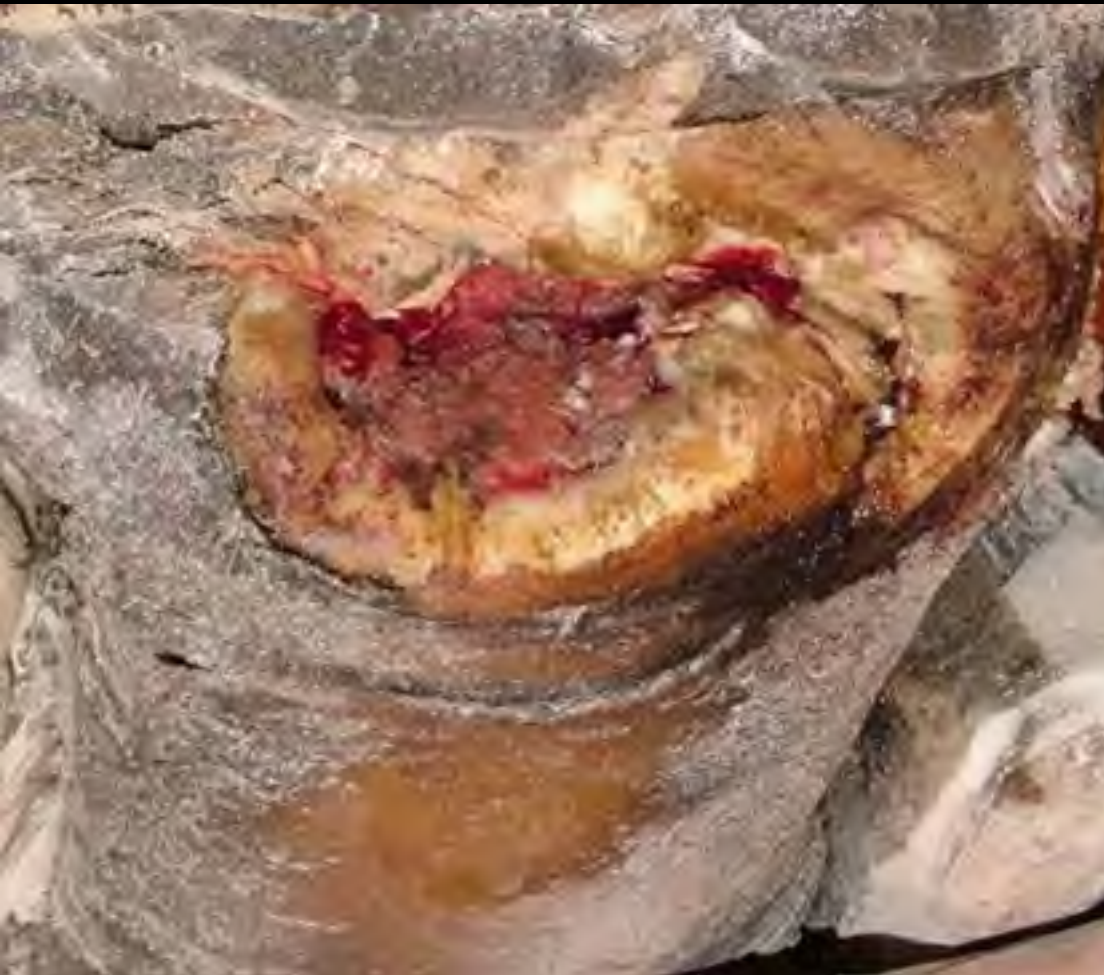3-12-2004





Right

10-12-2004



MAS105DE

ACTISORB[®] Silver 220


Silber-Aktivkohle-Wundauflage

Pansement au Charbon Actif et Argent

Medicazione in Carbone Attivo con Argento

Actief Koolstofverbond met Zilver

10 / 10.5cm x 10.5cm



Für infizierte Wunden –
breite antibakterielle Wirkung

Pour les plaies infectées –
large spectre anti-microbien

Per ferite infette –
large spettro antimicrobico

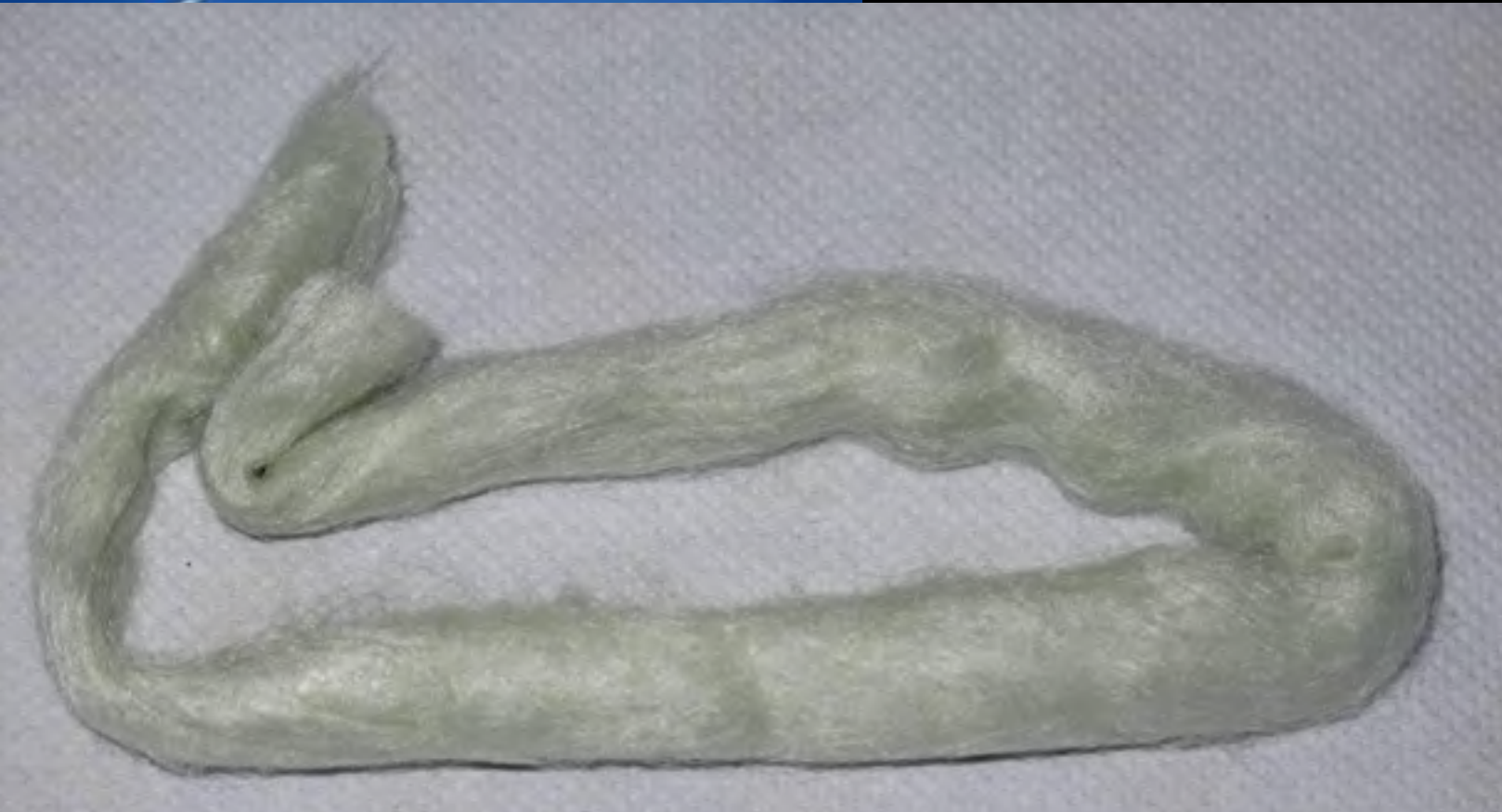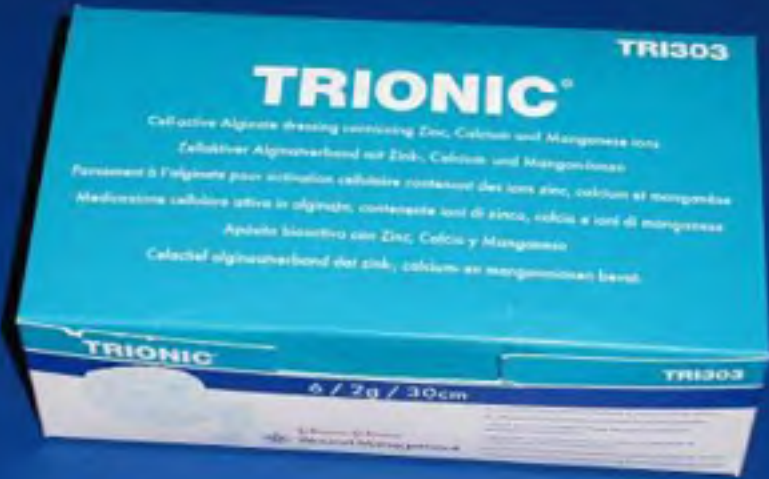Voor geïnfecteerde wonden –
breed antibacterieel spectrum

 **Johnson & Johnson**
Wound Management

PER INFORMAZIONI
LA PIÙ AVANZATA
ATTORNO WOUND CARE
VITACARBONE ATTIVO

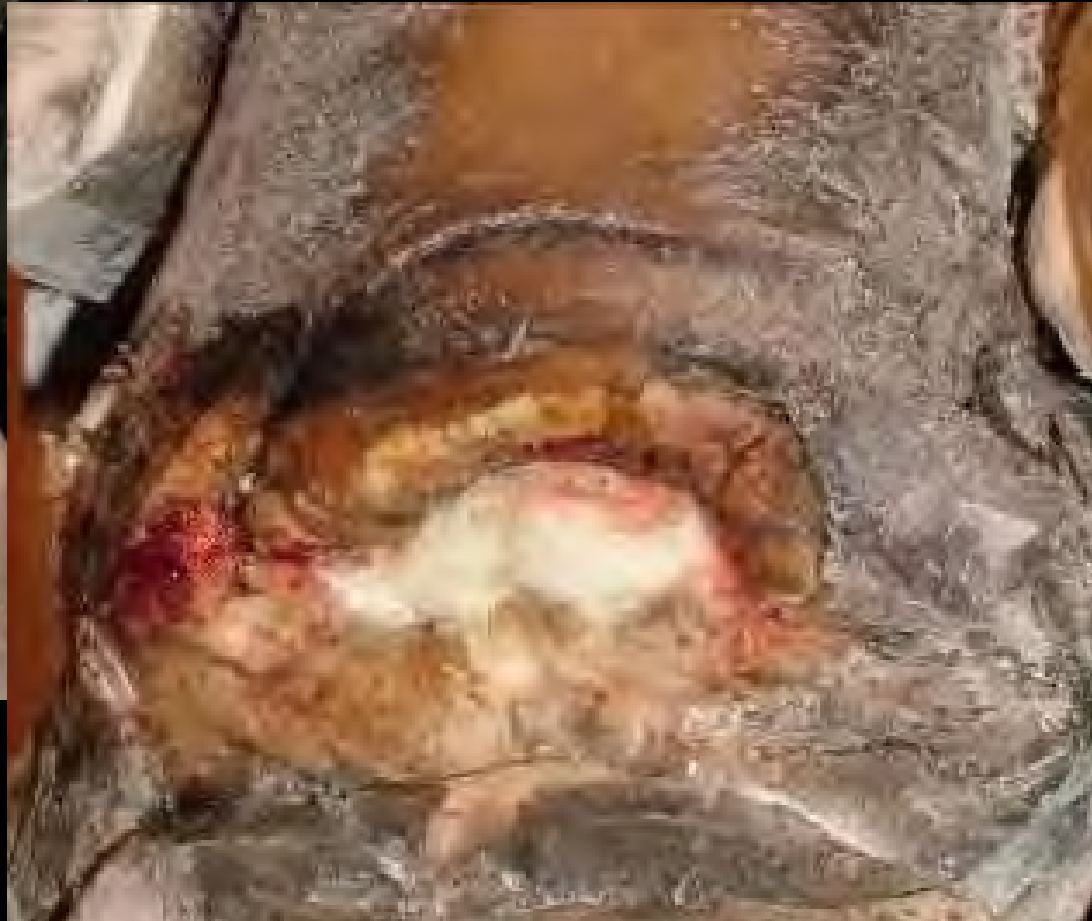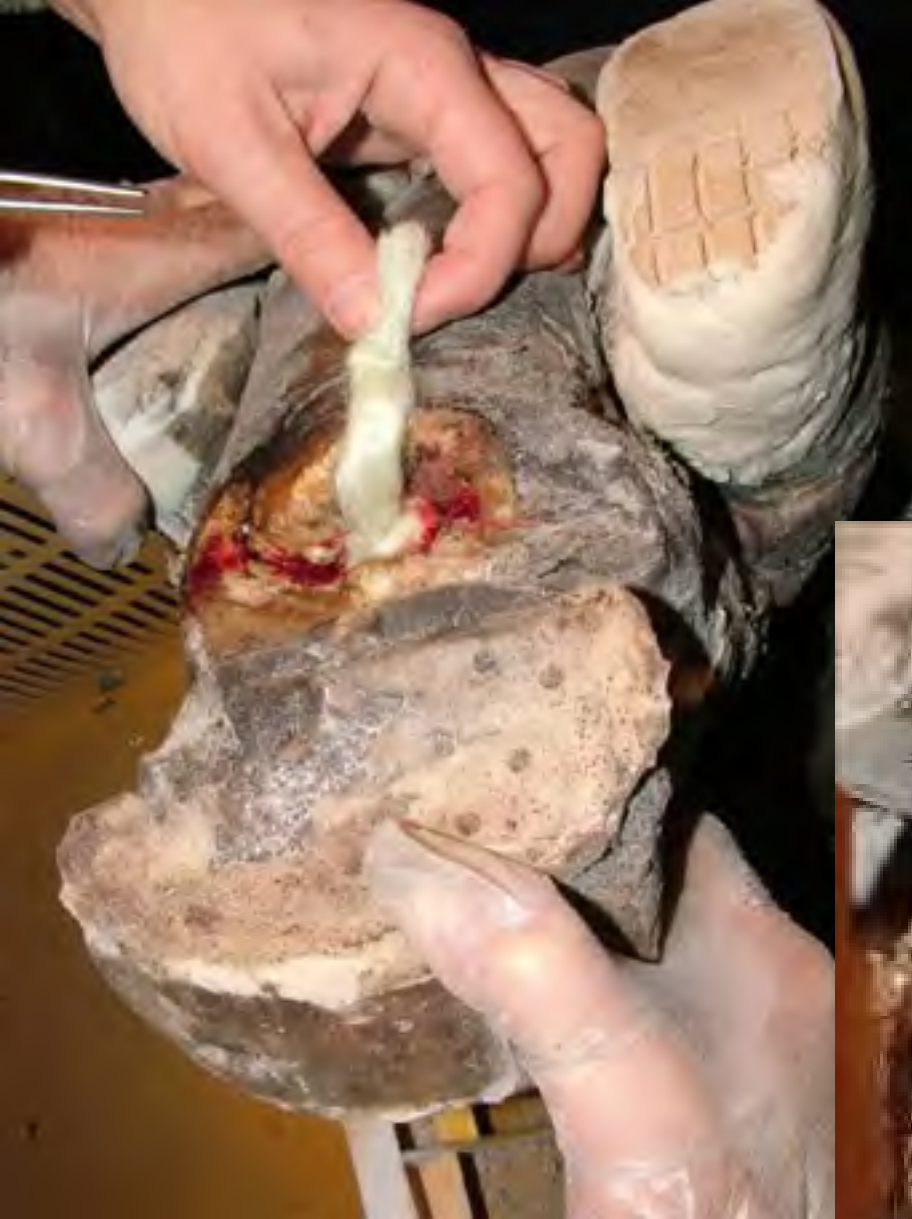Antibacterial:
silver + active carbon

Dried alginates



Right

10-12-2004





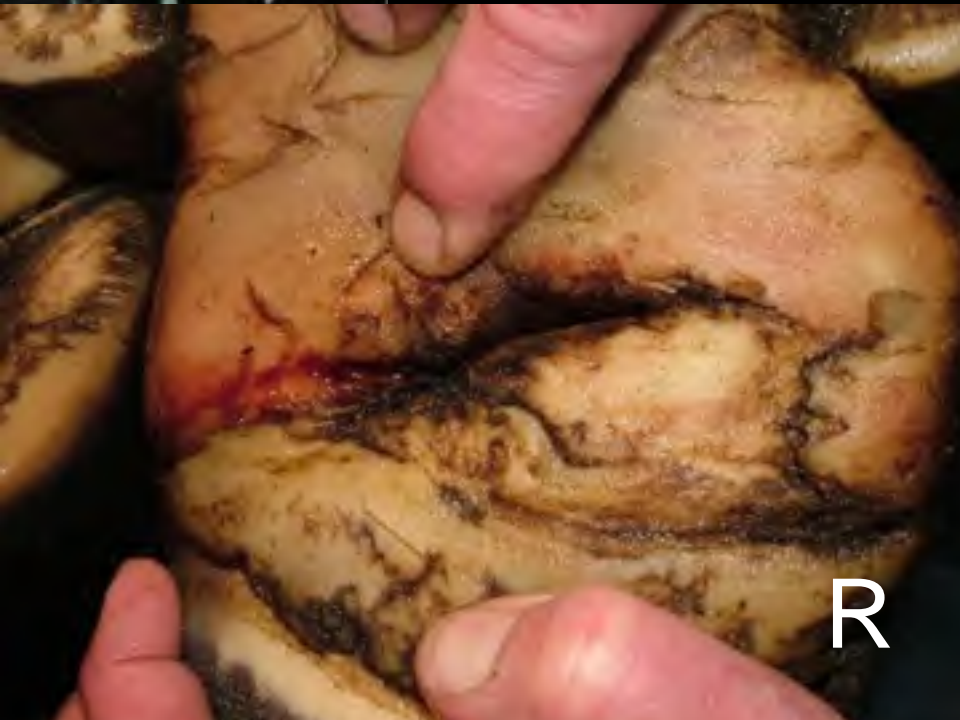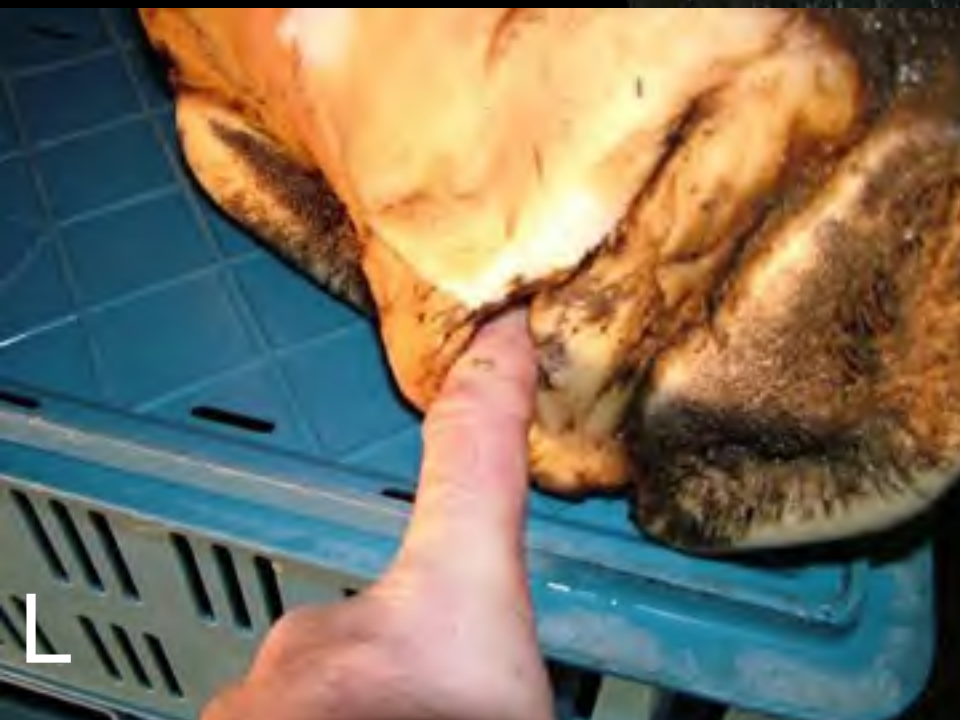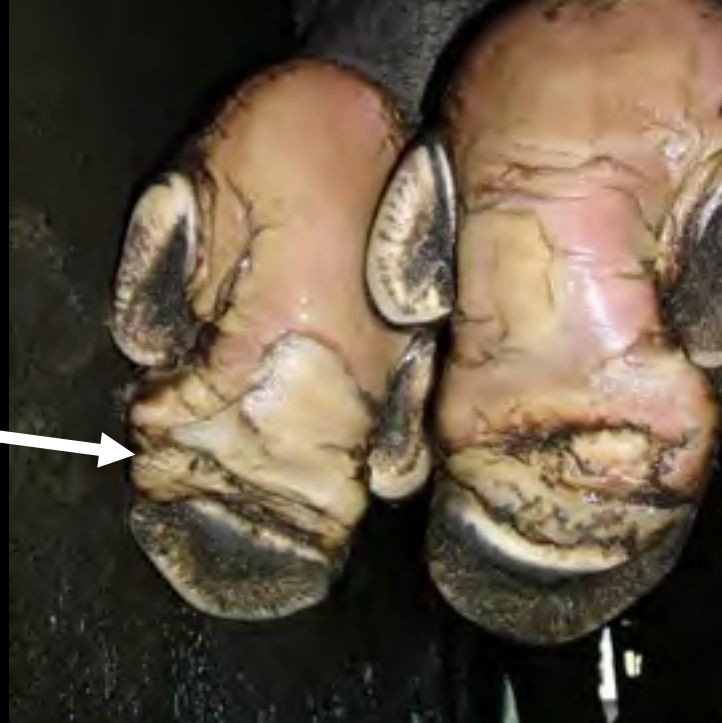Right

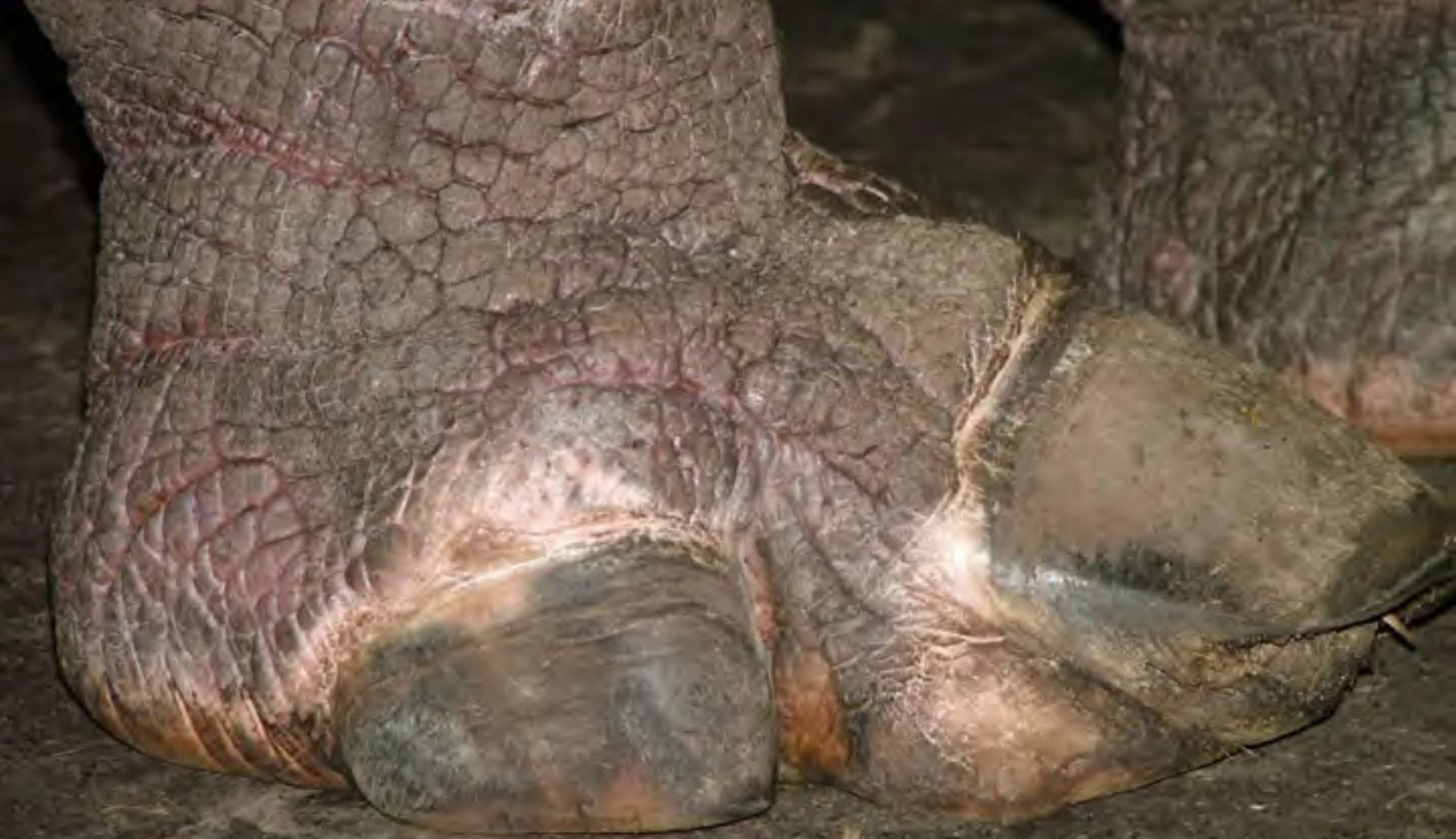17-12-2004



Left

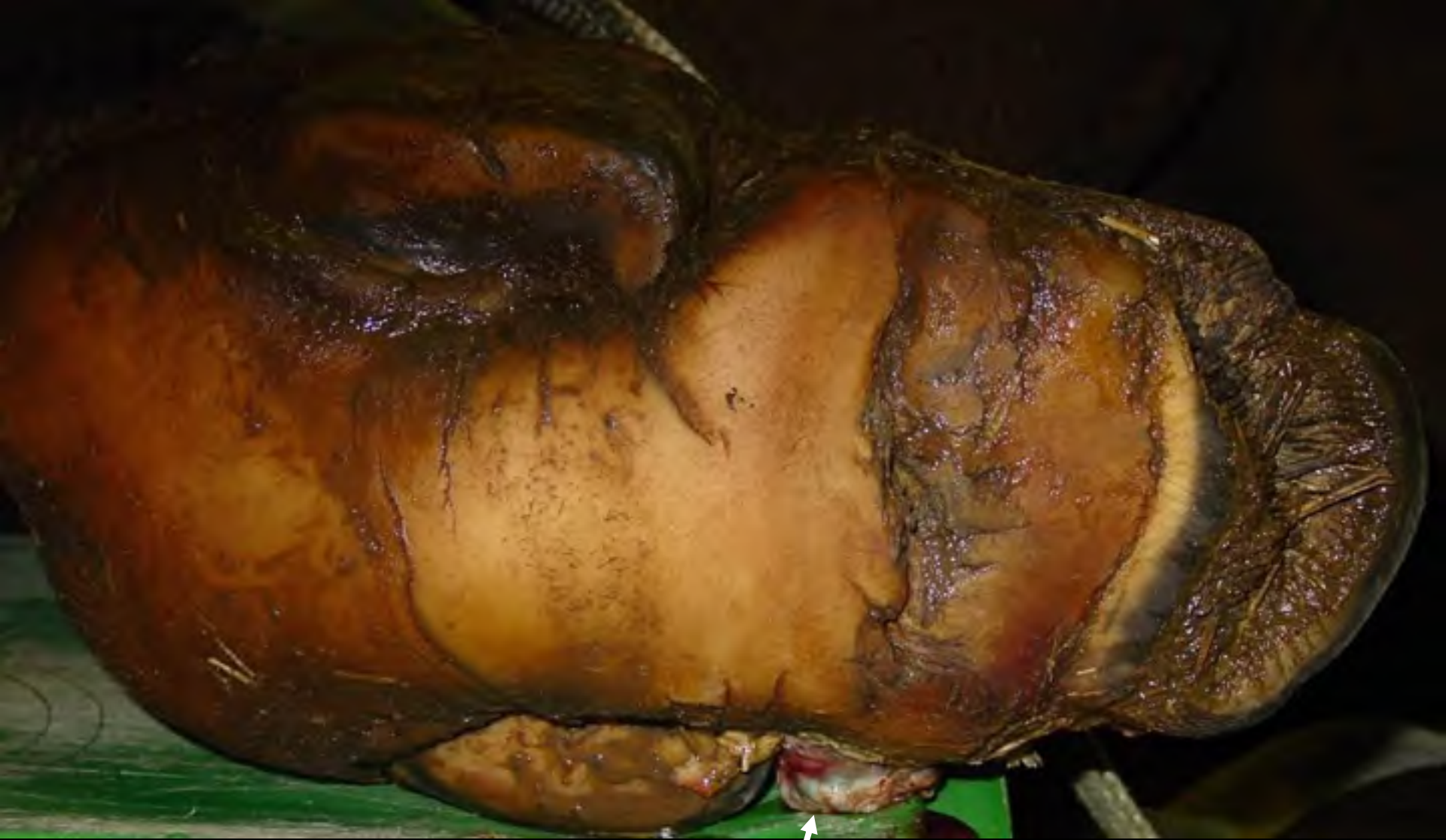4-02-2005





R

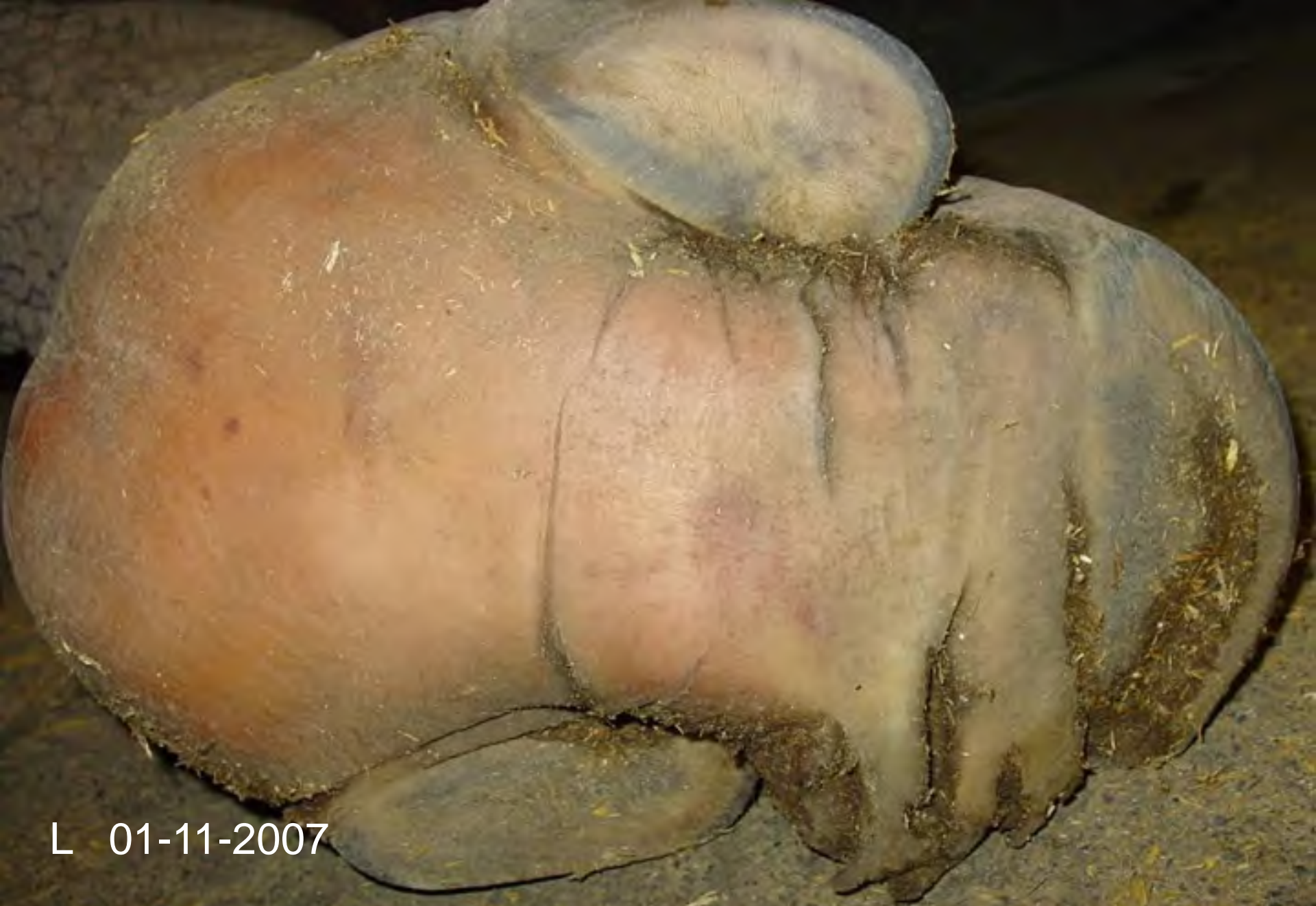



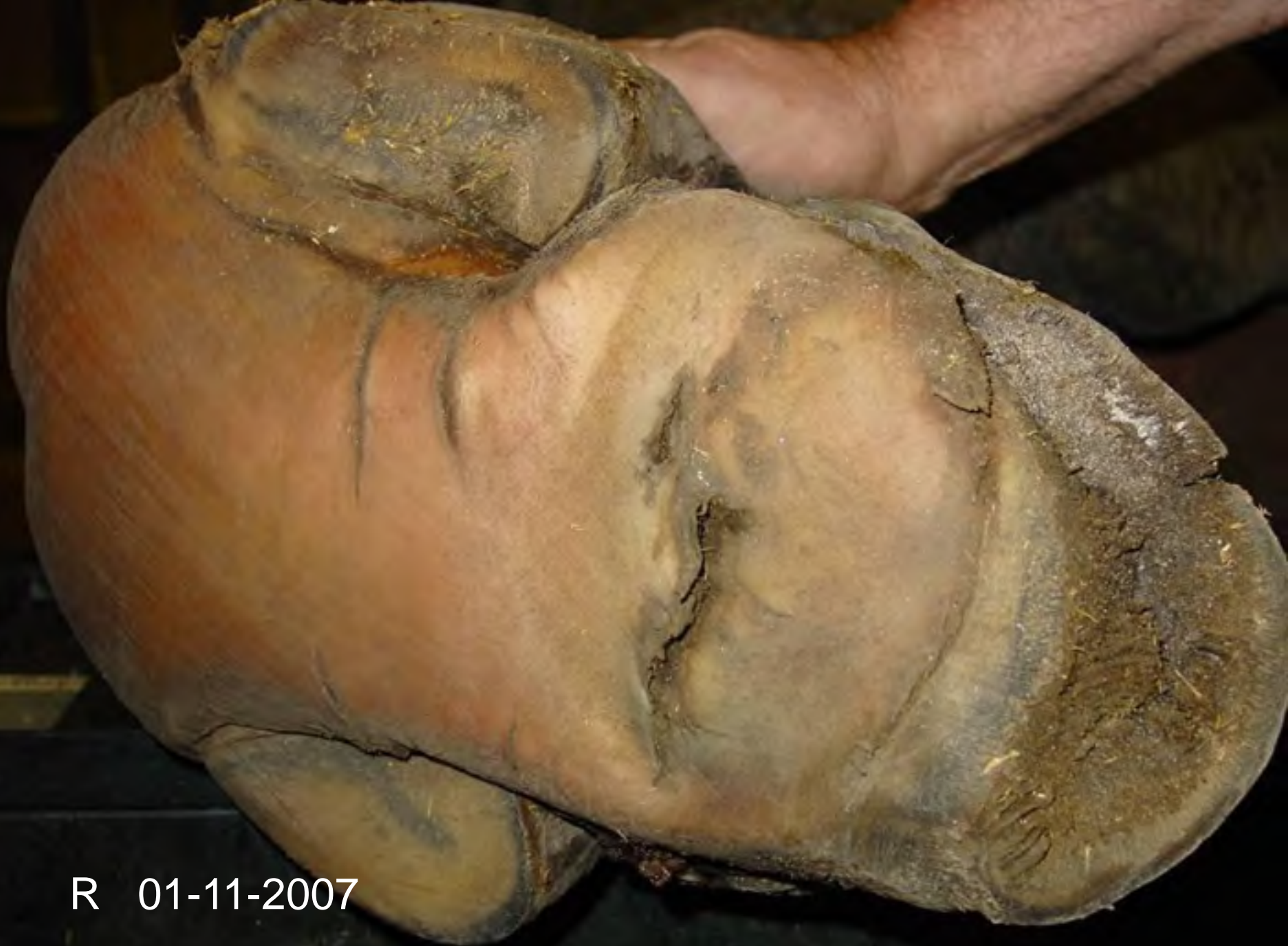R

Fistle to abscess

2007



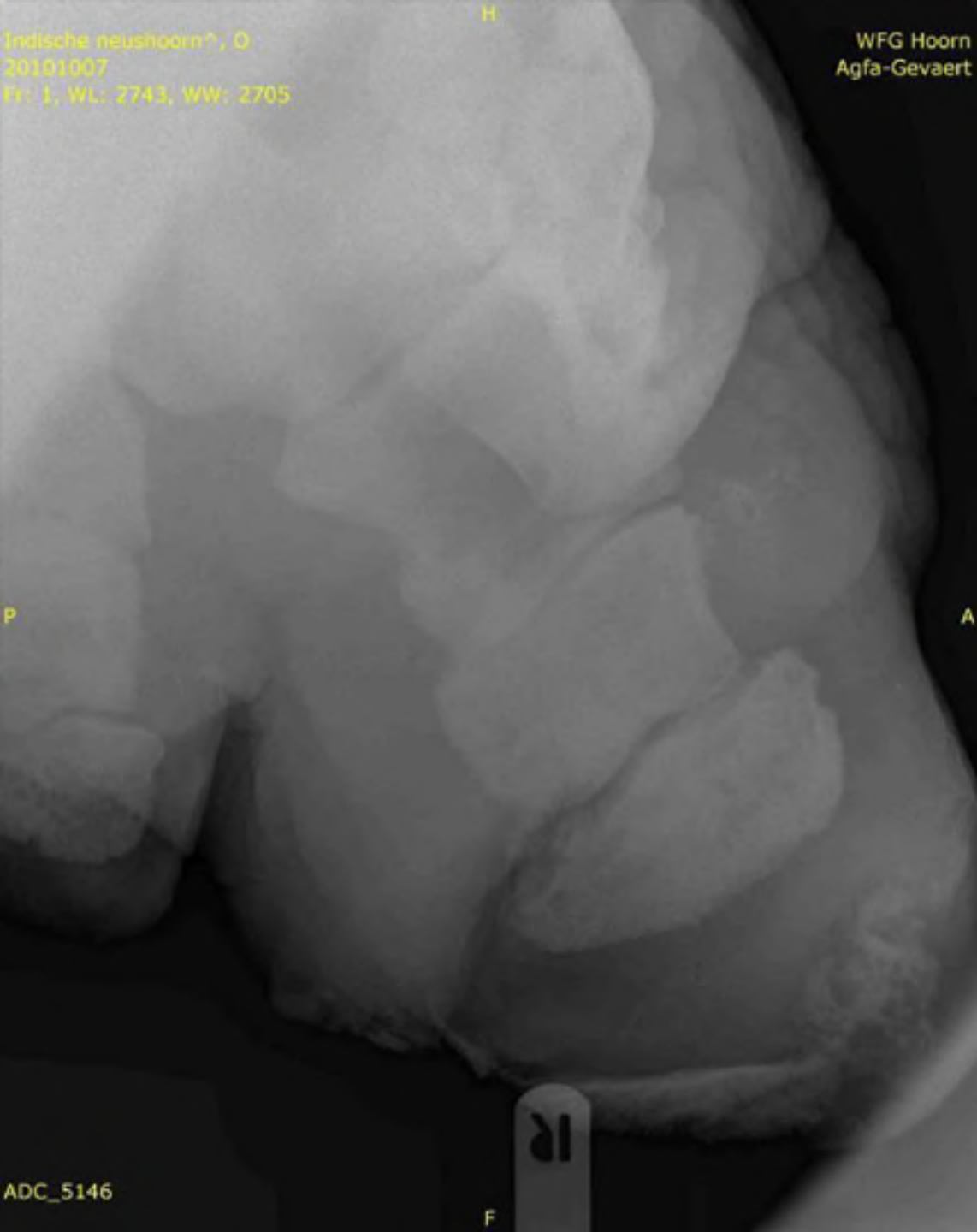
L 01-11-2007



R 01-11-2007

Indische neushoorn?, O
20101007
Fr: 1, WL: 2743, WW: 2705

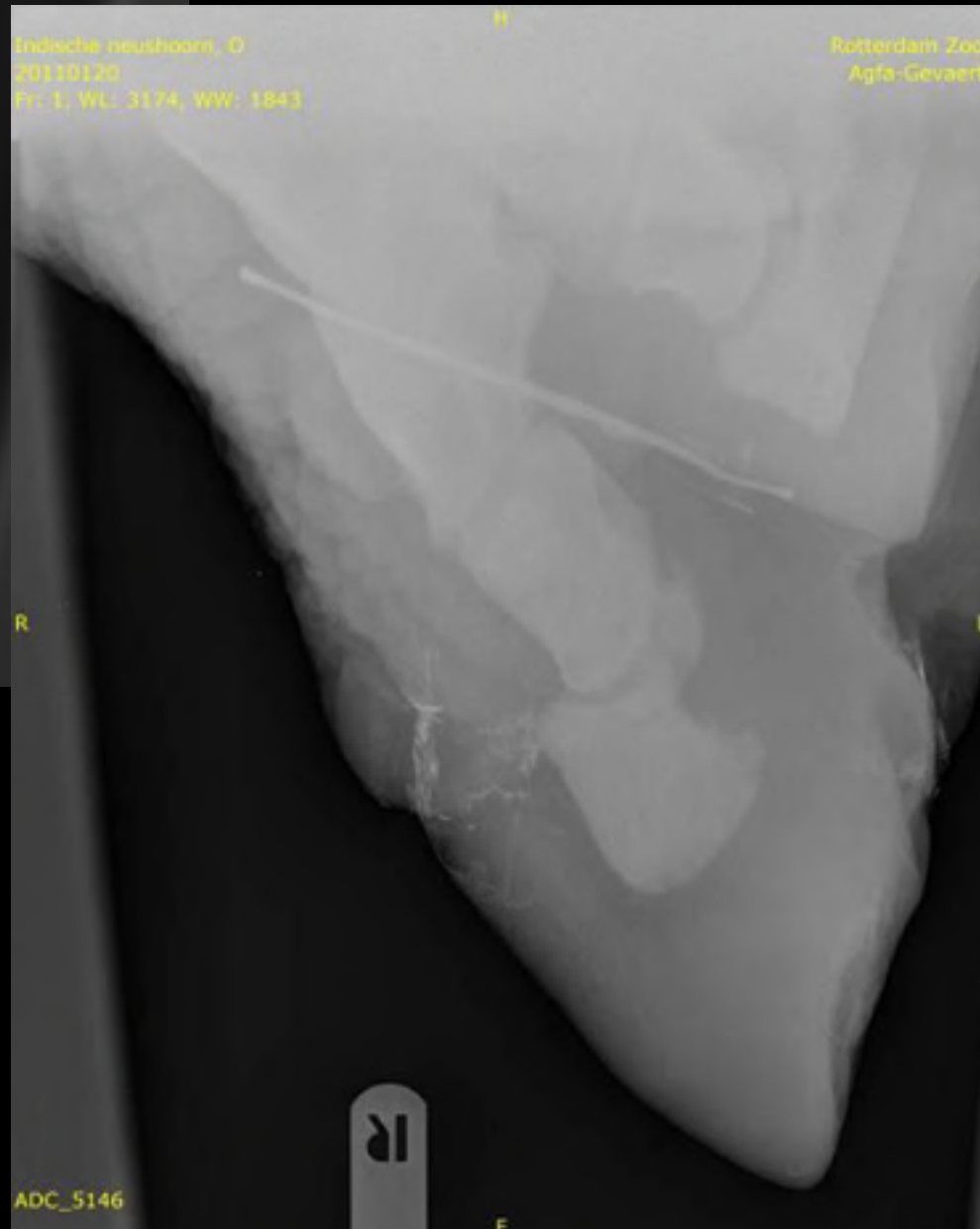
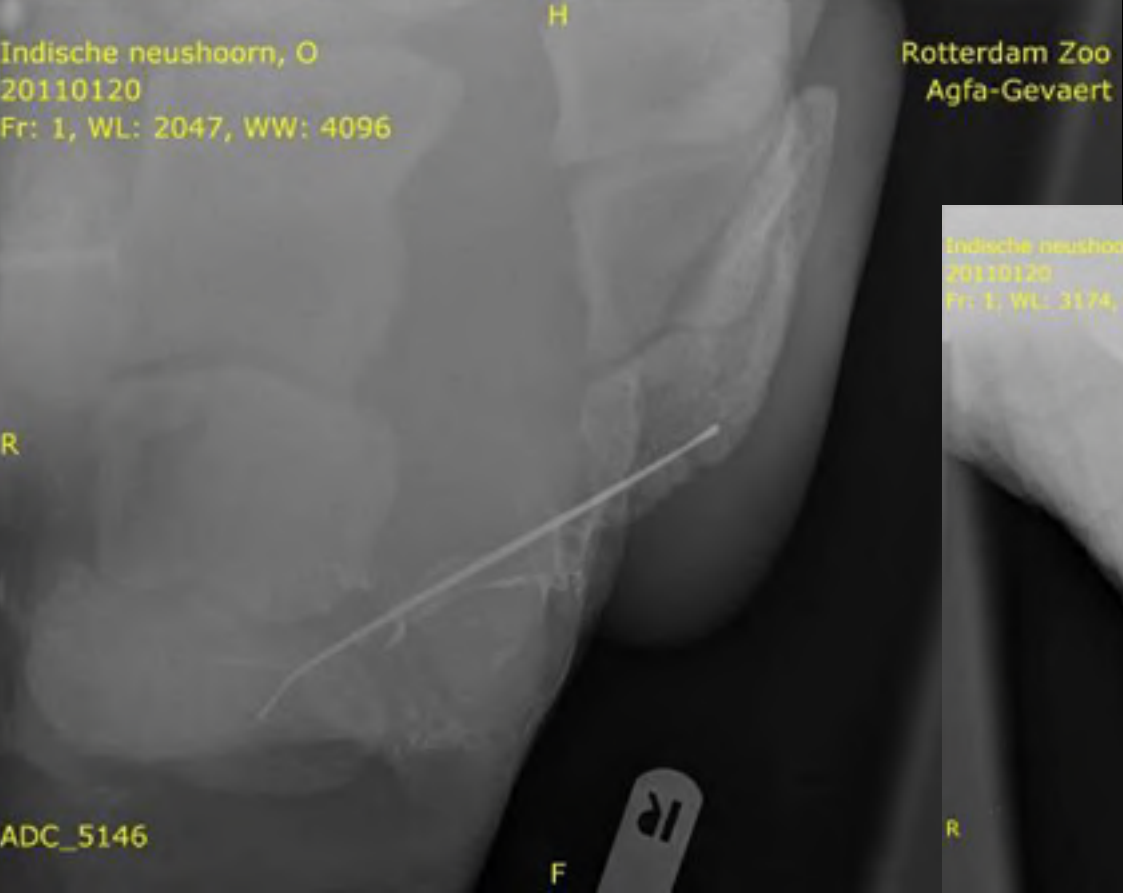
WFG Hoorn
Agfa-Gevaert



20-01-2011

ADC_5146

F



20-01-2011






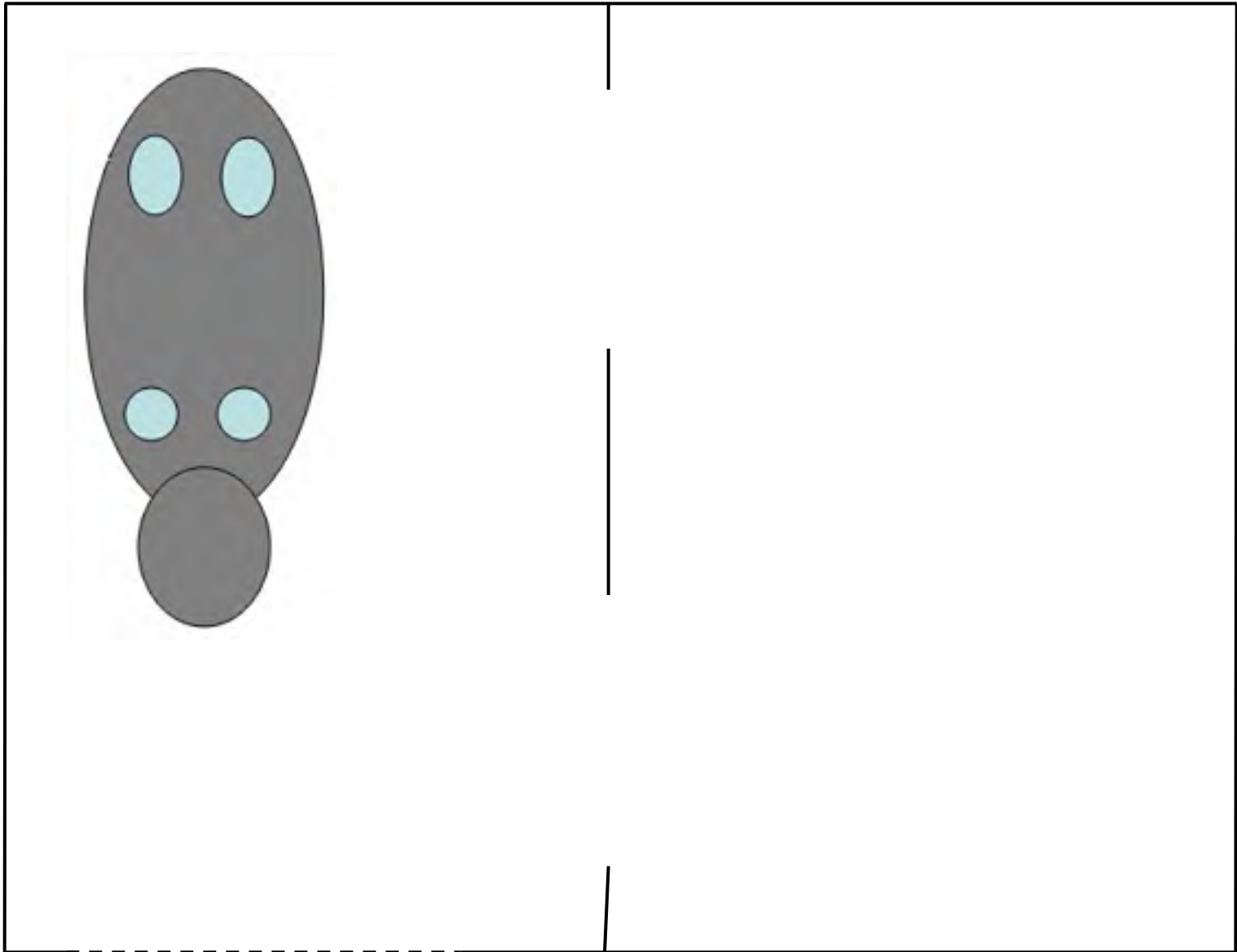


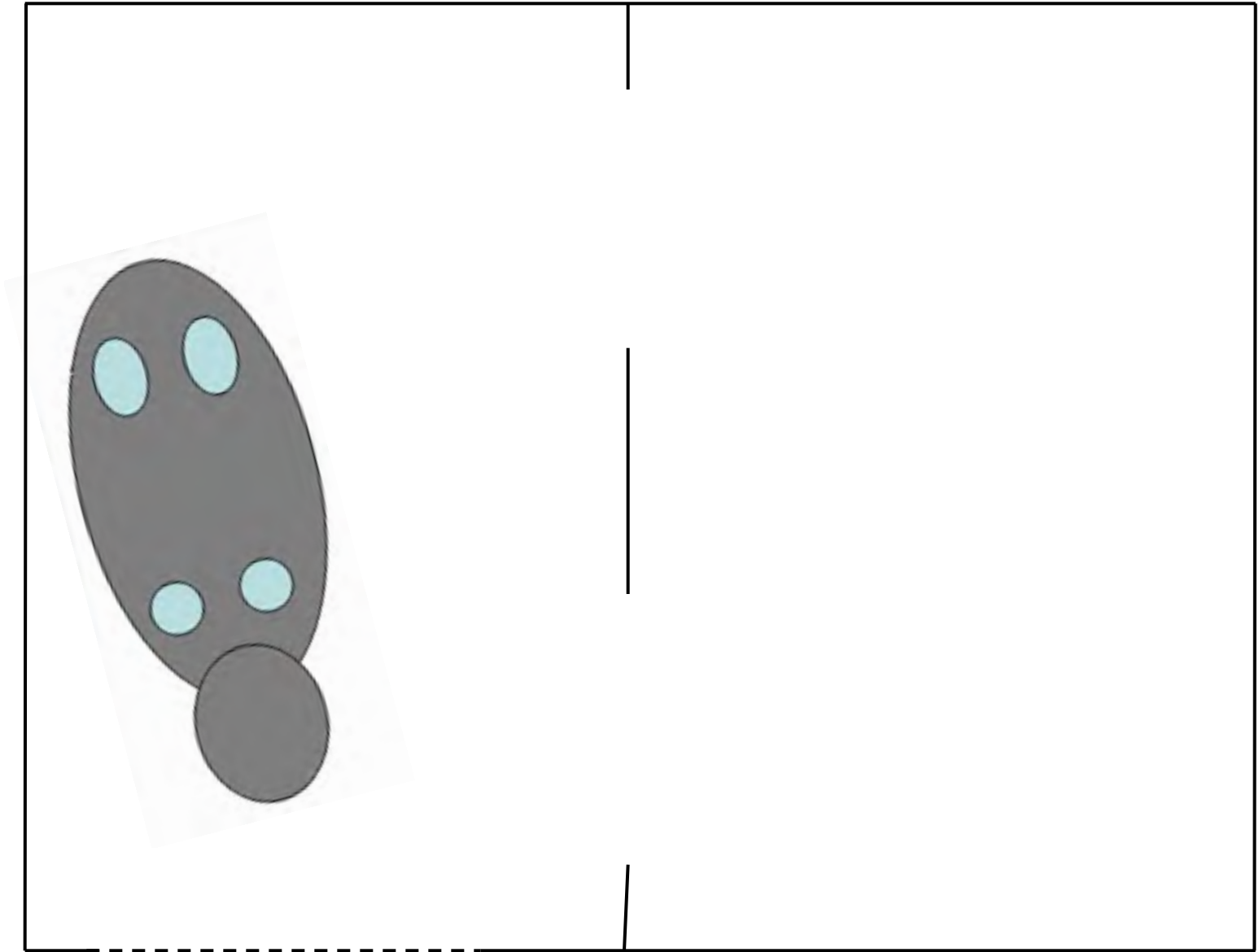


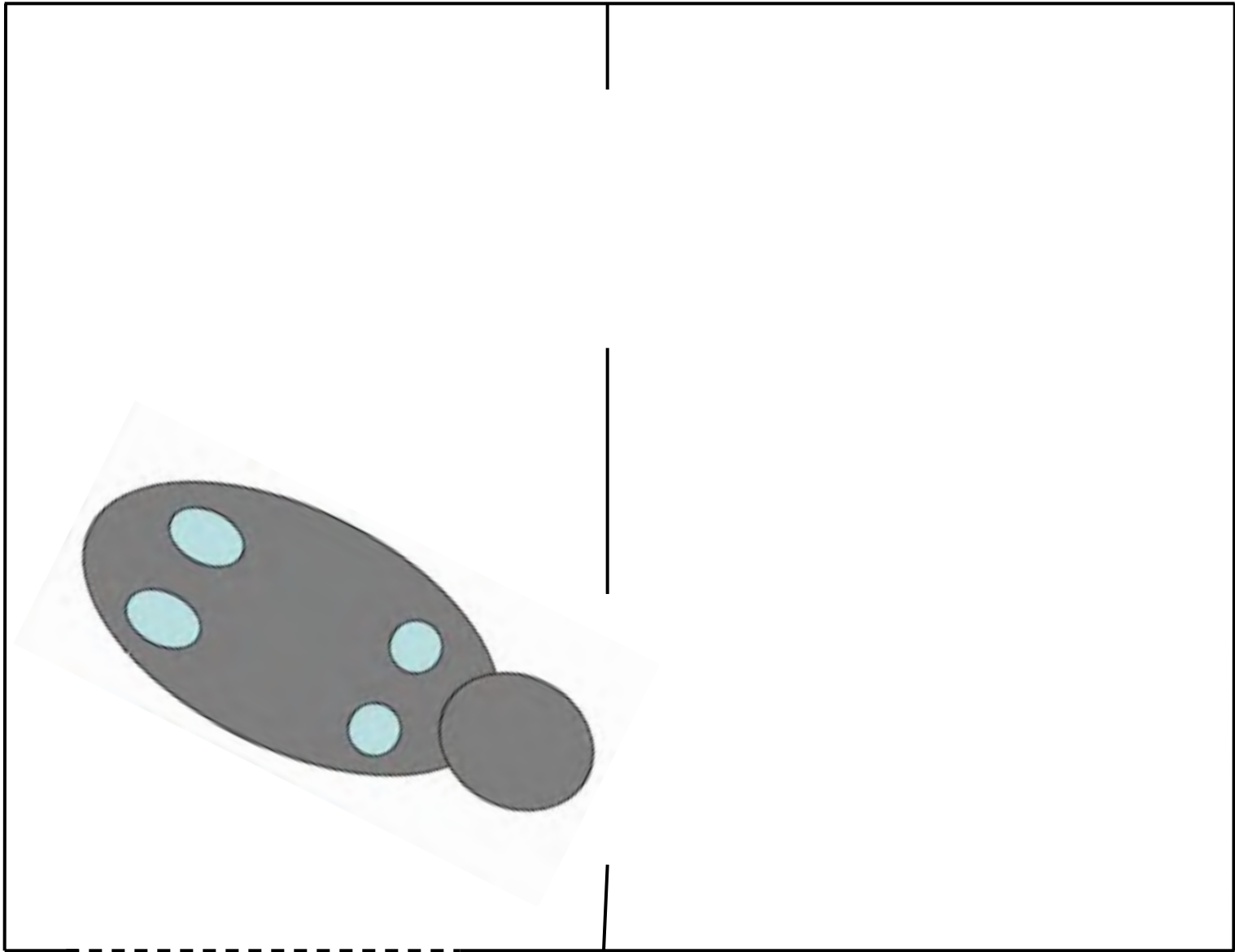


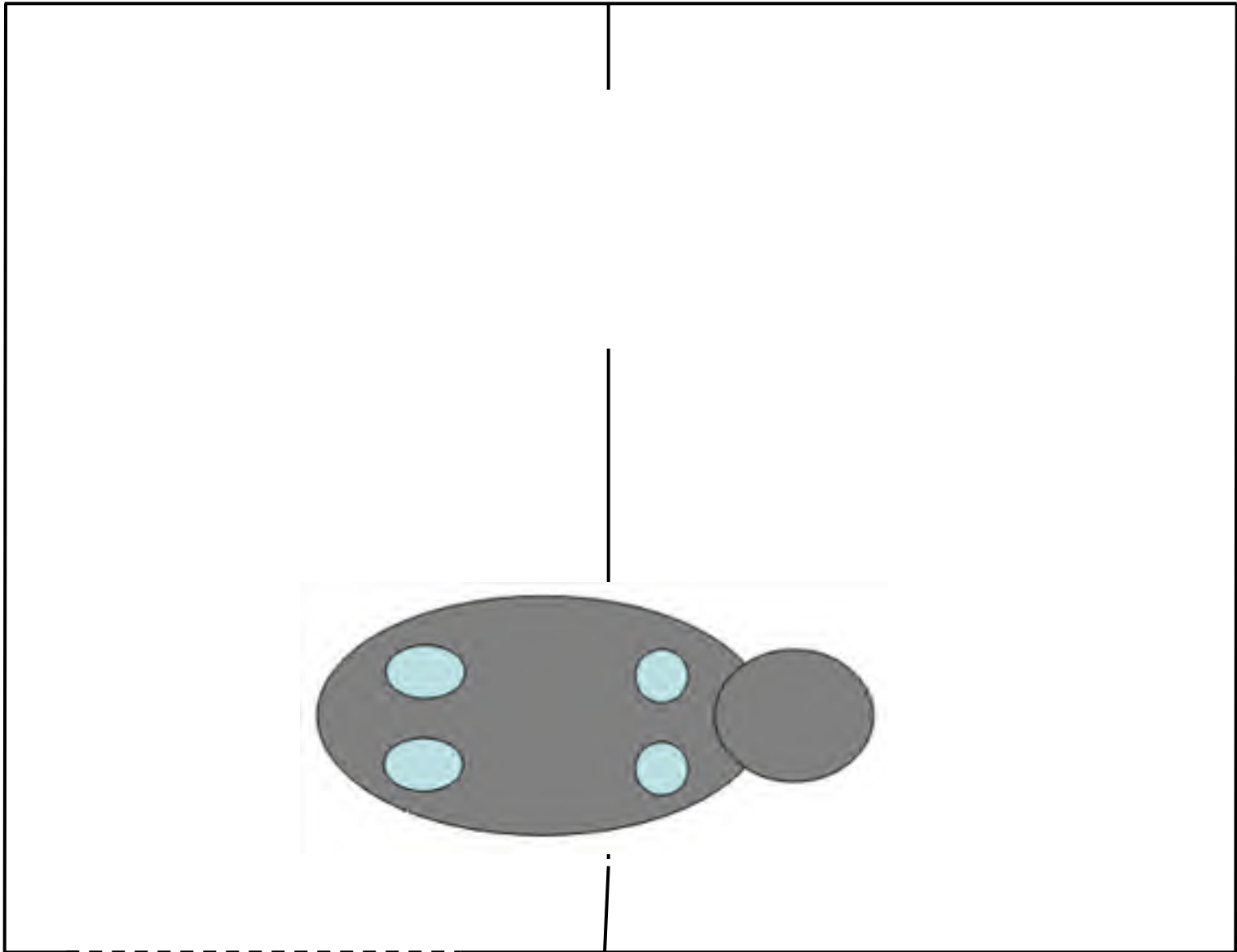


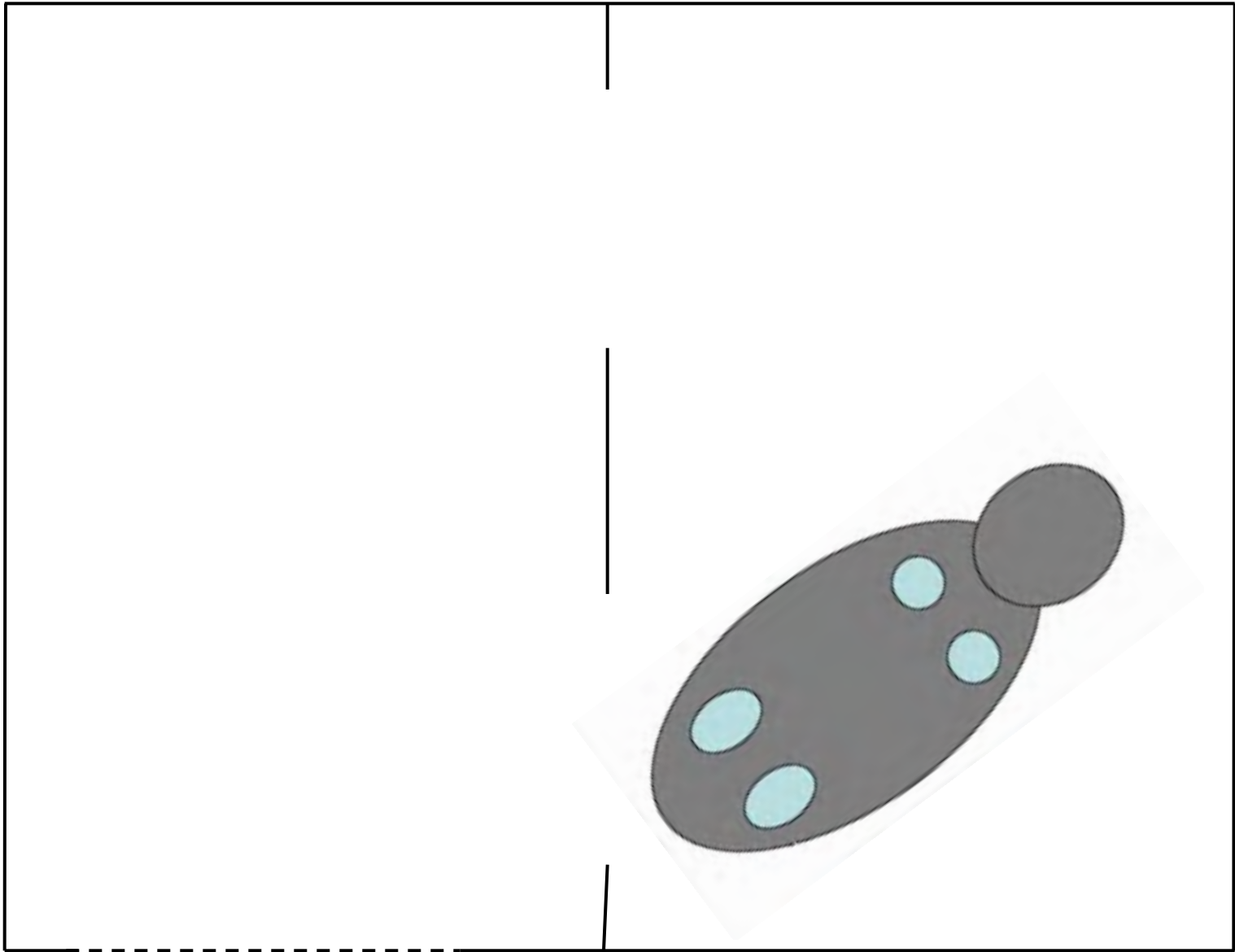


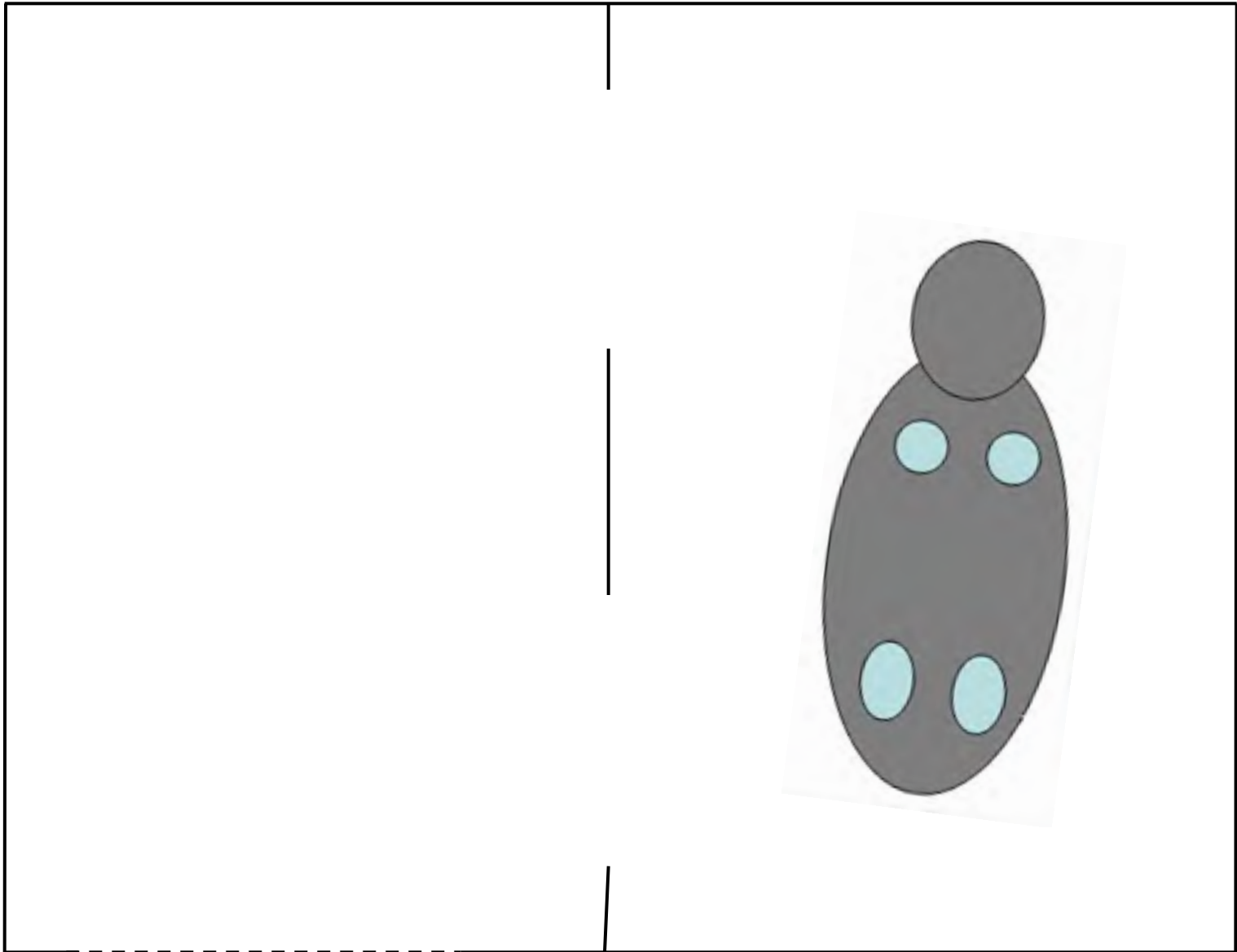


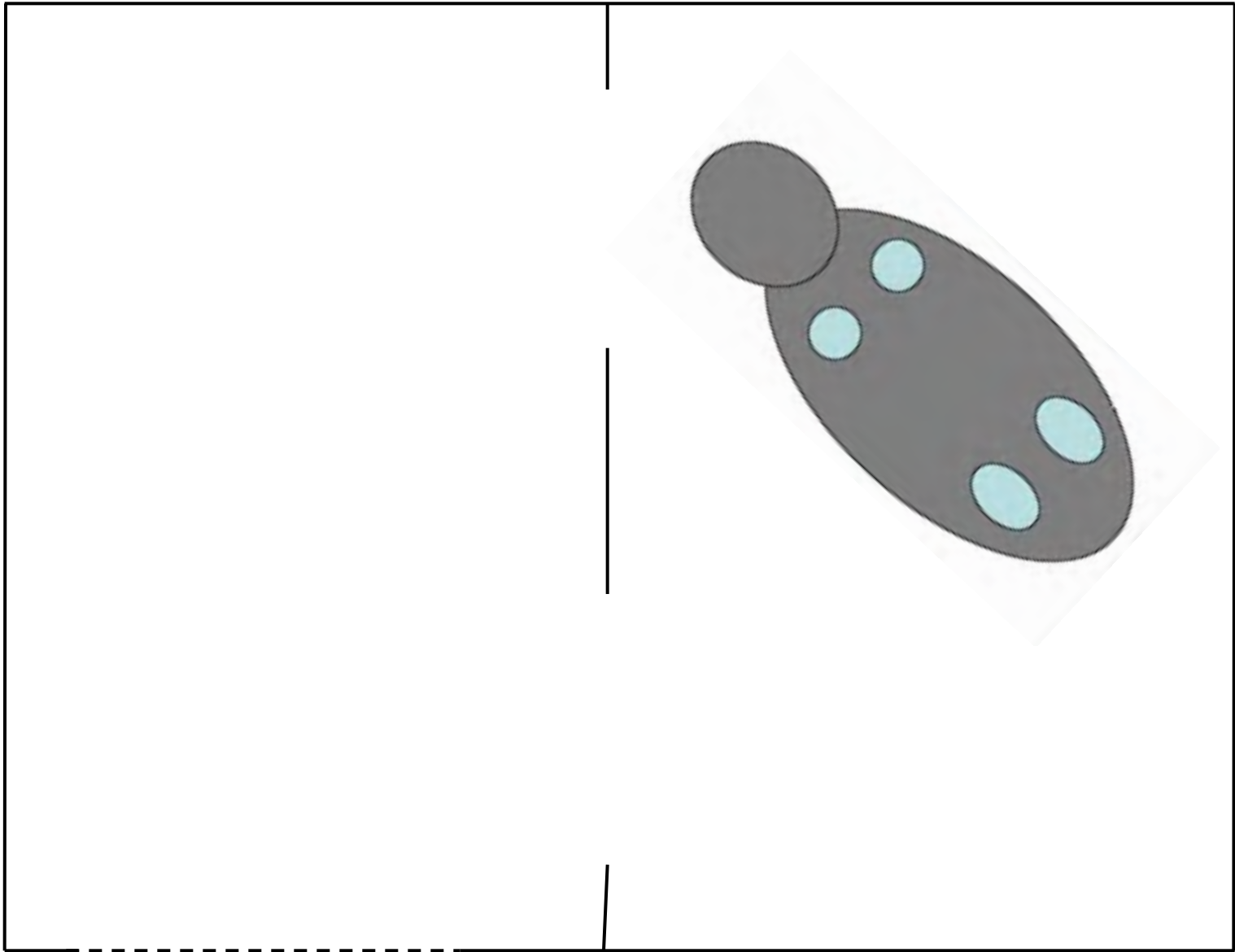


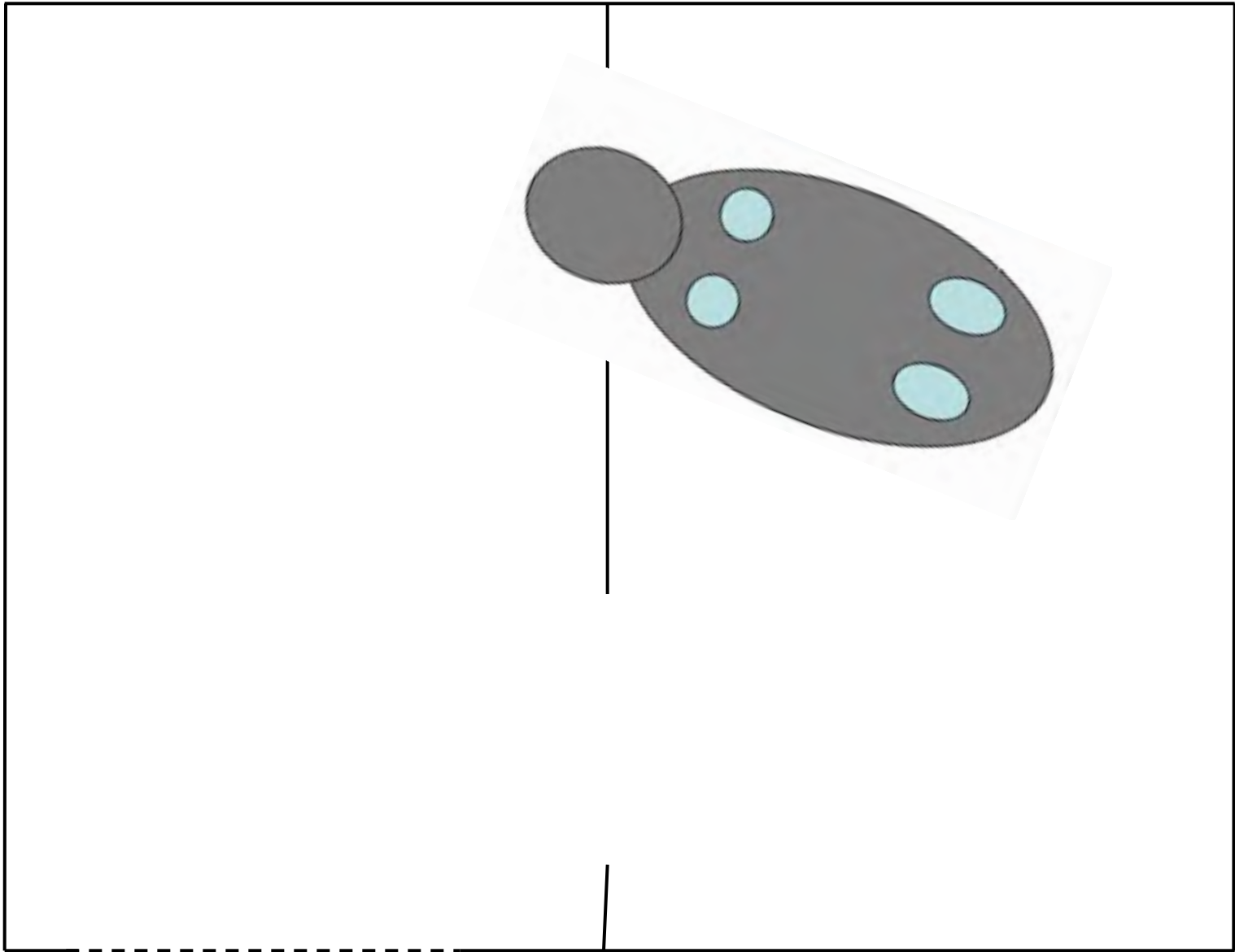


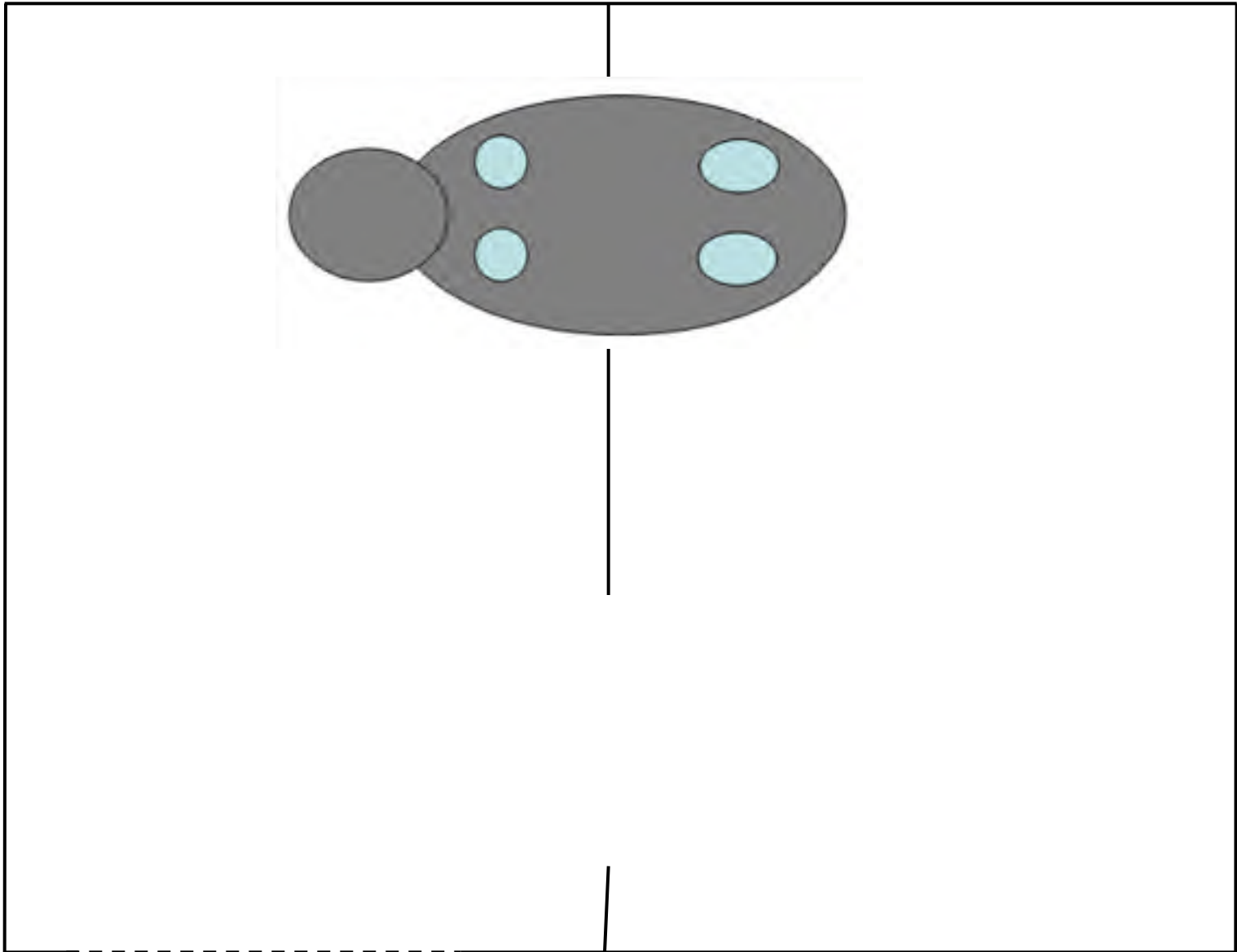


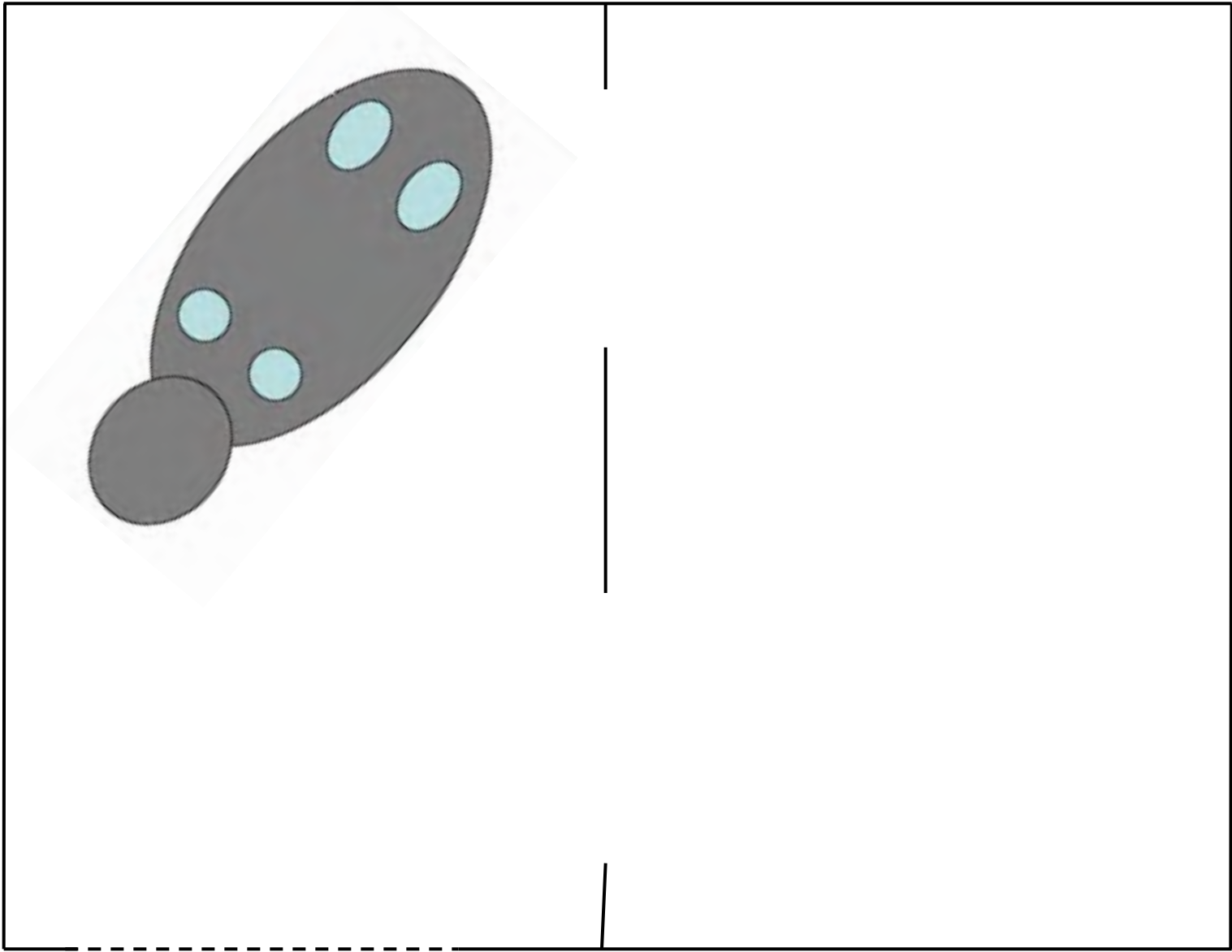


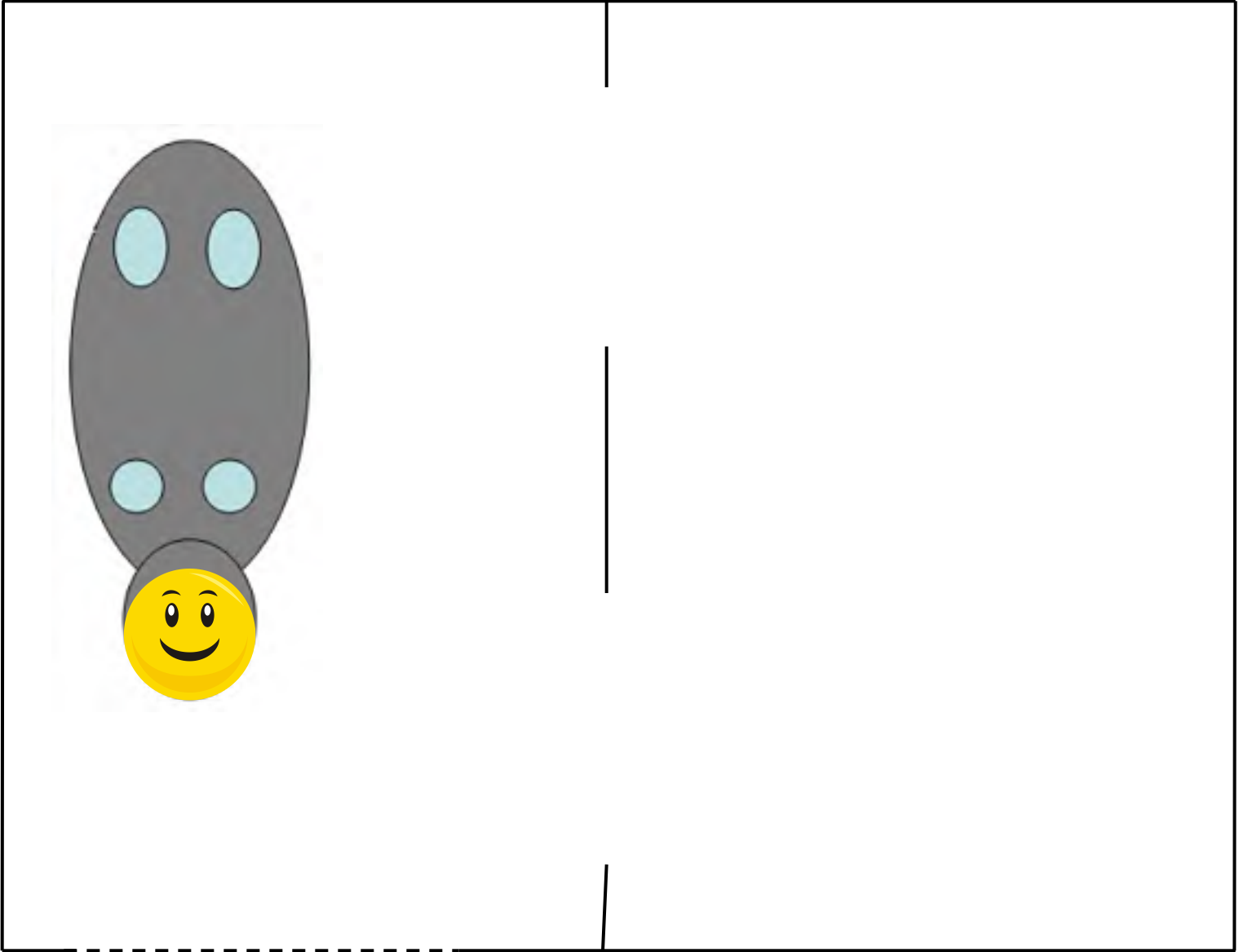













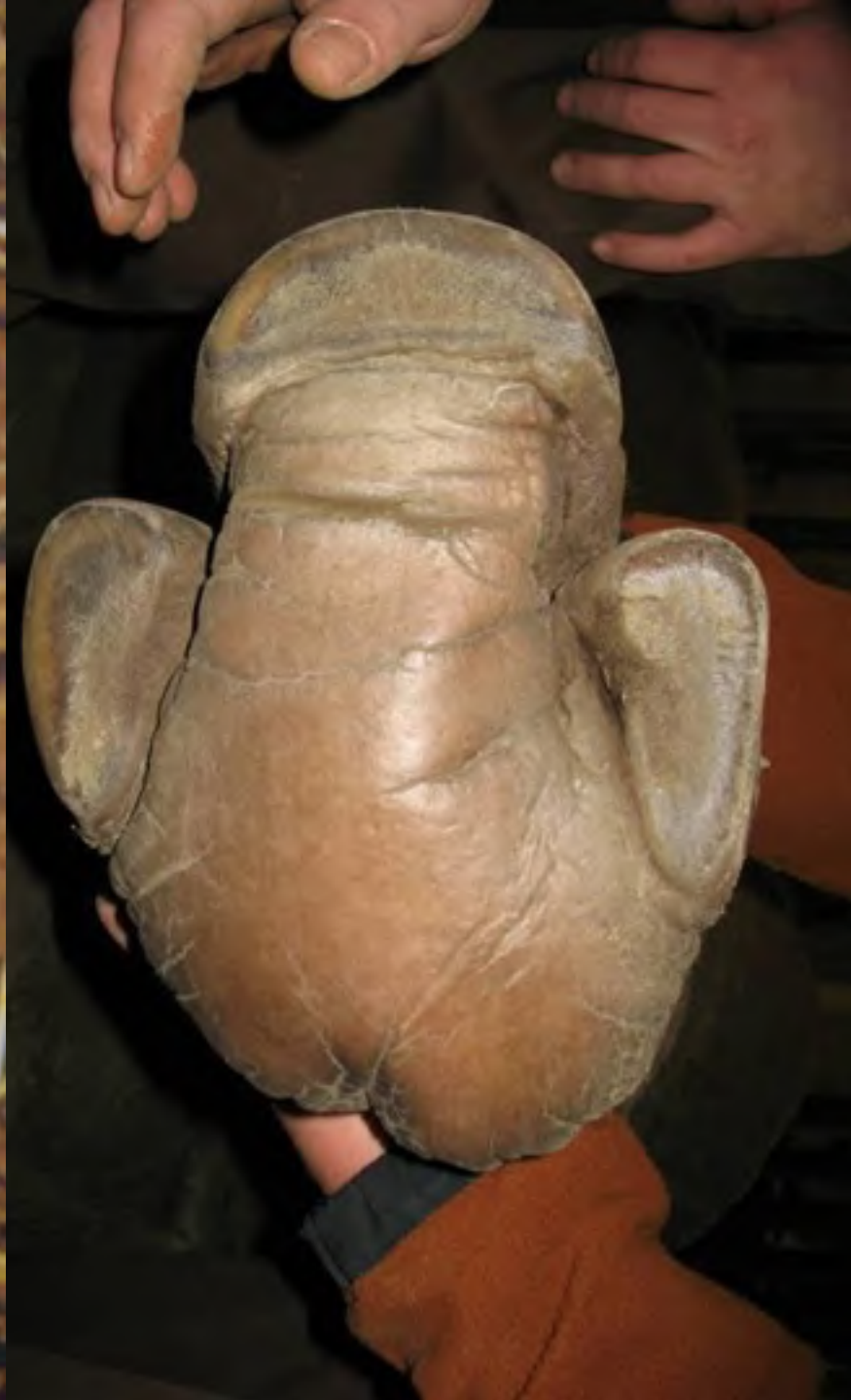
Bertus, 2008





Bertus, 2010



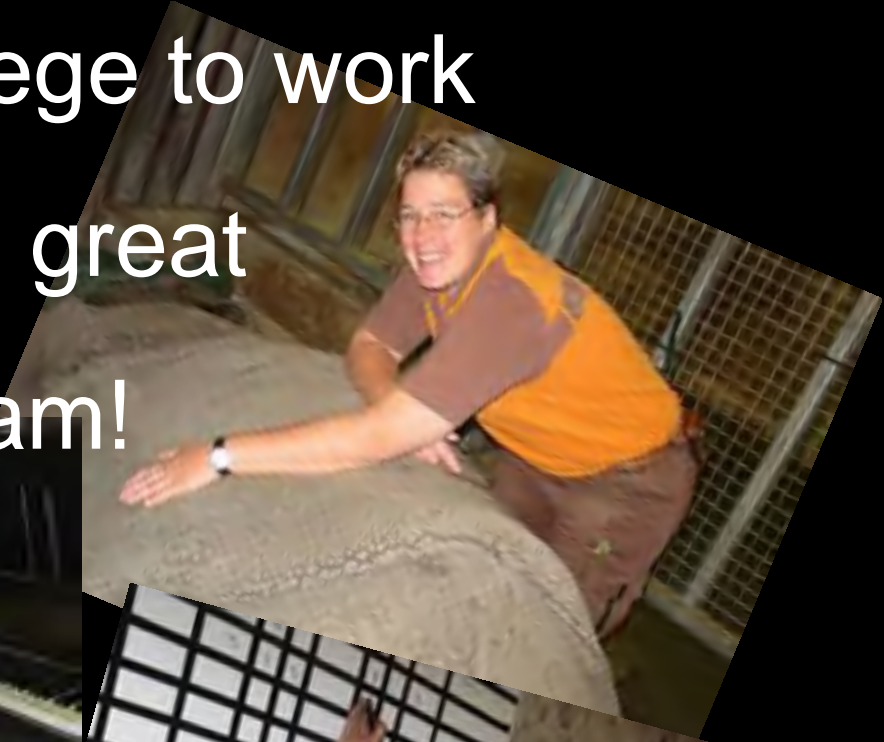

Frederique von Houwald

- Nico: 8 anesthetic events in 9 years
- Namaste: 26 anesthetic events in 12 years. Since 1 year: 2x/week pedicure.
- Factors of influence:
 - Moisture / soft ground / local pressure
 - Water access (weight relieve)
 - Nutrition (biotine,.....?)

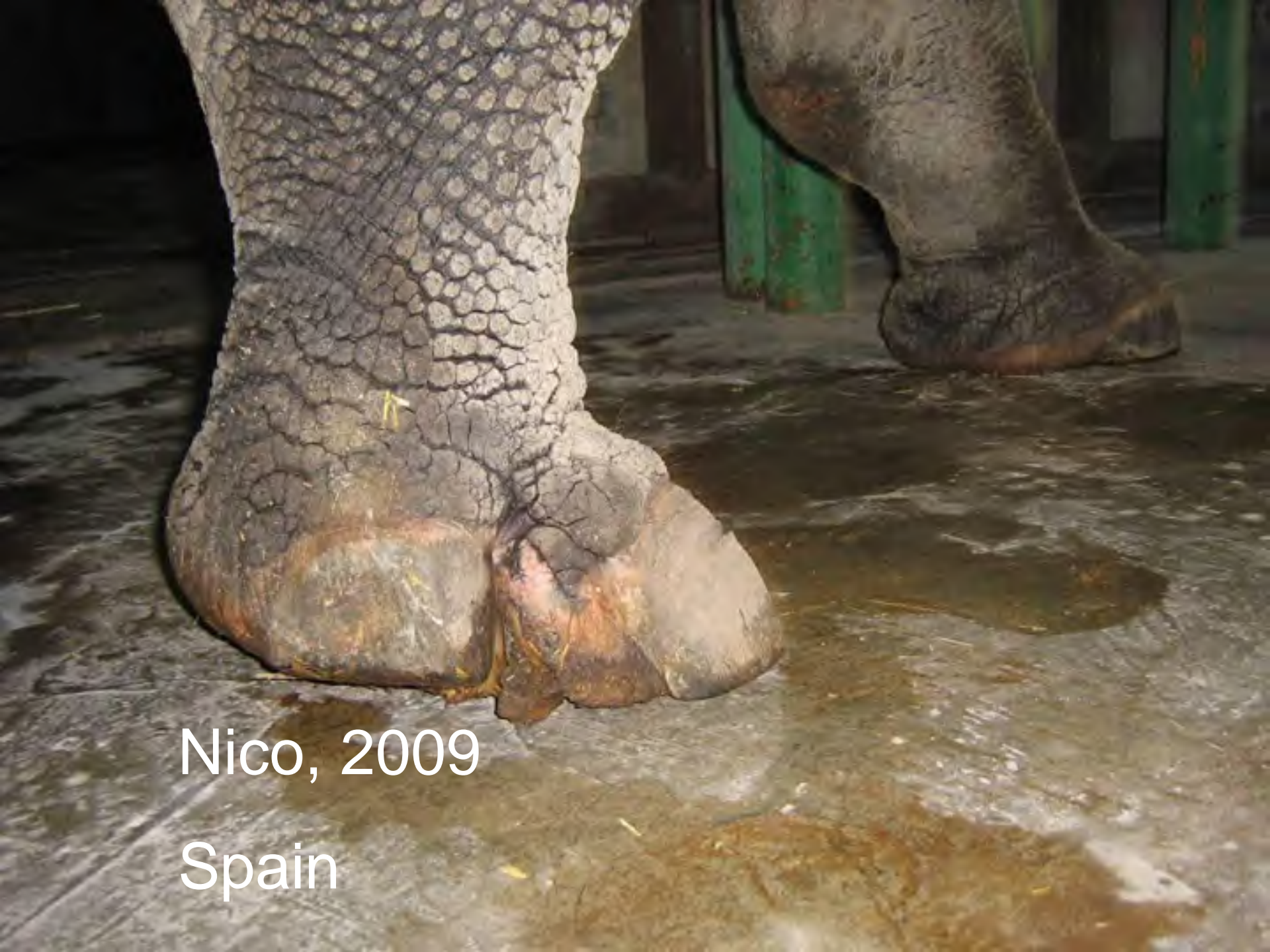It's a privilege to work
in this great
team!

Thank you!









Nico, 2009

Spain