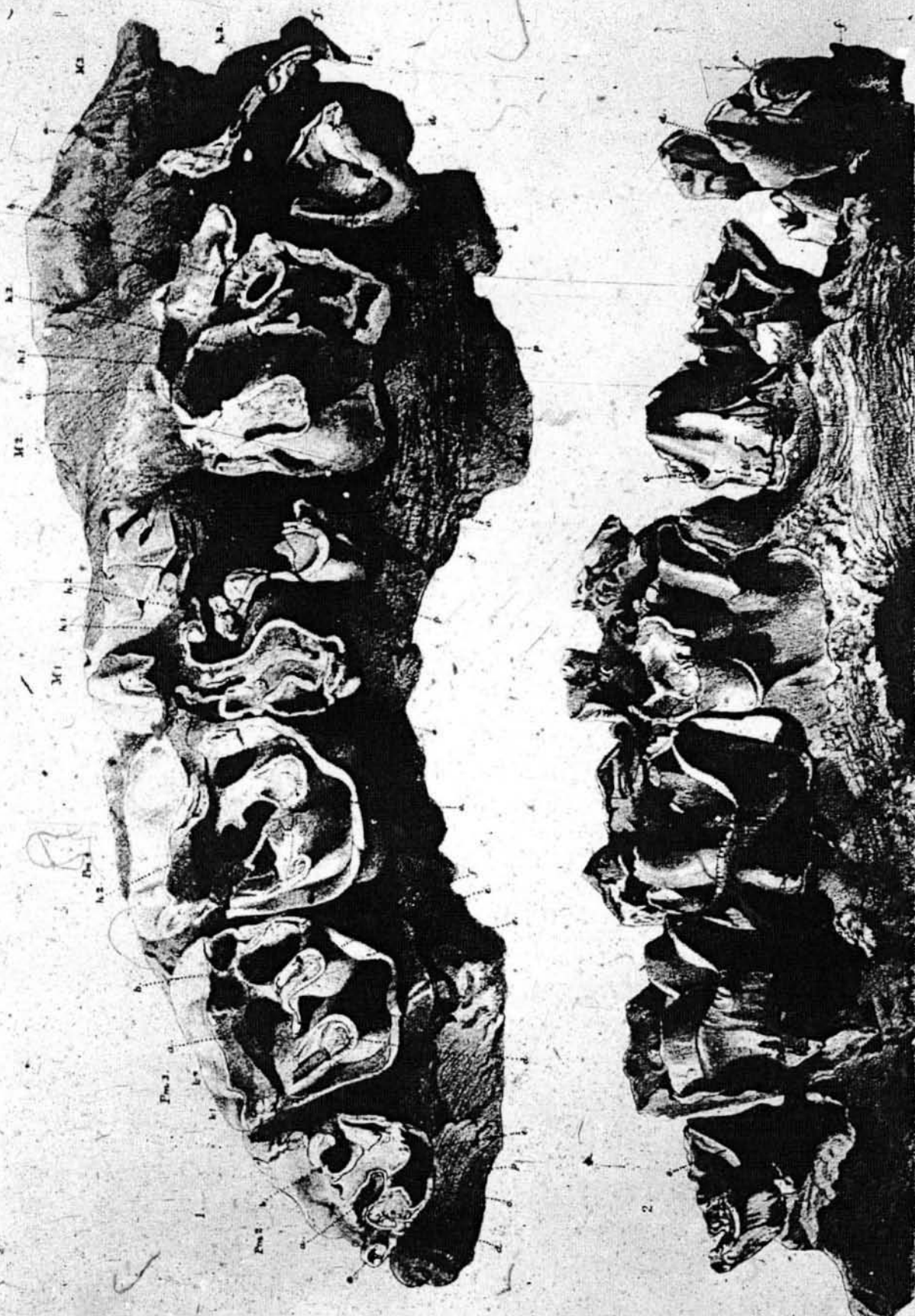

[Reprint.]

PLATE I.

RHINOCEROS DECCANENSIS, Foote.

- Fig. 1. View of masticatory surface of the upper molar series, left side.
Fig. 2. Left upper molars, from the inner side.



[Reprint.]

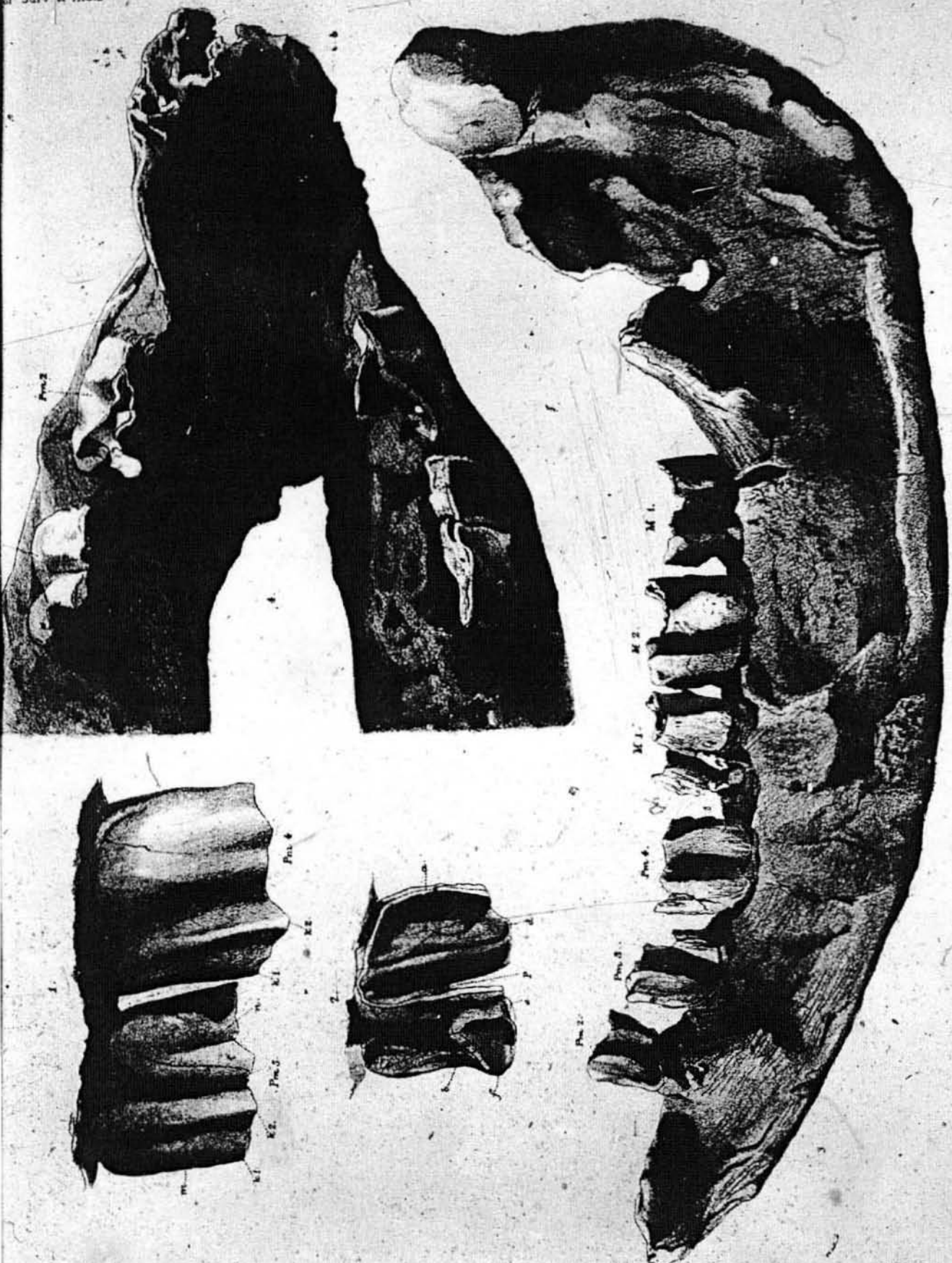
PLATE II.

RHINOCEROS DECCANENSIS, Foote.

- Fig. 1. Third and fourth upper premolars, left side, view of outer wall.¹
Fig. 2. Fragment of first true molar, right side, showing the inner wall of anterior valley (a),
to illustrate its great depth.
Fig. 3. Outer side of left ramus of mandible. Half natural size.²
Fig. 4. Symphysis of mandible seen from above.

¹ This view represents the teeth in their normal position, and does not therefore show their full height.

² The hindmost molar should be marked m² instead of m¹.



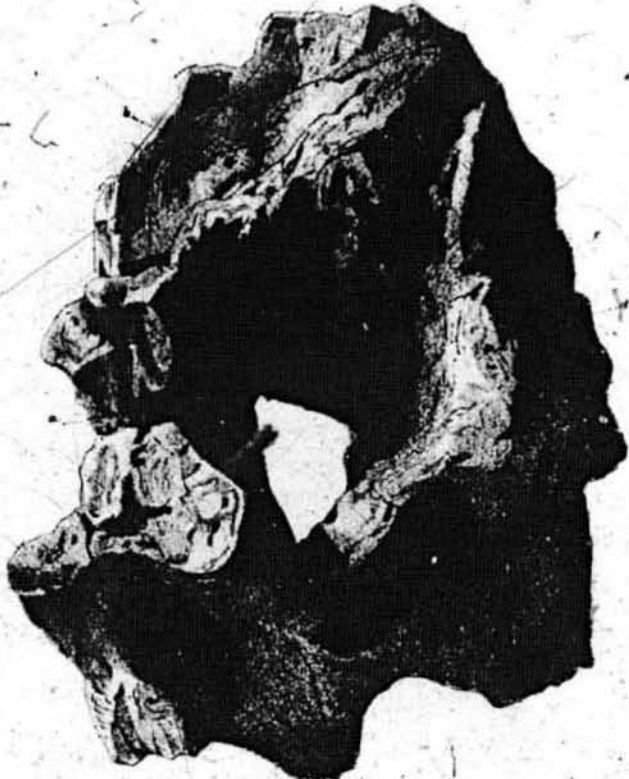[Reprint.]

PLATE III.

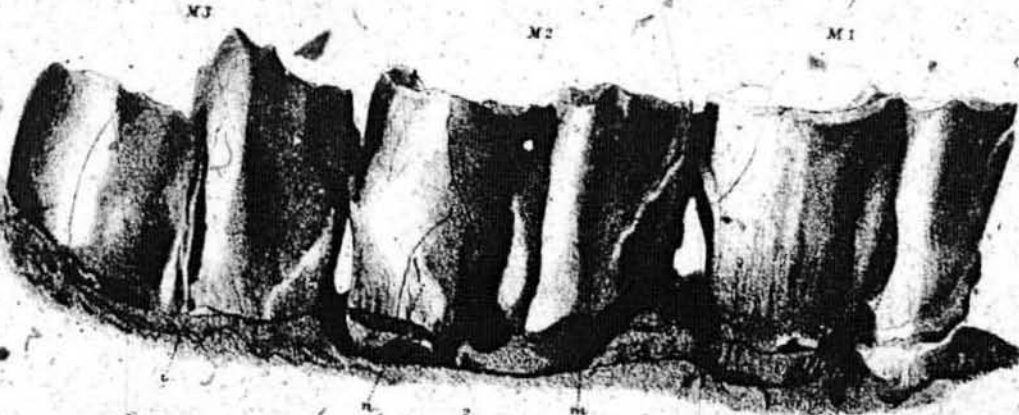
RHINOCEROS DECCANENSIS, Foote.

- Fig. 1. Squamosal bone with meatus auditorius (a), post-glenoid process (b), and post-tympanic process (c) : (d) parts of supra-occipital and ex-occipital (?) bones.
- Fig. 2. Outer sides of left lower molars.
- Fig. 3. Crown view of ditto.

All the letters not given here and in preceding plates will be found given on page 8.




I.



M3

M2

M1



M3

M2

M1

J.