

JOURNAL  
OF THE  
ASIATIC SOCIETY OF BENGAL.

Part II.—PHYSICAL SCIENCE.

No. III.—1880.

XI.—*Notes on the Dentition of Rhinoceros.*—By R. LYDEKKER, B. A.

(Received March 9th ;—Read June 2nd, 1880.)

(With Plate VII.)

A recent examination of the dentition of the fine series of skulls of *Rhinoceros indicus* contained in the collection of the Indian Museum, has brought to my notice several very interesting facts in regard to the development and serial homology of certain of the teeth of that and other species which I have thought of sufficient importance to be put on record, whence the following notes have been penned. My remarks will mainly refer to the dentition of *Rhinoceros indicus*, but some points relating to that of other species of the genus will be incidentally referred to in the course of the paper.

To illustrate my subject, I have had lithographed (through the courtesy of Mr. J. Wood-Mason) the left upper dentition of two adolescent skulls of *R. indicus*, from the collection of the Indian Museum, each of which is remarkable for an abnormality. The dentition exhibited in fig. 1 of the accompanying plate belongs to a young animal, and comprises two incisors ( $i.^1$ ,  $i.^2$ ), the milk-molar series ( $m.m.^1$  to  $m.m.^4$ ), and the true molars ( $m.^1$  to  $m.^3$ ), the last of which is still in its alveolus. The second specimen (fig. 2) belongs to a somewhat older animal, and exhibits the alveolus of an incisor ( $i.^1$ ), two premolars ( $p.m.^1$ ,  $p.m.^2$ ), two milk-molars ( $m.m.^3$ ,  $m.m.^4$ ), and the three true molars ( $m.^1$  to  $m.^3$ ), the last of this series, in this instance also, not having yet cut the gum. The grounds on which these teeth are assigned to their respective serial positions will be found in the sequel.

The true molars ( $m.^1$ ,  $m.^2$ ,  $m.^3$ ) in all species of *Rhinoceros*, whether living or extinct, are invariably three in number, corresponding with the typical mammalian series, and, therefore, require no further notice on this occasion. In advance of the first of the three true molars, there occur, in all young skulls of *Rhinoceros*, four teeth in serial apposition, but in older skulls there may be only three. It is to these anterior teeth of the milk-molar and premolar series (the one or the other present, according to the age of the animal) to which I now desire to draw attention.

An examination of the skull of which the left dentition is drawn in fig. 1, shows that, of the four teeth ( $m.m.^1$ ,  $m.m.^2$ ,  $m.m.^3$ ,  $m.m.^4$ ) in advance of the first true molar ( $m.^1$ ), the three last ( $m.m.^2$ ,  $m.m.^3$ ,  $m.m.^4$ ) have their fangs and bases absorbed away by the germs of other teeth, which are succeeding them from above: there can, therefore, be no doubt that these three teeth are the three last milk-molars of the typical series. This is also shown by the last tooth of the anterior series ( $m.m.^4$ ) being more worn than the first of the true molar series ( $m.^1$ ): if the tooth preceding the latter were a premolar, it would be the less worn of the two. The first tooth of the whole series ( $m.m.^1$ ) shows, however, no signs of being about to be replaced by a vertically succeeding premolar. I have carefully examined another skull of the same age, in which the alveoli of the teeth have been opened, and I can find there no trace of a replacing premolar above the first of the seven teeth of the molar series. Were this tooth to be replaced by a premolar, such replacement would take place before that of the tooth next in the series. Several other adolescent skulls of *R. indicus* which I have examined show no trace of the replacement of the anterior tooth, and it may, therefore, be considered to be proved that in many instances no such replacement ever takes place.

From the development of the tooth in question with the milk-molar series (though it sometimes appears rather later than the next tooth), there would seem to be no doubt that it is the first of that series, and I shall show below that such is undoubtedly the case. From the fact of this tooth having in most instances no vertical successor and persisting for a considerable time during the period of use of the permanent dentition, it is not unfrequently referred to as the first premolar, and though, as I shall show, such a nomenclature is altogether inaccurate, yet it has a certain amount of convenience which may justify its conditional use.

The dentition drawn in fig. 2 also exhibits four teeth in front of the first true molar ( $m.^1$ ), but they are not all homologous with those in the preceding specimen. The two teeth ( $m.m.^3$ ,  $m.m.^4$ ) in advance of the first true molar ( $m.^1$ ) in fig. 2 are more worn than the former, and will consequently be the third and fourth milk-molars, or the homologues of the corresponding teeth in fig. 1. The first and second teeth ( $p.m.^1$ ,  $p.m.^2$ ),

however, in fig. 2 are still in germ, and as being totally unworn must be of a later development than the third and fourth milk-molars: consequently, the former must be the first and second premolars, which have replaced the first and second milk-molars. In this instance, therefore, the first milk-molar, which, as we have seen, is normally persistent, has been replaced by a vertically succeeding premolar, from which replacement there can be no question as to the correctness of the serial position assigned to the former tooth. The replacing premolar (fig. 2, *p.m.*<sup>1</sup>) is of considerably larger size and more complex structure than the replaced milk-molar (fig. 1, *m.m.*<sup>1</sup>).

In the lower jaws of all the skulls of *R. indicus* which have come under my notice, I cannot find any instance of the vertical replacement of the first milk-molar, which generally persists until the permanent dentition is well in wear, and subsequently falls out at a comparatively early period. Neither can I find any instance of the replacement of the first milk-molar of either jaw in *R. sumatrensis* (*sumatranus*) or *R. javanicus* (*sondaicus*).

The formula of the molar dentition of *R. indicus*, taking into account the abnormal form, may be written as follows:—*m.m.*  $\frac{4-4}{4-4}$  *p.m.*  $\frac{(3\cdot4)-(3\cdot4)}{3-3}$   
*m.*  $\frac{3-3}{3-3}$ ; the adult molar dentition of the normal form, *m.m.*  $\frac{1-1}{1-1}$  *p.m.*  $\frac{3-3}{3-3}$   
*m.*  $\frac{3-3}{3-3}$ ; and of the abnormal form, *m.m.*  $\frac{0-0}{1-1}$  *p.m.*  $\frac{4-4}{3-3}$  *m.*  $\frac{3-3}{3-3}$ .

The succession and homology of the anterior tooth of the molar series appears to have given rise to a certain amount of confusion among naturalists. Thus Professor Huxley when treating of the dentition of the genus *Rhinoceros*, observes:\* “Of the four milk-molars, the first, as in the Horse, is smaller than the others, and is not replaced;” two pages back in the same work, however, the Professor gives the formula of the premolars as  $\frac{4-4}{4-4}$ , which would imply either that the first tooth of the molar series is replaced, or else that it is reckoned as a premolar, in which case there would be only three milk-molars.† Professor Owen appears to have come to a conclusion totally opposite to that of Professor Huxley, and seems to consider that the first milk-molar is always replaced. Thus on page 592 of his ‘Odontography’ the Professor observes that “the first of the

\* ‘Anatomy of Vertebrated Animals,’ p. 362.

† In a work explanatory of the homology of the teeth, as is Professor Huxley’s, there can be no doubt that this homology should be given with the most strict accuracy. In descriptive zoology and paleontology, however, it will still be convenient, in referring to the dentition of the genus *Rhinoceros*, to count the first milk-molar, when persistent, as a premolar, in order to avoid introducing another term into the dental series. The same conventional arrangement may be adopted in regard to the permanent and milk-incisors, referred to below.

*permanent* series of seven molar teeth is very small in both jaws, and is soon shed ;” and again on page 599, “the first milk-molar soon yields place to the first premolar.” The above given instances of the dentition of *R. indicus* show that this view cannot be normally correct: the difference in the form of the first upper milk-molar (*m.m.*<sup>1</sup>) and the first premolar (*p.m.*<sup>1</sup>) shows, in cases where the former tooth persists, that it cannot be a premolar which has supplanted a milk-molar *in utero*, as might otherwise be the explanation according to Professor Owen’s views.

I now come to the consideration of the non-molar dentition, and shall first treat of the teeth of the upper and secondly of the lower jaw.

According to Professor Owen,\* there is developed in the fœtal skull of *R. indicus*, immediately behind the maxillo-premaxillary suture, a very small tooth, which, from its position must be the milk-canine: this tooth disappears at an extremely early age, and no permanent successor is ever developed. I can find no record of an upper canine ever having been observed in the fœtus of any other species of the genus, and no permanent upper canine occurs in any species.

In a very young skull of *R. indicus*, figured by Cuvier,† there appear in the premaxilla the alveoli of two teeth, which must be those of the first and second milk-incisors. Two, indeed, appear to be the normal number of upper milk-incisors developed in the genus, though Professor Huxley‡ speaks of there being three on either side in some species.§

Normally, in *R. indicus* there is only one permanent incisor developed, succeeding the first (innermost) milk-incisor; the former tooth is easily recognized by its lateral elongation. Occasionally, however, as in the skull of which the left upper dentition is represented in fig. 1, a second upper incisor (*i.*<sup>2</sup>) is developed, replacing the second milk-incisor. In the figured specimen, the two incisors (*i.*<sup>1</sup>, *i.*<sup>2</sup>) are still in the condition of germs just protruding from their alveoli; from the condition of wear of the molar series it is quite evident that the two incisors belong to the second series, which is also shown by the characteristic form of the innermost (*i.*<sup>1</sup>); the second incisor (*i.*<sup>2</sup>) is not lengthened laterally like the first. In the right premaxilla of the same skull, only the first incisor is developed. Another instance of the development of the second incisor of one side of the upper jaw is afforded by the skull belonging to a mounted skeleton of an old individual of *R. indicus* in the Indian Museum, in which all the teeth of the permanent series are much worn. In the right premaxilla of that skull

\* ‘Odontography,’ p. 592.

† ‘Ossemens fossiles,’ Ed. 1836. Atlas, pl. xliii, fig. 3.

‡ Loc. cit. p. 362.

§ I am not aware which species is referred to.

there occur two large and well-worn permanent incisors not differing to such an extent in size as do those of the figured specimen. No trace of a second incisor is to be found in the left premaxilla, and I cannot, indeed, find any instance of the development of the two upper incisors of both sides in the same individual of *R. indicus*. The occasional development on one side only of the second permanent incisor in the last-named species, would seem to be a pretty clear indication that it is descended from an ancestor in which two pairs of upper incisors were normally present. It seems, indeed, that, when teeth normally absent do present themselves, they usually appear only on one side, as in the instance of the lower jaw of a tiger with an extra premolar, described by myself in a former volume of the Society's Journal.\*

In all species of the genus, the normal number of permanent upper incisors (if any are present) appears to be one only on either side, and I have not come across any instance of the abnormal development of the second upper incisor in any species but *R. indicus*. It may not improbably be, however, that such abnormal development may occur in other species.

It has, indeed, been stated on the authority of the late Dr. Falconer† that the extinct Indian *R. sivalensis* was furnished with three pairs of upper (and lower) permanent incisors; none of the numerous specimens of the skull of this species figured in the 'Fauna Antiqua Sivalensis,' however, exhibit any incisors at all, and we have, therefore, no tangible evidence whatever to support the new genus *Zalabis* lately proposed by Professor Cope‡ for the reception of this species on the ground of the unusual number of incisors with which it was provided.

Turning now to the lower jaw, we shall find that there is some considerable difficulty in arriving at a satisfactory conclusion as to the homologies of the teeth in advance of the molar series.

In *R. indicus*, there normally exist in the young animal an inner pair of very small conical teeth, and an outer pair of larger teeth. The outer pair are succeeded from below by a pair of much larger triangular and pointed teeth, which, therefore, evidently belong to the permanent series. Normally, I believe, the inner pair are not succeeded by permanent teeth, as I can find no trace of such in most lower jaws; in the lower jaw of the skull drawn in fig. 1, however, there occurs, a little above and internal to the middle pair of teeth, a second pair of small teeth, which are less protruded from the jaw, and which, I think, certainly belong to the second dentition.

\* Vol. xlvii, pt. ii, pl. 2.

† Owen, loc. cit. p. 589.

‡ Bul. U. S. Geol. Geog. Surv. Vol. v, p. 229.

We may, therefore, say that in *R. indicus* there are always developed in the symphysis of the mandible two pairs of milk-teeth, and always one, and occasionally two pairs of permanent teeth. When the middle pair of milk-teeth are not replaced, they remain during the permanent dentition, as in the analogous case of the first upper milk-molar.

It now remains to consider the serial position of the teeth in question. With regard to the middle pair of teeth, there can be no question but that they are incisors, and probably the first of that series. With regard to the homology of the larger outer pair of teeth, two views are entertained. By the older writers, this pair of teeth were unhesitatingly classed as incisors; a view adopted both by Prof. Huxley and by Prof. Owen. Latterly, however, some writers, among whom may be mentioned Professors Cope\* and Gaudry,† have come to the conclusion that this outer pair of teeth are really canines, apparently from their resemblance to the undoubted canines of certain genera of extinct Mammals. To distinguish between a canine and an incisor tooth in the lower jaws of animals in which the incisors are reduced and no upper canine is present, is indeed a matter of extreme difficulty, and I do not desire on the present occasion to enter into the reasons either for or against the innovation. I provisionally, however, adopt the old nomenclature.‡ With this view of the homology of the teeth in question, the anterior milk dentition of *R. indicus* may be formulated as follows:— $c. \frac{1-1}{0-0} i. \frac{2-2}{2-2}$ , the adult dentition will be normally  $c. \frac{0-0}{0-0} m.i. \frac{0-0}{1-1} i. \frac{1-1}{1-1}$ , or abnormally  $c. \frac{0-0}{0-0} i. \frac{2-2}{2-2}$ .

In treating of the milk dentition of *Rhinoceros*, Professor Huxley§ remarks of the two pairs of lower incisors that "it seems probable that only one pair, in any case, are permanent teeth." I have shown that occasionally in *R. indicus* both pairs may be replaced by permanent teeth, and I now proceed to show that such is at all events sometimes the case in another species. In a lower jaw of *R. javanicus* figured by De Blainville,|| there are the germs of two incisors on each side *in alveolo*, below protruded incisors; the former, therefore, are clearly permanent teeth. I have no means of knowing whether this replacement is abnormal or normal. In

\* Loc. cit.

† 'Les Enchainements du Monde Animal: Mammifères Tertiaries,' p. 50, et seq.

‡ I may perhaps observe that there seems to be some discrepancy in M. Gaudry's nomenclature, since on page 58 of his work quoted above, he speaks of there being two pairs of small incisors in the lower jaw of *R. bicornis (africanus)*, and yet does not produce any evidence to show that these teeth are not the homologues of the two pair of teeth in the mandible of *R. indicus*, which are reckoned as incisors and canines.

§ Loc. cit. p. 362.

|| 'Osteographie,' Atlas, Rhinoceros, pl. viii.

*R. sumatrensis*, there is in the adult state no median pair of lower incisors,\* and it is, therefore, probable that permanent middle lower incisors are never developed in this species.†

In the living African species of *Rhinoceros*, in the extinct Indian *R. deccanensis*, and other extinct species, no permanent incisors, in either jaw, were ever developed, and in the adult the symphysis of the mandible and the premaxillæ are consequently edentulous. It has been said that three pair of lower incisors were developed in *R. sivalensis*, but none of the lower jaws of the genus figured in the 'Fauna Ant. Siv.' show more than two pairs of these teeth, and none are present in the specimen referred to *R. sivalensis*.

From the foregoing brief notes it will be gathered that the dental system of the genus *Rhinoceros* presents very considerable differences in different species, and occasionally in different individuals of the same species. These differences are mainly due to the varying extent to which specialization has operated in the genus, and to the occasional development by 'reversion' of teeth normally absent.

The genus *Rhinoceros* (using the term in its original comprehensive sense) is indeed one of those in which the dental system may be said to be in a condition of change, and this variability in the matter of the development or suppression of certain teeth in species and individuals, appears to me to render the splitting up of the old genus into a number of new genera or subgenera (except in the case of *Acerotherium*) a very questionable measure. The relative prominence or insignificance of the anterior teeth may be traced in a graduated scale from one species to another as has been most ably done by M. Gaudry in his invaluable work already quoted in this paper.

#### EXPLANATION OF PLATE VII.

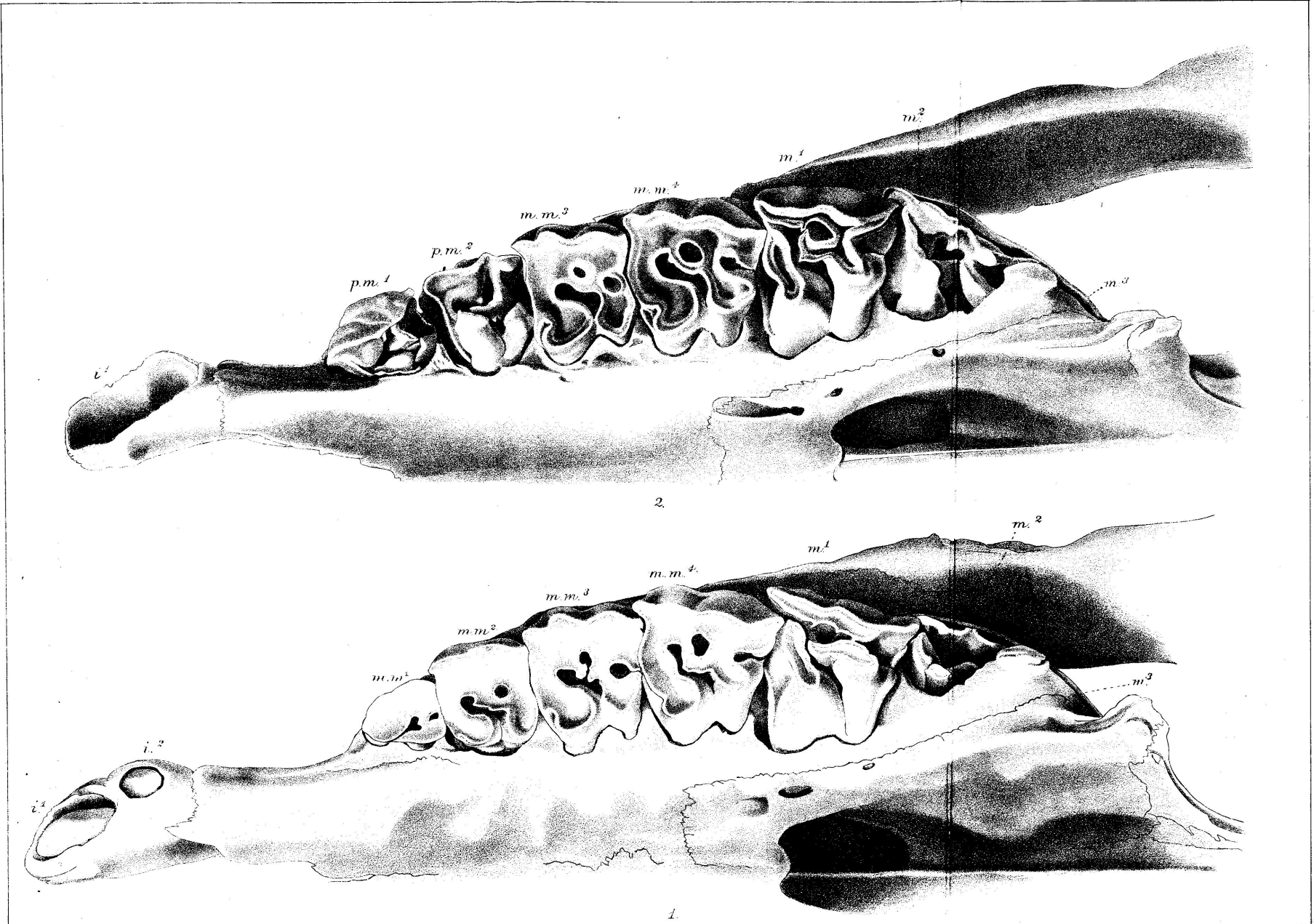
Fig. 1. The left upper dentition of an immature specimen of *R. indicus*, showing the germs of two permanent incisors ( $i^1, i^2$ ), four milk-molars ( $m.m.^1, m.m.^2, m.m.^3, m.m.^4$ ), first and second true molars ( $m.^1, m.^2$ ), and the alveolus of the third ( $m.^3$ ). (The animal to which this skull belonged was killed by Mr. W. T. Blanford.)

Fig. 2. The left upper dentition of a somewhat older individual of the same species, showing the alveolus of the first permanent incisor ( $i^1$ ), the first and second pre-molars ( $p.m.^1, p.m.^2$ ), the third and fourth milk-molars ( $m.m.^3, m.m.^4$ ), the first and second true molars ( $m.^1, m.^2$ ), and the alveolus of the third ( $m.^3$ ).

Both specimens are drawn one half the natural size.

\* Professor Cope (loc. cit. p. 229) is in error when he gives two pairs of mandibular teeth to this species.

† I should doubt if the lower jaw drawn in fig. 15 of plate 138 of Owen's 'Odontography' as of *R. sumatrensis* belongs to that species.



Abnormal Dentition of  
RHINOCEROS INDICUS.

Behari Lal Das, del. J. Schaunberg, Lith.

W. Newman & Co. imp.