

# Assessment of Fertility Status in the Male Sumatran Rhino at the Sumateran Rhino Sanctuary, Way Kambas National Park, Lampung

MUHAMMAD AGIL<sup>1,2\*</sup>, IMAN SUPRIATNA<sup>1</sup>, BAMBANG PURWANTARA<sup>1</sup>, DEDI CANDRA<sup>2</sup>

<sup>1</sup>Department of Clinics, Reproduction and Pathology, Faculty of Veterinary Medicine, Bogor Agricultural University, Darmaga Campus, Bogor 16680, Indonesia

<sup>2</sup>Suaka Rhino Sumatera, Way Kambas National Park, Lampung, Indonesia

Received June 25, 2007/Accepted February 21, 2008

Sumatran rhino is the most endangered rhino species. Its population is estimated less than 300 individuals remaining in the wild with highly declining rate to 50% in the last 15 years. The number of male rhinoceroses in the captivity are very few, therefore the assessment of its fertility is very important in order to support the breeding success since the captive breeding success is very poor. The objectives of this study were (i) to determine the male reproductive status, (ii) to establish a reliable semen collection method, and (iii) to assess semen parameters of the fresh collected sample. Three methods of semen collection were examined to determine its fertilizing potential, i.e. (i) stimulated combination of artificial vagina (AV), penile massage (PM) and accessory gland massage (AGM); (ii) AV and PM; and (iii) only with PM. The first method gave the best result with an ejaculation success of 85.71% (6/7, n = 7). The second and third methods obtained an ejaculation success rate of 50% (2/4, n = 4) and 25% (1/4, n = 4), respectively. The collected ejaculates had a volume of 1.2-12.4 ml with whitish to cream turbid colour and pH 6.90-6.99. Sperm concentration was (143-333) x 10<sup>3</sup> sperm/ml. The quality of the sperm was low with only approximately 1% of them moved forward slowly. Approximately 80% of the spermatozoa were immature (*prox. cytoplasmic droplet*) with head (*macro-, microcephalic*) and tail abnormalities (broken tail). Semen quality increased after several collections and the amount of immature sperm decreased up to 5%. Electroejaculation procedure could produce 34 ml semen, but no sperm was found in the ejaculate. Hence, the combination of AV, PM, and AGM could get higher volume of ejaculate compared to other methods, but sperm concentration was better obtained using AV and PM only. Repeated semen collection increased semen quality, although the male has low fertilizing capacity due to low sperm concentration (*oligozoospermia*) and small volume of the ejaculate (*oligospermia*).

Key words: Sumatran rhino, semen, sperms, collection

## INTRODUCTION

The Sumatran rhinoceros is the most critically endangered rhinoceros species. With fewer than 300 animals left worldwide and an extremely high rate of decline (50% of wild population lost over the last 15 years), the species is listed on Appendix I of CITES and in the red list of IUCN (<http://www.redlist.org/search/search.php?>). Very few Sumatran rhinos are to date kept in captivity (about 9 animals distributed worldwide). Moreover, although the species has been kept since the early 19<sup>th</sup> century (year 1,800 until now, total 96 animals), no animal bred successfully until one offspring was born in 2001 in Cincinnati Zoo, USA. There are a number of reasons for this failure in captive breeding, such as a lack of understanding of its reproductive biology, limited number of male rhinos and a lack of knowledge on breeding management and information on the fertility status of the rhinos in captivity.

Despite many successful mating taken place since 2002, no pregnancy occurred in the female housed in the Sumatran Rhino Sanctuary (SRS) Way Kambas. Since the female shows a regular pattern of ovarian cycle, indicated by hormone analysis and ultrasound examinations, the fertility of the male Sumatran rhinoceros in this facility (named Torgamba) has

been questioned, and was thought to be a major factor contributing to the failure of the breeding program in SRS. Clinical examination of reproductive organs and assessment of semen quality have historically been used to predict potential fertilizing capability of stallion (Colenbrander *et al.* 1992, 2003). Application of this approach may also provide important information on male fertility status in the Sumatran rhinoceros.

In order to analyze semen quality of the male Torgamba, the development of a reliable semen collection method is required, since to date no such methods are available for the Sumatran rhinoceros. Semen collection has, however, become a standard practice for fertility assessment and assisted reproduction procedures in many domestic animal breeding programs (Penny 2005).

Therefore, this research was conducted with the objectives: (i) to establish a reliable semen collection method for the Sumatran rhinoceros, (ii) to assess semen parameters of the fresh ejaculates, and (iii) to determine Torgamba's reproductive potency.

## MATERIALS AND METHODS

**Animal and Housing Conditions.** For the study, only one male Sumatran rhino, Torgamba, a ~22 year old animal kept at the SRS, Way Kambas National Park, Indonesia, was available.

\*Corresponding author. Phone: +62-251-629461, Fax: +62-251-624446, E-mail: rhinogil@indo.net.id

Torgamba has been moved from Port Lympne Zoo, England to the SRS Way Kambas in early 1998. Generally, Torgamba is kept separately from the female rhino, Bina, but is allowed to have access to the female when Bina is showing oestrous signs and when there is an interest for mating. Semen collection were conducted in an observation cage (6 x 6 m), which is adjacent to the browsing enclosure (10 ha) area separated by a door and bars. Entry to or escape from the rhino was possible along the side of the observation cage between the bars. Since Torgamba was very tolerant to new objects and personnel in his cage, semen was collected without physical restraint or sedation, except when electroejaculation procedures were carried out. The study was conducted for two years from 2002 up to 2004.

**Semen Collection Methods.** Three methods of semen collection techniques were evaluated. The first approach was to combine accessory gland massage (AGM), penile massage (PM) and the use of an artificial vagina (AV); the second method combined only PM and AV, and the third was PM only. In addition, electroejaculation was performed, without combining it with any other technique.

**Penile Stimulation.** Penile stimulation was conducted using penile massage and or artificial vagina methods. The method was carried out according to the protocol described by Schaffer *et al.* (1990) for the Indian rhinoceros.

**Penile Massage (PM).** A penile massage was carried out with two operators kneeling at the rear of the male rhino and massaging the penis. Rubbing the medial side of the rear legs and the penile sheath always induced let-down of the penis from the sheath, allowing a direct massage. After the penis was released from the sheath, it was first washed with warm water (30-35 °C). Silicone gel (K-Y, Johnson & Johnson, New Brunswick, NJ) was then smeared on the distal of the penis, but the penile tip was kept free of lubricant. Complete erection was induced by rubbing back and forth on the top and bottom of this area with one hand. Gentle rubbing would become more vigorous as the penis became erect. With erection, the curve of the penis straightened, swinging the tip of the penis forward. A waterspade (dry and clean) was held down and in front of the tip of the penis to collect the ejaculate. Forceful ejaculations of seminal fluid occurred as the penis became fully erect. Shaking of the hind legs and thrusting of penis often occurred. Another operator would help support the penis as it became fully erect. The waterspade was held closed to the tip at all times during stimulation since semen could squirt or drip out at any time. After forceful ejaculation, the penis relaxed and the animal remained in the cage for further manipulation. If ejaculation did not occur when the penis was fully erected, the penis was allowed to relax. The period to induce erection and ejaculation lasted for 20-45 minutes. The process was repeated until the rhino would no longer stand still, which usually occurred after two hours.

**Artificial Vagina.** A modified AV was provided and donated by N.E Schaffer (through SOS rhino) based on her experiences using the AV in the Indian rhinoceros. A 15 cm diameter latex liner was doubled over and vulcanized together with a 15 diameter rubber ring. The other end of the folder liner was

also vulcanized close, except for an opening that could be stretched onto a 50 cc centrifuge tube (Figure 1). This AV was constructed to cover only the distal part (15-20 cm) of the penis. The cavity between both latex liners was then approximately half-filled with warm water (~40-45 °C). Lubricant was then applied to the interior of the AV. Inducing a fully erect penis by penile massage was required before the AV could be fitted.

**Rectal Stimulation.** Stimulation inside the rectum was conducted according to the protocol described by Schaffer *et al.* (1990). Rectal stimulation was induced by either accessory glands massage or by an electrical probe.

**Accessory Glands Massage.** For massage of the accessory glands, an operator inserted a plastic-sleeved, lubricated hand through the anal sphincter and then manually massaged the accessory glands through the mucosa of the caudal rectum. The prostate and bulbourethral glands, which were about 10-15 cm proximally to the anal sphincter, were massaged with rhythmic side-to-side downward pressure. Massage proceeded in 5 minute intervals with a 1-2 minute resting time between intervals. Duration of the whole procedures did not exceed 30 minutes.

**Electroejaculation.** Electroejaculation was conducted according to the protocol described by Roth (personal communication) and carried out under her supervision. The rhinoceros rectal probe (specifically designed for rhinoceros) and the electroejaculator (P-T Electronics, 11241 SE362nd, Boring, Oregon 97009, USA) were provided by T.L. Roth (through International Rhino Foundation/IRF, Figure 2).

The rhino was fasted 12 h prior to anesthesia preceding the electroejaculation process. Water was withdrawn from the cage in the morning of the procedure. The rhino was immobilized according to the anesthesia protocol described by Radcliffe *et al.* (2000) using a cocktail of butorphanol (Tobugesic, Fort Dodge Animal Health, Fort Dodge, Iowa 50501, USA: 10 mg/ml, dosage: 50 mg/200 kg body weight) and azaperone (Stresnil, Janssen Pharmaceutical, Mississauga, Ontario L5N 5R9, Canada: 40 mg/ml, dosage: 100 mg/200 kg body weight). Immediately after electroejaculation was finished, the rhinoceros was reversed with antidote 10 mg naloxone (Narcan, DuPont Pharmaceuticals, Manatí, Puerto Rico 007001; 1 mg/ml).

As soon as the rhinoceros was sedated, ropes were placed around the rear legs and fixed securely around the bars of the enclosure. Faeces were manually removed from the entire distal rectum. The penis was released from the sheath and cleaned with warm water (~30-35 °C) and a towel.

Prior to use, the surface of each electrode of the probe required sanding to remove oxidation. Following each use, the properly sealed probe was immersed in a bath of disinfectant cleaner. Once inserted, the handle of the probe was lifted, forcing the head of the probe down within the rectum and the electrodes made contact with the rectal lining just over the reproductive accessory glands. Electrical stimulation was administered in several series of increasing voltage (+ 1 volt each increase) with rest intervals of up to 5 minutes between each series. Each series consisted of 5-15

stimulations during which voltage was stepwise increased in three voltage ranges. Once the male started producing the fluid, the collection cups were exchanged frequently to avoid potential contamination of a good-quality fraction with one of poorer quality.

The position of the probe was changed frequently by shifting it slightly left, right, cranial, or caudal during the procedure in order to find the best results of penile stimulation and ejaculate production. Maintaining the probe in proper position with good rectal contact was often difficult, especially when the animal's muscles contacted hardly due to an increase of higher voltages.

**Sample Processing and Evaluation.** Semen in sample tubes was immediately protected from direct sunlight and analyzed in the field laboratory at SRS. Semen assessment included assessment of total volume, pH, sperm concentration, total sperm number, sperm motility, and morphology. Specifically, sperm concentration was assessed in a 10  $\mu$ l aliquot of the ejaculate using a haemocytometer (Neubauer). For sperm motility and morphology an aliquot (10  $\mu$ l) from each sample was diluted 1:10 in pre-warmed (~35 °C) deionize water and evaluated for percent sperm moving forward using a microscope equipped with a warm stage (Olympus, Japan). Ejaculate fractions were evaluated for pH by assessing the color change after adding 10  $\mu$ l of samples to an indicator strip (Neutralit pH 5-10, Merck, Darmstadt, Germany).

Sperm morphology was assessed under microscope from native smear and/or from stained smear using dip-quick staining procedure. Native smear was prepared using 10  $\mu$ l of ejaculates and mixed with 10  $\mu$ l of dionized water prior to the assessment. Dip-quick staining was used a commercial reagent, which has two different reagents (reagent #1, and reagent #2) for two steps of staining. Each step of staining procedure lasted for 2 minutes. A 10  $\mu$ l aliquot of ejaculate was smeared on the object glass, and then dried in the air for 10 minutes prior to staining procedure. Native smear was observed at 400x magnification, while dip-quick slide was investigated at 1,000x magnification under bright field microscopy. Sperm morphology was characterized as being normal or abnormal sperm. Abnormalities included defects of the head (micro- and macrocephalic), detachment of the tails and heads from the mid-piece flagellum, or the occurrence of cytoplasmic droplets.

## RESULTS

A two months training of the rhino was required to develop the various procedures and for habituation of the animals to the protocols. A total of 10 ejaculates were collected from 16 times the procedures were attempted, giving an overall success rate of about 62.5%.

There were, however, clear differences in the success rates between the different collection procedures applied (Table 1). In this respect, the combination of AGM, PM, and AV yielded the best results with 85.7% (6/7, n = 7) of the attempts resulting in an ejaculate. The other methods were less successful. The combination of PM and AV yielded only 50% of cases (2/4, n = 4) an ejaculate, while stimulation by PM only resulted in only 25% of attempts (1/4, n = 4) in an ejaculate. In all collection attempts using a combination of accessory gland massage, penile massage and artificial vagina, the rhino behaved very tolerant. This procedure basically needed several people to be involved. As shown in Figure 3, the procedure started by massaging the accessory glands until the penis drops from the sheath; soon after, another operator started to massage the penis until it was fully erect. It was then immediately inserted into the artificial vagina which was hold by another operator while the rhino was thrusting (Figure 3).

The ejaculate volumes obtained by the different collection procedures ranged between 1.2-34 ml (Figure 4). From the 10 ejaculates obtained, only four, however, contained spermatozoa. In each of these ejaculates, sperm concentration was very low ranging from  $143 \times 10^3$  –  $333 \times 10^3$  spermatozoa/ml ejaculate. In the ejaculates obtained by the procedures of PM only and electroejaculation, no sperm was found at all, although, the electroejaculation procedure produced the highest volume of ejaculate (34 ml).

Most of the sperms (85%) contained a proximal cytoplasmic droplet (Figure 5), and some sperms (15%) were found with abnormal head so called, macro- and microcephalic, and detached tail (broken tail) (Figure 6). However, the presence of a proximal cytoplasmic droplet decreased gradually from 85% in the first ejaculate obtained to 5% at the last ejaculate collected about one year later.

In terms of sperm motility, all samples showed a very low degree of motile sperm (< 10%), and most of the sperms were dead. From these results, there were presumably only one percent of sperm that showed a progressive move forward (Table 1).

Electroejaculation produced an ejaculate with pinkish color, which was different from the creamy turbid ejaculates obtained by the other procedures. This sample was contaminated by red blood cells, as indicated by microscopic assessment. The pH value (6.9-7.0) was similar between the "non-invasive" semen collection procedures, while electroejaculation samples had a markedly higher pH of about 8.7.

## DISCUSSION

Although only a limited number of ejaculates could be obtained, the study provided the first data on the characterization of fresh ejaculates obtained from varying

Table 1. Seminal parameters (range) for various collection methods from the Sumatran rhinoceros

Method	$\Sigma$ ejaculates	Volume (ml)	pH	Color	Sperm conc. ( $\times 10^3$ /ml)	Motility (%)	Abnormality (%)
AGM, PM, and AV (n = 7)	6	1.2-12.4	6.9-7.0	Whitish turbid	0-167	1	30-80
PM and AV (n = 4)	2	1.5-2.1	6.9-7.0	Creamy turbid	143-333	1	5-30
PM (n = 4)	1	1.5	6.9	Whitish turbid	0	n/c	n/c
Electroejaculation (n = 1)	1	34	8.7	Pinkish	0	n/c	n/c

n/c = data not collected.

semen collection methods in the Sumatran rhinoceros. More importantly, it provided the first comparative information on the value of different stimulation protocols for collecting semen in this species. Single stimulation using rectal massage

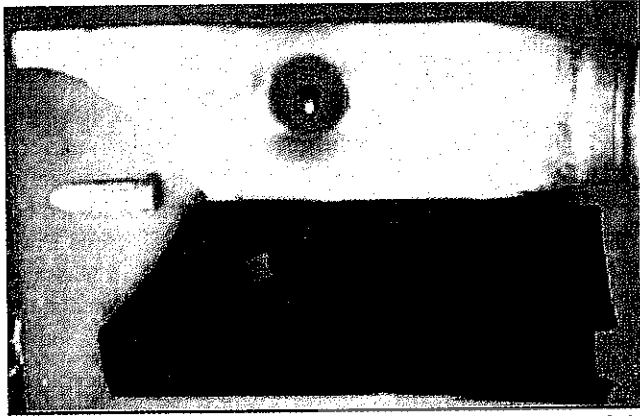


Figure 1. Water-filled latex AV for stimulation of distal tip of the penis.




Figure 2. Electroejaculator and the probe for electroejaculation procedure to collect semen in the Sumatran rhinoceros.

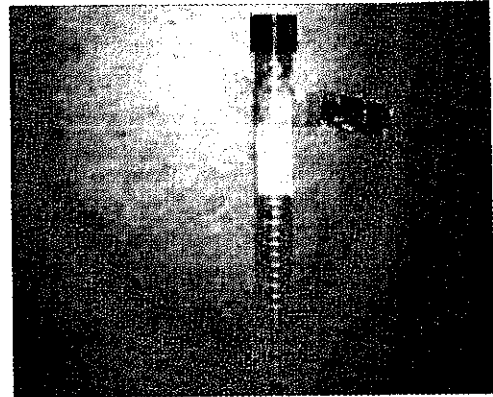


Figure 4. Semen collected from the Sumatran rhinoceros at SRS Way Kambas, Lampung, Indonesia.




Figure 5. Sumatran rhinoceros sperm: (a) sperm with a proximal cytoplasmic droplet, (b) sperm with bent tail (from native smear) (40 x 10).




Figure 6. Sperm with broken tail in several forms; (a) sperm with proximal cytoplasmic droplet, (b) sperm with bent tail, (c) sperm with broken tail (from dip-quick smear) (100 x 10).



Figure 3. A sequence of rhinoceros semen collection using a combination of (a) accessory glands massage, (b) penile massage, and (c) artificial vagina.

(accessory glands massage, AGM) only was not used in the present study because Schaffer *et al.* (1990) reported that although this procedure could produce seminal emission, the stimulation was not sufficient to cause ejaculation in the Indian rhino. In line with this, for the beef bull, Palmer *et al.* (2004, 2005) reported that the rectal massage enabled to stimulate erection and contributed to poor semen sample quality. Although, it appears that AGM alone is not an effective method for stimulating ejaculation, many researchers used it as a prime procedure in combination with other stimulation techniques in wild animals, e.g. penile massage in Ceylon elephant (Jainudeen *et al.* 1971), or AV in Asiatic elephant (Heath *et al.* 1983).

In the present study, three "non-invasive" semen collection methods differed in stimulation (penile massage, PM; PM in combination with an artificial vagina, AV; and PM in combination with accessory gland massage, AGM and AV) and the invasive procedure of electroejaculation were tested for their usefulness in obtaining ejaculates in the Sumatran rhinoceros. The results indicated that the success rate in terms of obtaining an ejaculate progressively increased with the intensity of the stimulation, with the highest success rate (86%) being found when all three stimulation procedures (AGM, PM, AV) were combined. The combination of AGM, PM, and AV resulted also in generally higher ejaculate volumes. The combination of these techniques was also reported to work well in terms of obtaining proper ejaculates in elephant (Heath *et al.* 1983), and domestic animals (Hafez & Hafez 2000; Palmer *et al.* 2005). In contrast, Schaffer *et al.* (1990) reported that the AV procedure was not able to provide a proper ejaculate, in the Indian rhinoceros since sperm concentrations in the samples using AV were low. Similarly to this, sperm concentration was also generally lower in ejaculates obtained in the present study using AGM compared to when only PM in combination with AV was used. Since the proportion of abnormal sperm was lower in ejaculates obtained without AGM, these preliminary data may suggest that although success rate and ejaculate volumes are lower using PM and AV only, the ejaculates obtained by this procedure might be of better quality. In line with this result, Palmer *et al.* (2005) reported that the semen collected by AGM in beef bull may have contained more residual (dead) sperm and contributed to poor semen sample quality. The combination of AGM, PM, and AV produced better results in terms of success rate of the ejaculation and the ejaculate volume, suggesting that the use of AV presumably increased stimulation of the animal to produce an ejaculate. More trials with other male Sumatran rhinoceros are, however, needed to investigate this further.

Electroejaculation is the most commonly used method for collecting semen from domestic species (Roth *et al.* 2005). However, Schaffer *et al.* (1990) reported that the method does not produce proper ejaculates in the rhinoceros that can be used for cryobanking or assisted reproduction. Nevertheless, in a recent report, Hermes *et al.* (2005) indicated that use of a specially designed rectal probe during electroejaculation can improve the effectiveness of semen collection in the African white rhinoceros species and this was confirmed by a study

of Roth *et al.* (2005) in the African black, African white and Indian rhinoceros. In particular, the electroejaculator stimulates an optimal erection and ejaculation process, and, due to high stimulation of semen plasma secretion (Hafez & Hafez 2000) the technique usually results in the production of higher ejaculate volumes compared to other techniques. Despite a 3-20 fold higher ejaculate volume found in the present study, no single sperm was observed in the sample obtained by electroejaculation. In comparison to studies in other rhinos, it thus appears that the procedure of electroejaculation is of only limited value for collecting semen in the Sumatran rhinoceros. Since the present data are extremely limited and therefore more studies are required to clarify whether this is really the case.

The results showed that the male Sumatran rhinoceros at SRS produced very low ejaculate volumes (1.5-34 ml semen/ejaculate) and very low sperm concentrations ( $133-333 \times 10^3$  spermatozoa/ml ejaculate). In contrast, in the other rhinoceros species ejaculate volumes of 20 to 200 ml, and sperm concentrations of about  $1.8-75.8 \times 10^6$  spermatozoa/ml ejaculate have been reported using different collection methods (Schaffer *et al.* 1990; Hermes *et al.* 2005; Roth *et al.* 2005). On other male Sumatran rhinoceros housed in Cincinnati Zoo, an ejaculate recovered post-coitus was shown to be as large as 104 ml and contained a sperm concentration of  $25 \times 10^6$  spermatozoa/ml (O'Brien & Roth 2000). Ejaculate volume and sperm concentration of Torgamba were also much lower compared to horse, which can produce ejaculate volumes of about 20-100 ml and sperm concentrations of  $120-300 \times 10^6$  spermatozoa/ml ejaculate (Janett *et al.* 2003a,b; Turner & McDonnell 2003). It thus appears, that the male Sumatran rhinoceros at the SRS suffers presumably from an abnormality in semen production, so called oligospermia and oligozoospermia (Hafez & Hafez 2000).

Moreover, analysis of sperm motility and morphology indicated that the male appeared to produce a high proportion of less motile sperm and dead sperm as well as with primary abnormalities (a cytoplasmic droplet and abnormal head), and small numbers with secondary abnormalities (detached tail). Interestingly, the abnormality of sperm decreased from 80% at the beginning of the study to 5% after one year. This may indicate that with time and repeated application of procedures, a noticeable improvement in sperm quality (reduced degree of abnormality) in the Sumatran rhino might be achieved, a finding also reported by Schaffer *et al.* (1990) for the Indian rhinoceros. Most of the abnormal sperm had a proximal cytoplasmic droplet, indicating that the sperm that was ejaculated, was immature (Hafez & Hafez 2000; Pesch & Bergmann 2006). The presence of high amounts of immature sperm has also been described in other rhino species (Schaffer *et al.* 1990; O'Brien & Roth 2000). Cytoplasmic droplets, are the most common defect at the neck region, but they can also be found at the midpiece and the principal piece of the tail. They represent a failure of maturation, because normally the residual cytoplasm is released down the tail during spermiogenesis. Proximal droplets are thought to have a great impact on fertility and therefore are classified as major defects

(Pesch & Bergmann 2006). Similarly, the defects found in the sperm head (i.e., micro- and macrocephalic) were presumably associated with abnormal spermiogenesis, furthermore indicating sub- or even infertility as often reported in stallions (Pesch *et al.* 2005) and ram (Ott *et al.* 1982). The reasons for this phenomenon are thought to be various, e.g., prolonged sexual rest (Blom 1945 in Pesch & Bergmann 2006), cell death (Austin & Bishop 1958), and the fixation for morphological evaluation (Hurtgen & Johnson 1982).

For Torgamba, it is likely that the first explanation applies because the rhino has not mated since he was young when captured until at the age ~25 years when the first ejaculate was observed in 2002 during his first natural mating. The reason for low fertility in this male remains unknown, therefore it is necessary to assess the causes, i.e. whether there is an ejaculatory failure, or testicular failure to produce proper sperm and/or problems in sperm transport. This can be done using the alkaline phosphatase activity test as described (Turner & Sertich 2001; Turner & McDonnell 2003). Alkaline phosphatase (AP) activity in ejaculatory fluid is an accurate marker for true ejaculation in stallions with severe abnormalities of these testes and epididymides. Turner and Sertich (2001) reported that AP value > 1,000 IU/l suggests true ejaculate; < 100 IU/l suggests ejaculatory failure or blockage; 100-1,000 IU/l may indicate partial ejaculate or partial blockage in horse.

It is concluded that (i) the study has provided the first data on the characterization of the fresh ejaculates obtained from artificial semen collection methods; (ii) a combination of AGM, PM, and AV yielded a higher success rate in stimulating ejaculate compared to the other collection methods, however, semen quality appeared to be better when PM and AV without AGM was used; (iii) in comparison to other rhino species using the same semen collection methods, the volume of ejaculates and sperm concentration were very low; (iv) the results indicate that the male Torgamba presumably has a low fertilization capacity as a result of low sperm concentrations called *oligozoospermia* and low ejaculate volume, so called *oligospermia*. It is suggested to find out factors affecting the low fertility of Torgamba by using the alkaline phosphate activity test.

#### ACKNOWLEDGEMENT

We thank the International Rhino Foundation for providing financial support of the study. I would like to express our gratitude to the board of the Suaka Rhino Sumatra Foundation for getting an access to the animal. Sincere thanks are addressed to the Directorate General of Higher Education, Ministry of National Education of the Republic of Indonesia for scholarship support. Special thank is addressed to Terri L. Roth from Cincinnati Zoo for providing an electroejaculator machine and her assistance in conducting electroejaculation technique on the Sumatran rhino.

#### REFERENCES

- Austin CR, Bishop MWH. 1958. Some features of the acrosome and perforatorium in mammalian spermatozoa. *Proc Reprod Soc* 149:234-240.
- Colenbrander B, Gadella BM, Stout TA. 2003. The predictive value of semen analysis in the evaluation of stallion fertility. *Reprod Domest Anim* 38:305-311.
- Colenbrander B, Puyk H, Zandee AR, Parlevliet JM. 1992. Evaluation of the stallion for breeding. *Acta Vet Scand* 88:29-38.
- Hafez ESE, Hafez B. 2000. *Reproduction in Farm Animal*. 6<sup>th</sup> ed. Philadelphia: Lea & Febiger.
- Heath E, Jeyendran RS, Graham EF. 1983. Ultrastructure of spermatozoa of the Asiatic elephant *Elephas maximus*. *Zentralblatt Vet Med Compr Ana Hist Embr* 12:245-252.
- Hermes R *et al.* 2005. Reproductive soundness of captive southern and northern white rhinoceros (*Ceratotherium simum simum*, C.s. cottoni): evaluation of male genital tract morphology and semen quality before and after cryopreservation. *Theriogenology* 63:219-238.
- Hurtgen JP, Johnson LA. 1982. Fertility of stallion with abnormalities of the sperm acrosome. *J Reprod Fert Suppl* 32:15-20.
- Jainudeen MR, Eisenberg JF, Jayasinghe JB. 1971. Semen collection of the Ceylon elephant. *J Repr Fert* 24:213-217.
- Janett F, Thun R, Bettschen S, Burger D, Hassig M. 2003a. Seasonal changes of semen quality and freezability in Franches-Montagnes stallions. *Anim Reprod Sci* 77:213-221.
- Janett F, Thun R, Niederer K, Burger D, Hässig M. 2003b. Seasonal changes in semen quality and freezability in the Warmblood stallion. *Theriogenology* 60:453-461.
- O'Brien JK, Roth TL. 2000. Postcoital semen collection and cryopreservation in the Sumatran rhinoceros (Ds) and application to gamet rescue in the African black rhinoceros. *J Reprod Fertility* 118:263-271.
- Ott RS, Heath EH, Bane A. 1982. Abnormal spermatozoa, testicular degeneration, and a varicocele in a ram. *Am J Vet Res* 42:241-245.
- Palmer CW, Amundson SD, Brito LFC, Waldner CL, Barth AD. 2004. Use of oxytocin and cloprostenol to facilitate semen collection by electroejaculation or transrectal massage in bulls. *Anim Reprod Sci* 80:213-223.
- Palmer CW *et al.* 2005. Comparison of electroejaculation and transrectal massage for semen collection in range and yearling feedlot beef bulls. *Anim Reprod Sci* 87:25-31.
- Penny C. 2005. Practical semen collection and examination techniques for breeding soundness evaluation of bulls. *Cattle Practice* 13:199-204.
- Pesch S, Bergmann M. 2006. Structure of mammalian spermatozoa in respect to viability, fertility and cryopreservation. *Micron* 37:597-612.
- Pesch S, Bostedt H, Bergmann M. 2005. Advanced fertility diagnosis in stallion semen using transmission electron microscopy. *Anim Reprod Sci* (Epub Ahead of Print)
- Radcliffe RW, Ferrell ST, Childs SE. 2000. Butorphanol and azaperone as a safe alternative for repeated chemical restraint in Captive white rhinoceros (*Ceratotherium simum*). *J Zoo Wildl Med* 34:196-200.
- Roth TL *et al.* 2005. Semen collection in rhinoceroses (*Rhinoceros unicornis*, *Diceros bicornis*, *Ceratotherium simum*) by electroejaculation with a uniquely designed probe. *J Zoo Wildlife Med* 36:617-627.
- Schaffer NE, Beehler B, Jeyendran RS, Balke B. 1990. Methods of semen collection in an ambulatory greater one-horned rhinoceros (*Rhinoceros unicornis*). *Zoo Biol* 9:211-221.
- Turner RM, Sertich PL. 2001. Use of alkaline phosphatase activity as a diagnostic tool in stallions with azoospermia and oligospermia. *Anim Reprod Sci* 68:315-365.
- Turner RMO, McDonnell SM. 2003. Alkaline phosphatase in stallion semen: characterization and clinical applications. *Theriogenology* 60:1-10.