

outward extending process seen in *R. bicornis*. Nor is the proximal end so much expanded laterally as in the African species.

The tibial border of the rotular trochlea is greatly developed; it has very nearly reached the extreme modernized stage of development seen in the recent *Rhinoceros* and the horse. The antero-posterior diameter of the distal end is therefore greater than the transverse in approximately the same proportion as in *R. bicornis*.

The patella is triangular in general outline, due to the large development of the internal process in order to cover the greatly developed internal border of the rotular trochlea described above. The trochlear grooves of the patella are quite uneven in size and the bone as a whole unlike that of the horse.

In fully adult and old individuals both ends of the tibia and fibula have a strong tendency to become coössified. This is a direct indication of the progressive development which has reached its culmination in the completely united tibia and fibula of *R. bicornis*. Like the femur, the tibia and fibula are rather long and slender, when compared with these bones in the recent species, and it also appears that

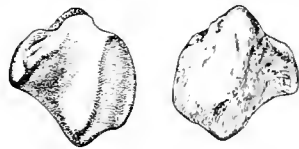

FIG. 37. *Diceratherium cooki* Peterson. No. 1840, Coll. Carnegie Museum. Posterior and anterior views of patella. $\times \frac{1}{2}$.

these bones in *Cænopus tridactylus* (Osborn) are proportionally shorter and possibly also somewhat heavier than in *D. cooki*.

Pes. Pls. LXIII, LXIV. As is already known, the pes is strictly tridactyl. It is on the whole narrow and quite high, especially when compared with *R. bicornis*. It is also somewhat higher and slenderer than the pes in *Cænopus tridactylus*.

The tuber of the calcaneum has about the same general proportions as the European species *D. (?) croizeti* Pomel*, *i.e.*, it is quite heavy and of medium length, while the sustentacular facets are similar in detail. The broad and rather low astragalus also agrees in detail with that of this European form. The cuboid is quite high and has an extremely heavy process posteriorly. The metatarsals are quite elongated, the lateral metatarsals with curved shafts somewhat similar to those in the manus. The ungual phalanges are shorter than in the manus.

The remains of *Diceratherium cooki* constitute by far the greatest percentage of all the material found in the Agate Spring Fossil Quarries. Another significant

* Pomel referred the species to *Accratherium*. Professor Max Schlosser identifies it as *Diceratherium* in the case of material sent to us from the Royal Museum in Munich.

MEASUREMENTS OF THE TYPE OF *D. COOKI*.

Greatest length of skull	350 mm.
Length from occipital condyle to and including P ²	307 "
Length from occipital condyle to M ³	150 "
Greatest transverse diameter of skull	215 "
Greatest transverse diameter of brain-case	107 "
Greatest transverse diameter of frontals	140 "
Transverse diameter of nasals back of horn-cores	65 "
Transverse diameter of nasals at the horn-cores	70 "
Transverse diameter of palate at M ³	55 "
Vertical diameter of the orbit	30 "
Antero-posterior diameter of premolars two, three, and four	68 "
Antero-posterior diameter of the molar series	90 "
Antero-posterior diameter of P ²	22 "
Transverse diameter of P ²	23 "
Antero-posterior diameter of P ⁴	28 "
Transverse diameter of P ⁴	29 "
Antero-posterior diameter of M ¹	34 "
Transverse diameter of M ¹	32 "
Antero-posterior diameter of M ³	26 "
Transverse diameter of M ³	32 "

MEASUREMENTS OF LIMB BONES OF SKELETON.

Scapula, height	273 mm.
Scapula, width at superior border	138 "
Humerus, length	250 "
Ulna, length	315 "
Radius, length	250 "
Carpus, height	59 "
Carpus, transverse diameter	60 "
Mc II, greatest length	70 "
Mc III, greatest length	138 "
Mc IV, greatest length	115 "
Phalanges, median digit	70 "
Pelvis, total length	335 "
Pelvis, diameter across ilia	355 "
Pelvis, Diameter across acetabulum	220 "
Femur, length	323 "
Tibia, length	275 "
Tarsus, height of tuber of calcaneum not included	70 "
Tarsus, length of tuber of calcaneum	48 "
Tarsus, greatest transverse diameter	53 "
Mt. II, length	110 "
Mt. III, length	125 "
Mt. IV, length	110 "
Phalanges, third digit	30 "

fact is the great number of bones representing young animals and females in proportion to those of males. This would appear to indicate (1) that the animals were polygamous to a great degree and that the males were either struggling for the possession of the herds after the manner of recent ungulates (*Equus*), and were few, or, that they were strong enough to extricate themselves when overtaken by the calamities which destroyed the herds.

The articulated skeleton of *Diceratherium cooki* has been fully discussed in the Annals of the Carnegie Museum, Volume VII, pp. 274-279.

MODES OF DEVELOPMENT OF CERTAIN DENTAL AND BONY STRUCTURES OF THE CRANIUM IN DICERATHERIUM.

(Plates LXV and LXVI.)

Important facts, in connection with the evolution of the dental formula and other features of the cranium of the Rhinocerotidæ, are obtained from the large collection under study in the Carnegie Museum. Some studies bearing on the evolution of the incisors and canines of *Diceratherium* were already presented before the Paleontological Society at Pittsburgh in 1910. The following pages are given to a further discussion of the appearance and shedding of the different deciduous teeth, the appearance of the permanent series, and other changes of contour of the head from the young to the fully adult form of *Diceratherium cooki*.

1. A skull of a young *Diceratherium*, No. 1848 (See Pl. LXV, Figs. 1, 2, 4) which belongs to the original series from which the type of *D. cooki* was selected, is especially complete and furnishes an excellent opportunity for study. In viewing this skull from above, the most noticeable characters are the following: brain-case proportionally broad; occiput short; frontals broad; horn-cores little developed, and nasals gradually pointed, more like that of adult females. Back of the horn-cores on the lateral margin of the nasals there is also less constriction in skulls of young individuals and adult females than is the case in males. The supra-orbital ridges are so varied that one cannot attach great importance to them, though it would appear that in female skulls they are generally less prominently developed and in their backward progression to the occiput they possibly have a tendency to be further separated from the median line. On either a direct side view or a palatal view of the young skull the most noticeable feature is the great backward extent of the alveolar border of the maxillary. The alveole for M³ is seen to be nearly opposite the pterygoid, while in fully adult forms this tooth is well in advance of this region. In very young individuals, the base and the supra-occipital of the skull are often slipped off at the sutures, not an unusual feature of the mammalia. In the skull here described, the base is lost, but the supra-occipital is in position.

Buried deep in the small round alveolus, the point of the upper permanent incisor is found. Judging from the size of the alveole, the deciduous tooth was rather small and had a root of more rounded outline than the permanent one, and the crown was perhaps also of an entirely different shape. There is no canine present and, if there were a deciduous canine in this individual, it dropped out early and the alveole was closed, there being in this region a small groove which extends for a short distance back of the maxillary-premaxillary suture. If there was a deciduous first premolar in the *Diceratheres*, it was possibly shed very early in life.³⁰ P¹ is somewhat worn, but not enough to lose the characters of the grinding face. (See Pl. LXV, Fig. 2.) The ectoloph is, as usual, well developed, the protoloph is less prominent than the metaloph, which gives to the tooth the characteristic triangular outline. The post-fossette is sometimes constricted in such a manner as to form an isolated fossette on the metaloph on further wear, while the main post-fossette continues to the posterior edge of the tooth. This fossette is not always present. D.P² is considerably worn, but the detailed structure is yet easily made out. The tooth is longer than the permanent tooth, the ectoloph is heavy, the protoloph is well developed internally as is also the metaloph. The crista is enormously developed, extending on an even internal line with the proto- and metalophs. In a young or unworn tooth this ridge is often constricted so as to form an internal tubercle, which on further wear unites with the true crista. In the young of the John Day forms both the crista and this internal tubercle are less developed and apparently entirely separated, judging from the material in the American Museum. This is admirably illustrated on Pl. LXV Fig. 3. The crochet of D.P² in *D. cooki* is quite distinct though much less developed than the crista, and the cingulum is well developed on the internal face of the tooth. In excavating the maxillary above D.P² it is seen that P² is quite well advanced. See Pl. LXV, Fig. 1. D.P³ is well worn. The median valley is open, but the crochet is evidently united with the ectoloph, while the post-fossette is isolated by wear of the tooth. There is a small tubercle on the internal cingulum in the median valley. D.P⁴ has the well developed crochet still separated from the ectoloph, but the crista is rather poorly developed or wanting. The median valley is open and, as in the preceding tooth, there is a small tubercle on the cingulum at the exit of the valley. The post-fossette is broad and open. M¹ is fully erupted and has already received some wear. The ectoloph is yet quite thin, but in excavating

³⁰ If P¹ in *Diceratherium* did not succeed a milk-tooth in extremely early stages of the animal, this tooth may be regarded as a persistent milk-tooth which would agree with the studies of Huxley ("Anatomy of Vertebrate Animals," p. 362); Lydekker ("Notes on the Dentition of Rhinoceroses," Jour. Asiatic Society of Bengal, Vol. 49, 1880, pp. 135-6).

the median and prefossettes, the walls of the internal face of the ectoloph and the external face of the crochet are rapidly slanting toward one another, so that on extreme wear the tooth would have the usual appearance seen in old individuals of this species. The post-fossette is deep and broad. The cingulum is less developed internally than on the milk premolars. M^2 is just appearing in its alveolus and M^3 is entirely buried in the maxillary.

2. In a somewhat younger individual (No. 2476) it is observed that the roots of $D.P^2$ are longer and heavier and in excavating the maxillary, P^2 is found in an extremely early stage of formation (often no evidence of it is found). M^1 in this individual is just cutting through the alveolar border, while that in the specimen described above has received slight wear. There can be only a comparatively small difference in age of these two individuals, and it thus appears that the permanent teeth developed extremely rapidly after they began to show the form of tooth in the maxillary bone. This rapid formation and development of the permanent dentition in *Diceratherium* should not be regarded as out of the ordinary when comparison is made with the shedding of the deciduous and the appearance of the permanent teeth in man and other mammals.

3. In the collection of the Carnegie Museum are two left rami (Nos. 1820 and 1821) representing very young animals, most probably foetal. The total length of the rami of each of these young specimens is approximately 180 mm., while the depth in the middle antero-posterior region is 28 mm. The most characteristic features are as follows:

The lunate-shaped outline of the ramus due to the greatly downward curved under border of the jaw in the fore-and-aft direction, the close proximity of the cheek-teeth to the canine and the incisors, due to the absence of a diastema on the alveolar border of the jaw, the very slight constriction in front of the cheek-teeth and back of the incisors which is so very pronounced in adult and even in quite young specimens, the small transverse diameter of the symphysis, and the deep groove on the external face of the jaw extending from the symphysis about 20 mm. back in a parallel line with the long axis of the ramus. The glenoid condyle is not present in either one of the rami; the coronoid process on the other hand is present in No. 1820. The latter is rather low, and terminates in an attenuated process.

The second deciduous incisor is in place, while the alveolus for the first is empty. The lateral incisor is not present and a small opening external to $D.I_2$ of this individual may or may not have contained this tooth. The small alveolus for the canine is immediately in front of that for $D.P_1$; the latter is a round opening

of considerable size. The two succeeding round openings are for the roots of D.P₂. Back of this point the two succeeding cheek-teeth are partly erupted. (See Pl. LXVI, Figs. 3, 8 and 9.) The general pattern of these teeth is quite similar to that of the permanent set, indeed it is not easy to distinguish one set from the other. Portions of a fifth cheek-tooth (M₁) lie buried deep in the jaw behind the two just described.

4. Two pairs of lower jaws (Nos. 2476, 2477) have been selected from the collection to represent the next stage of evolution in the development of the ramus, No. 2476 being represented on Pl. LXVI, Fig. 7. The total length of jaws Nos. 2476, 2477 is 250 and 270 mm. and their depth is 36 and 40 mm. respectively. At this stage the jaw is easily recognizable, as all the characteristic generic features are present. The jaw is less lunate-shaped, the characteristic diastema in front of the cheek-teeth is quite well developed, including the constriction of the alveolar border, which in the younger stage is represented only by the deep groove on the external face of the ramus referred to above. In this stage of development the chin is broader, due to the lodgment of the already well-advanced lateral incisor. The temporal fossa is well developed, as are the condyle and the coronoid process.

The median incisors are just through the alveolar border and present the same small and conical-shaped crowns met with in older forms. These teeth are succeeded by a short diastema before the alveoli of D.I₂ is reached. The latter is situated somewhat posterior to I₁ and I₃ in the alveolar border and is thus placed in an irregular position. In the specimens of the Carnegie Museum under observation there is sometimes found a delicate septum separating the second and third incisors. This bony bridge is often broken. D.I₃ is frequently found in position as is the case in the specimen here described, see Pl. LXVI, Fig. 7. This tooth has a long root, quite robust, on which sits a small enamel-covered crown very little larger in circumference than the root itself. The two lateral incisors are succeeded by a diastema; the alveolar border here forms a heavy rounded edge with a noticeable swelling on the external face. This swelling of the incisive alveolar border is due entirely to the rapid development of the cutting incisor of the second set of teeth which is yet buried underneath the deciduous dentition. The deciduous canine is found in many individuals. This is a small tooth with a conical enamel-covered crown and a rather short root. The canine is quite generally found in a procumbent position, isolated by diastemata in front and behind, and drops out very early. The diastema back of the canine constitute a long and sharp border which has first a slight inward curvature and then suddenly takes an outward direction to meet the cheek dentition. The first deciduous cheek-tooth is rather

small, simple-crowned, receives comparatively little wear, and is closely crowded to the anterior face of the succeeding tooth. $D.P_2$ is proportionally longer and narrower than P_2 . The configuration of the crown is otherwise quite similar in the two. $D.P_3$ has by far the greatest wear and is, if one may judge by the degree of wear, the first cheek-tooth to appear in the young. $D.P_4$ is less worn and cuts the alveolar border simultaneously with or perhaps a little sooner than $D.P_2$. Back of $D.P_4$ are seen the points of the crown of M_1 and back of the last-mentioned tooth the alveolar border is deeply marked to indicate the position of M_2 which is still entirely buried in the jaw.

5. The next stage of development in the succession of teeth from the deciduous to the permanent series is interesting. Three individuals have been selected which fairly well cover the main points in individual variation and irregularities of development. Of these three individuals No. 1923*a* might be considered as the most normal and will be first discussed. The small median incisor occupies the usual position, while the permanent lateral incisor has broken through the alveolar border (Pl. LXVI, Fig. 5), uniting the alveoli for $D.I_2$ and $D.I_3$ into a large transversely oblongate fissure for receiving the cutting and procumbent incisor.³¹ In this individual the alveolus for the canine of the right ramus is present, though very small, while in the left there is no trace of an alveolus for the canine. $D.P_1$ is in place while $D.P_2$ has been shed and the crown of P_2 appears through the alveolar border. $D.P_3$ is still in place but P_3 is well advanced and the deciduous tooth was almost ready to drop off before the death of this individual. $D.P_4$ is apparently quite solid in the jaw and still served well for masticating purposes. M_1 has already received considerable wear, while M_2 is almost entirely erupted. M_3 is quite undeveloped and is buried deep in the jaw.

6. The next specimen to be considered is No. 1841, a pair of lower jaws. This specimen presents some irregularities worthy of note. From the illustration (Pl. LXVI, Fig. 6) it is seen that the permanent lateral incisors of this specimen are retarded, *i.e.*, they have not yet appeared above the surface of the alveolar border; the alveoli for the canines are quite large. $D.P_1$ is still in place, but contrary to the specimen just described both $D.P_2$ and $D.P_3$ have disappeared and P_2 and P_3 have already received some wear, $D.P_4$ is solidly inserted in the jaw, M_1 has been in use for some time and is considerably worn as in No. 1923*a*, while M_2 has received slight wear on the anterior portion. M_3 on the other hand is apparently no further developed than in the specimen previously described.

³¹ In the judgment of the writer this incisor is probably I_2 while I_3 and the canine of the *Diceratheres* are atrophied.

7. In No. 1854 it is seen that the lateral incisor is no further advanced than in No. 1841 just described. The alveole or deep groove³² for the deciduous canine is still quite prominent while D.P₁ is shed and all traces of its alveole entirely obliterated. P₂ and P₃ have received slightly more wear than those teeth in the previous specimen described, but D.P₄ is still well rooted in the alveolar border. M₁ is quite well worn and the anterior part of M₂ is also more worn than that in No. 1841. The deep fissure back of M₂ indicates the position of M₃. The latter is very little further developed than in the two preceding specimens and is yet buried in the angle of the jaw. The three lower jaws just described are of approximately the same age as the skull No. 1848, referred to in the opening paragraph of this discussion.

In connection with the probable manner in which the upper and lower incisors of *Diceratherium*³³ developed in size, and modified into the shape in which we find them, it is interesting to return to the foetal specimens Nos. 1820 and 1821 just described (page 452). We have already found that the deciduous dentition of these specimens forms practically a close series, without the constricted and thin areas of the alveolar border between the cheek-teeth and the incisors of older animals, the alveolus for the canine is deep though small; in excavating the chin, the continuation of the dental canal is found, but the germ for the permanent incisor had not yet started, hence the small transverse diameter of the chin.

In the next stage represented by Nos. 2476 and 2477, the specimens are of quite young animals. We observe here a sudden change. It is likely that the characters so prominently developed in this young animal had already been well advanced during the latter part of the intra-uterine stage. At all events the jaw was still in a very plastic condition in order to have transformed so quickly between the two stages represented in the illustrations (see Pl. LXVI, Figs. 7 and 9). In the specimens of this second stage we find a broad and heavy chin in order to support the heavy and long-rooted permanent incisor. The alveolus for the canine, which we originally found quite deep and placed close to the cheek-teeth, is now shifted well forward and is transformed into a shallow groove, which in

³² In more matured individuals, the fissure in the alveolar border which lodged the canine cannot be regarded as a true alveolus.

³³ Not only *Diceratherium* but the Rhinocerotata in general (such forms as the Aemynodonts excepted) undoubtedly developed the cutting incisors along the same general line.

The result of the present study is contrary to the statement by Professor Marsh (Amer. Jour. Sci., Vol. XIV, 1877, p. 251). It may be said here that the presence of the canines in the Aemynodonts does not prove "that the large lower teeth, usually regarded as incisors in *Aceratherium* and many other members of the Rhinoceros family, are really canines."

the majority of cases is empty, the small canine lodged therein having dropped out, while back of the canine we find a long diastema which is very much constricted forming externally a deep and rather broad groove for the lodgment of the inferior labial muscles.

Let us suppose that the foetal specimens referred to have the jaws more or less like those of the early Tertiary forms. We must in any event expect that the early progenitors of the family had, first a complete dental series, *i.e.*, $\frac{3}{3} \cdot \frac{1}{1} \cdot \frac{4}{4} \cdot \frac{3}{3}$ (abundantly proven by the genus *Trigonias* of the lower Oligocene); and secondly quite likely the absence of a diastema back of the incisors.³⁴ It follows that advancing influences effected gradual changes of the bony structure simultaneously with that of the teeth. If we have, for instance, a set of lower incisors of subequal size and a normal canine in its natural position (we actually do find evidence of a canine in young *Diceratheres*), we should expect the upper incisors to meet the lower. When the atrophied and hypertrophied changes took place, which transformed the original sub-equal teeth to those which obtained in later forms, *it was not the lower canine, but I₂, which received the constant impact from the upper median tooth.* The diastemata between the incisors, canine, and cheek-teeth was most likely an early development of the group. The modification of the cutting incisor was cotemporaneous with the reduction of I₁, the atrophy of I₃, the broadening of the chin, and the constriction of the ramus in the region of the canine which, in turn probably, caused the reduction and final disappearance of the latter tooth. After the present study of the *Diceratherinae*, I cannot accept the designation given to this tooth, as "canine," by some authors, Professors Marsh, Cope, and Gaudry having been the first to promulgate this view.

Since the preceding paragraphs were submitted for publication, Professor W. B. Scott of Princeton University has published his splendid work on the "History of Land Mammals in the Western Hemisphere." On consulting the history of the Rhinocerotidæ in Scott's volume, pp. 326-340, it is very evident that he does not regard the large cutting incisor of the lower jaw in the early Rhinoceroses as a canine. In fact since the genus *Trigonias* from the Lower Oligocene of America was established by Mr. Lucas³⁵ and more completely described by Mr. Hatcher³⁶ the morphology of the incisors and canines of the Rhinocerotidæ rests on a firmer foundation.

³⁴ Even in *Colonoceras agrestis* Marsh, a genus which might be regarded as possibly near the ancestral line of the *Diceratheres*, there is a well-established diastema back of the superior canines.

³⁵ Proc. National Museum, Vol. XXIII, 1900, pp. 221-223.

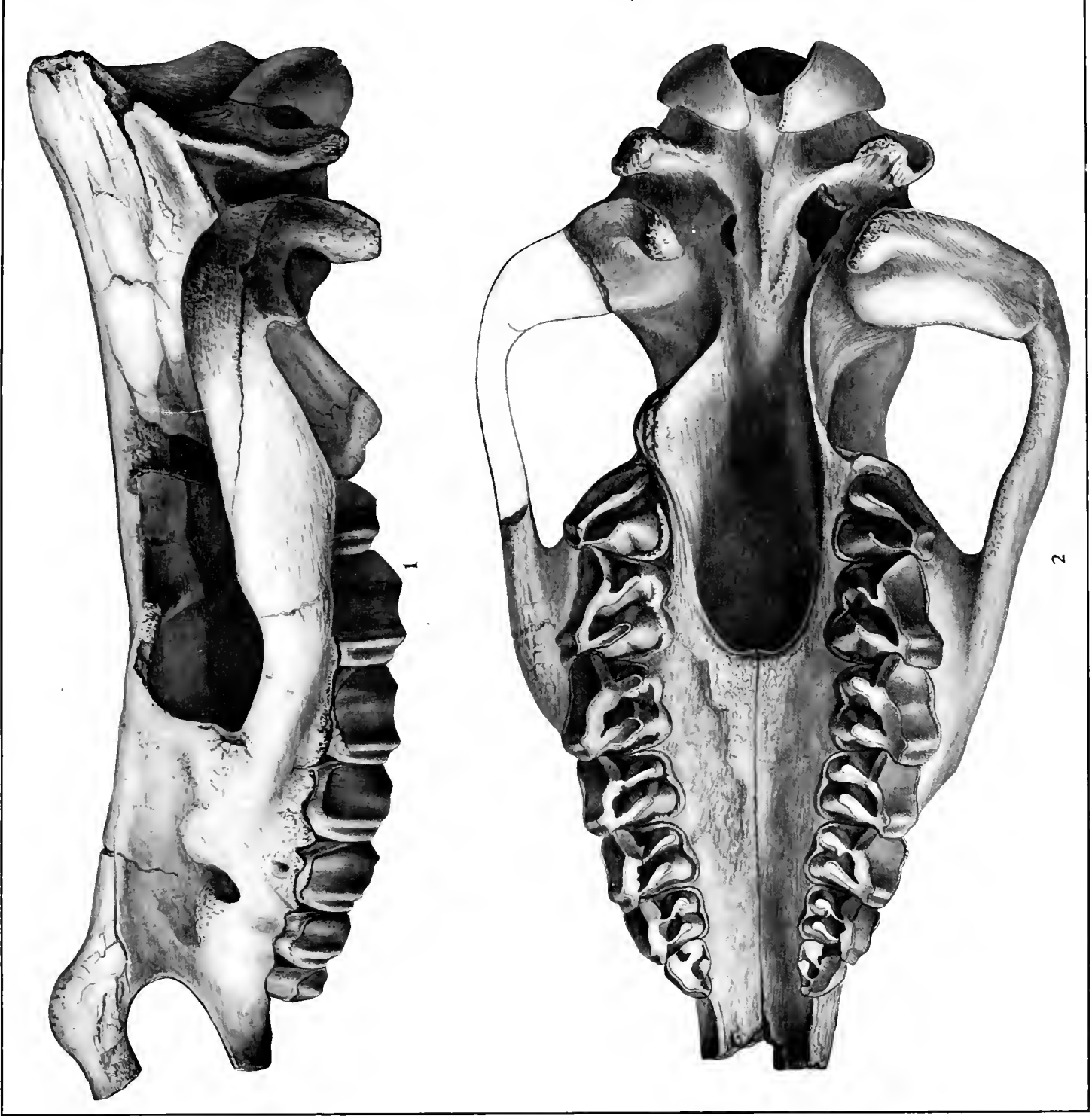
³⁶ Ann. Carnegie Museum, Vol. I, 1901, pp. 135-144.

EXPLANATION OF PLATE LVII.

FIG. 1. *Diceratherium armatum*, type. Side view of skull. Peabody Museum, No. 10003.

FIG. 2. *Diceratherium armatum*, type. Palatal view of same specimen as Fig. 1.

All figures about $\frac{3}{8}$ natural size.



Diceratherium armatum MARSH.

2

1

EXPLANATION OF PLATE LVIII.

FIG. 1. *Diceratherium nanum*, (Marsh) type. Peabody Museum of Natural History, No. 10004. Front of skull from the side.

FIG. 2. *Diceratherium nanum*, type. Front of jaws from the side.

FIG. 3. *Diceratherium nanum*, type. Alveolar border and dentition.

FIG. 4. *Diceratherium cooki*. Carnegie Museum, No. 1555.

All figures $\frac{1}{2}$ natural size.

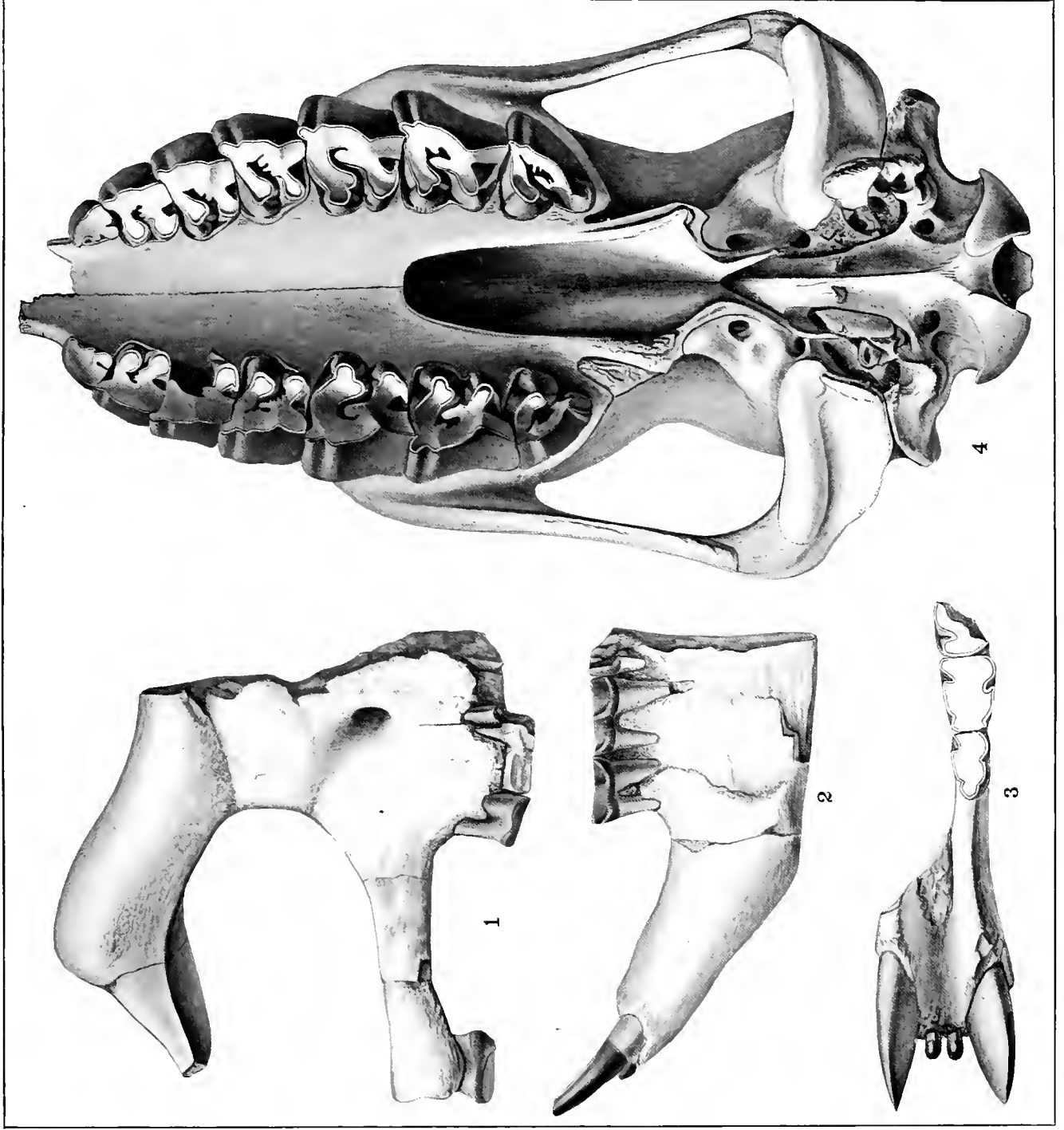


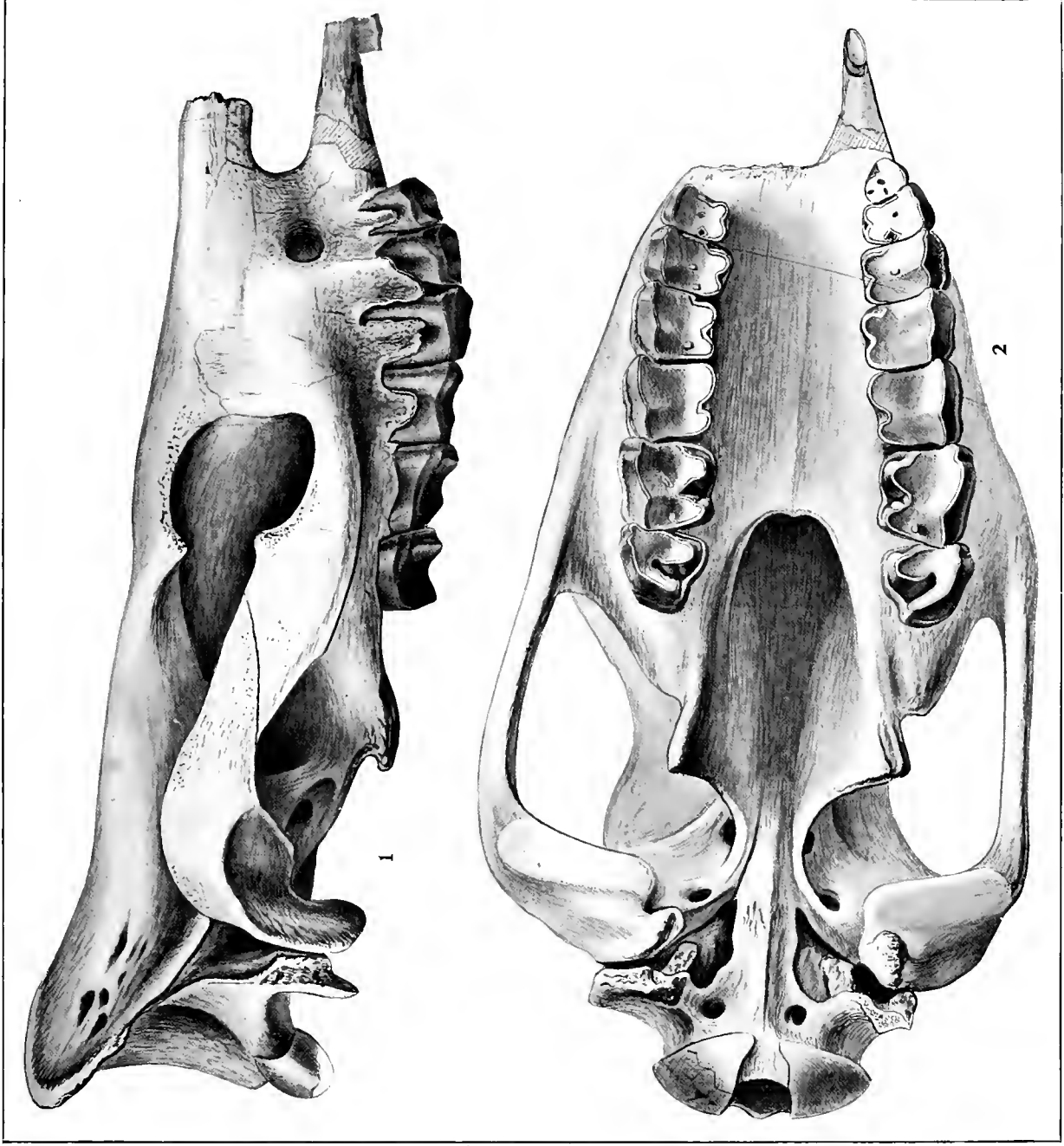
FIG. 1-3, TYPE OF *D. nanum* MARSH; FIG. 4, *D. cooki* PETERSON.

EXPLANATION OF PLATE LIX.

FIG. 1. *Diceratherium gregorii*, type. Side view of skull. American Museum of Natural History, No. 12933.

FIG. 2. *Diceratherium gregorii*, type. Palatal view of the same skull.

All figures $\frac{1}{3}$ natural size.



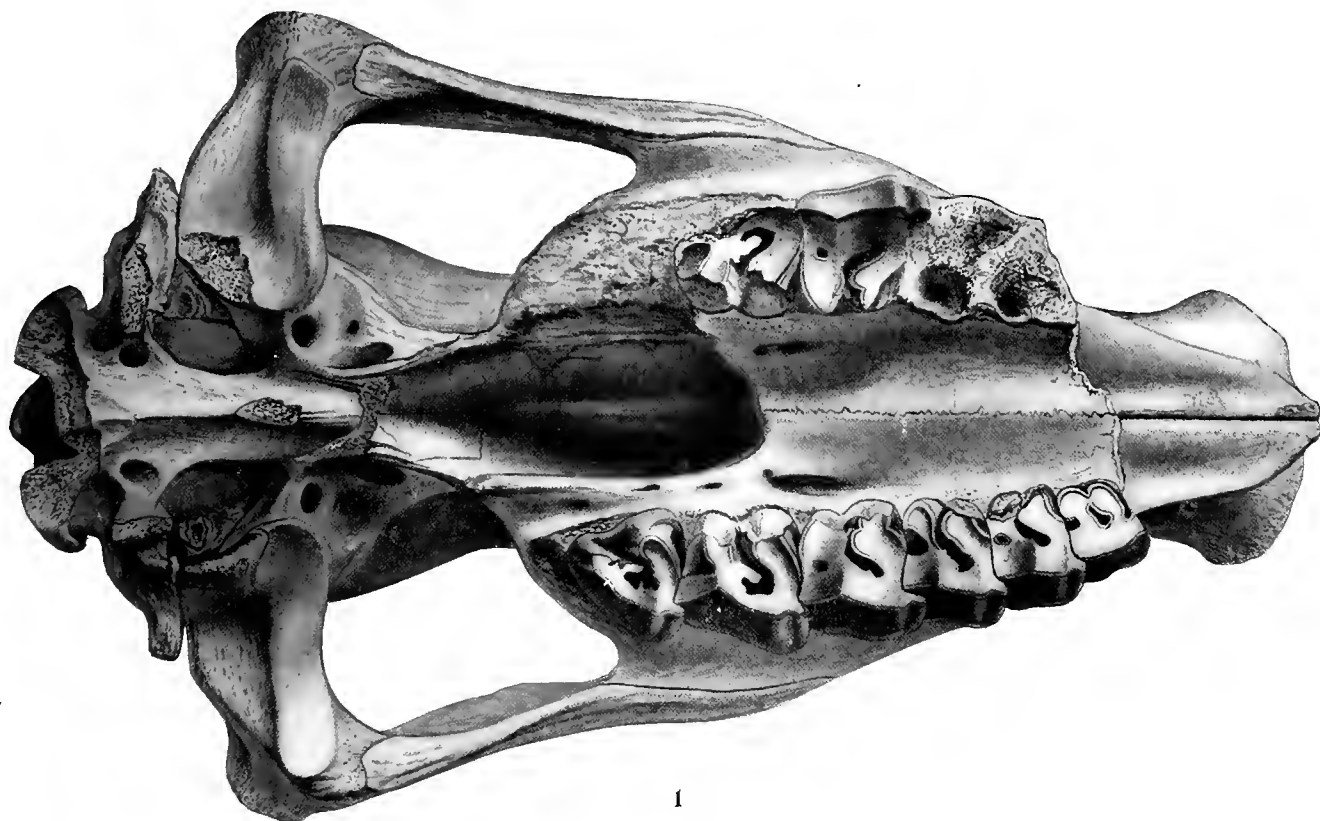
D. gregori peterson.

EXPLANATION OF PLATE LX.

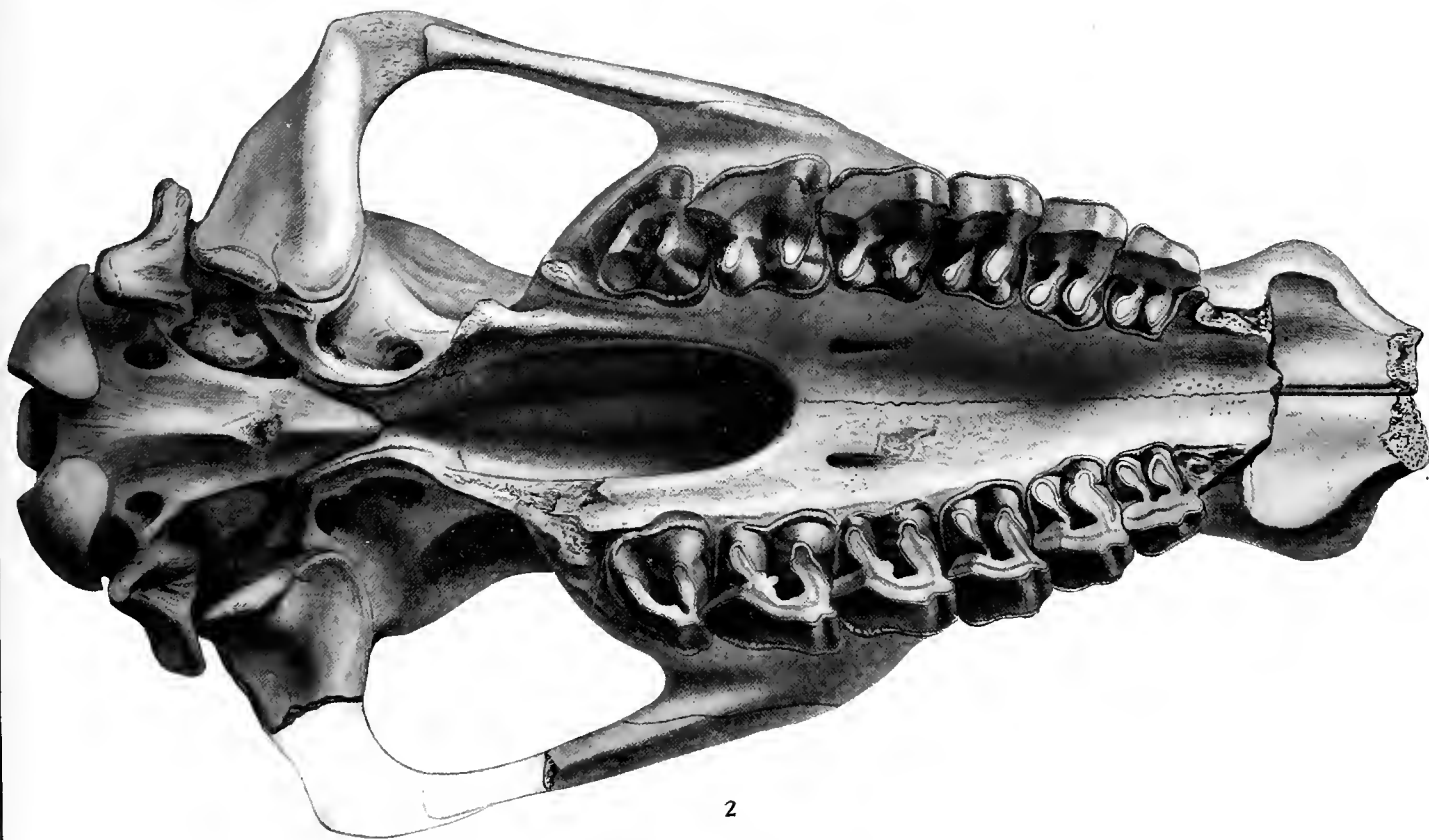
FIG. 1. *Diceratherium cooki* type. Carnegie Museum, No. 1572.

FIG. 2. *Diceratherium niobrarense* type. Carnegie Museum, No. 1271.

Fig. 1, $\frac{1}{2}$ natural size; Fig. 2, $\frac{4}{9}$ natural size.



1



2

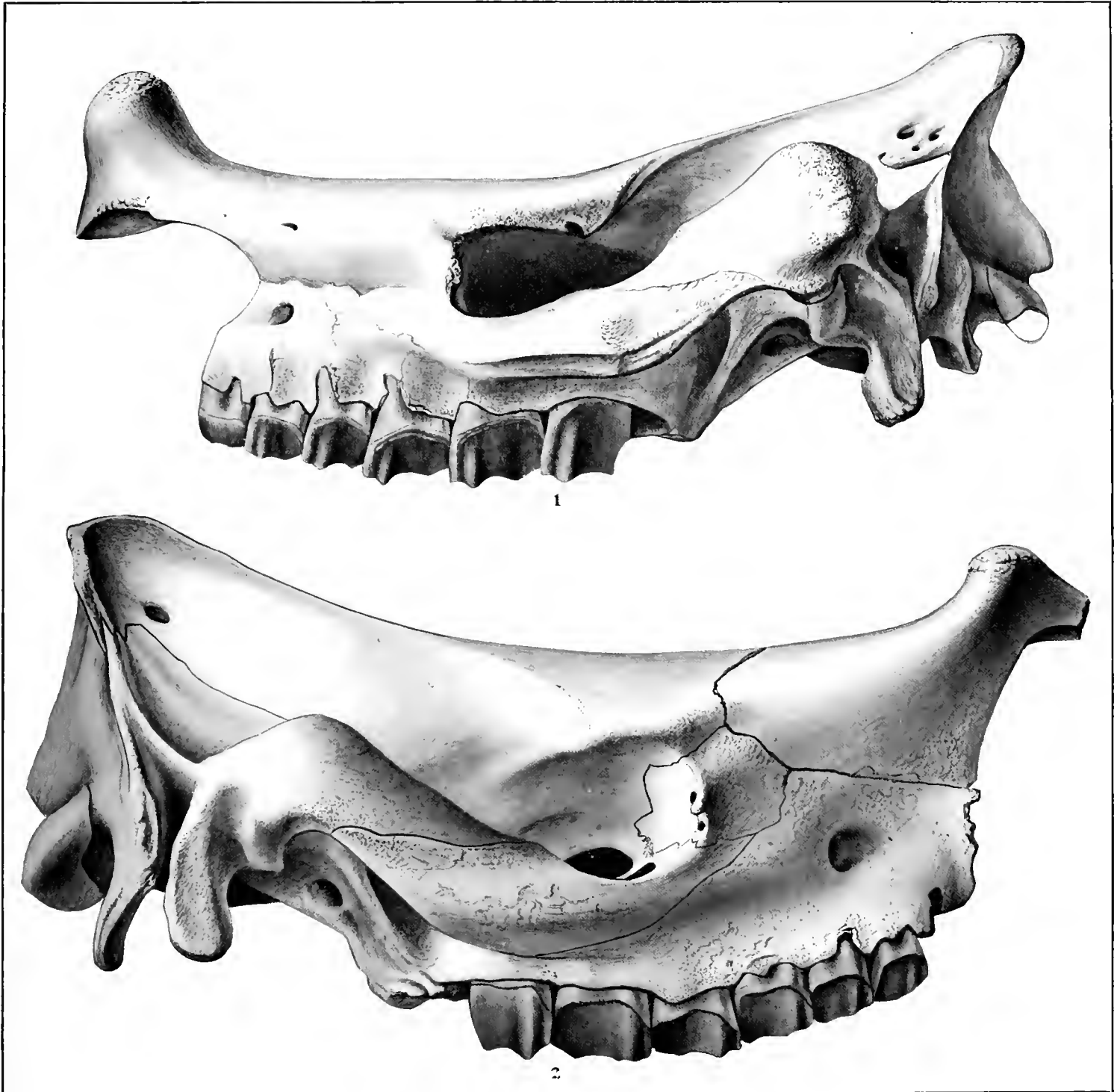D. cooki PETERSON AND *D. niobrarense* PETERSON.

EXPLANATION OF PLATE LXI.

FIG. 1. *Diceratherium cooki*, type. Carnegie Museum, No. 1572.

FIG. 2. *Diceratherium niobrarense*, type. Carnegie Museum, No. 1271.

Fig. 1, $\frac{1}{2}$ natural size; Fig. 2, $\frac{1}{9}$ natural size.



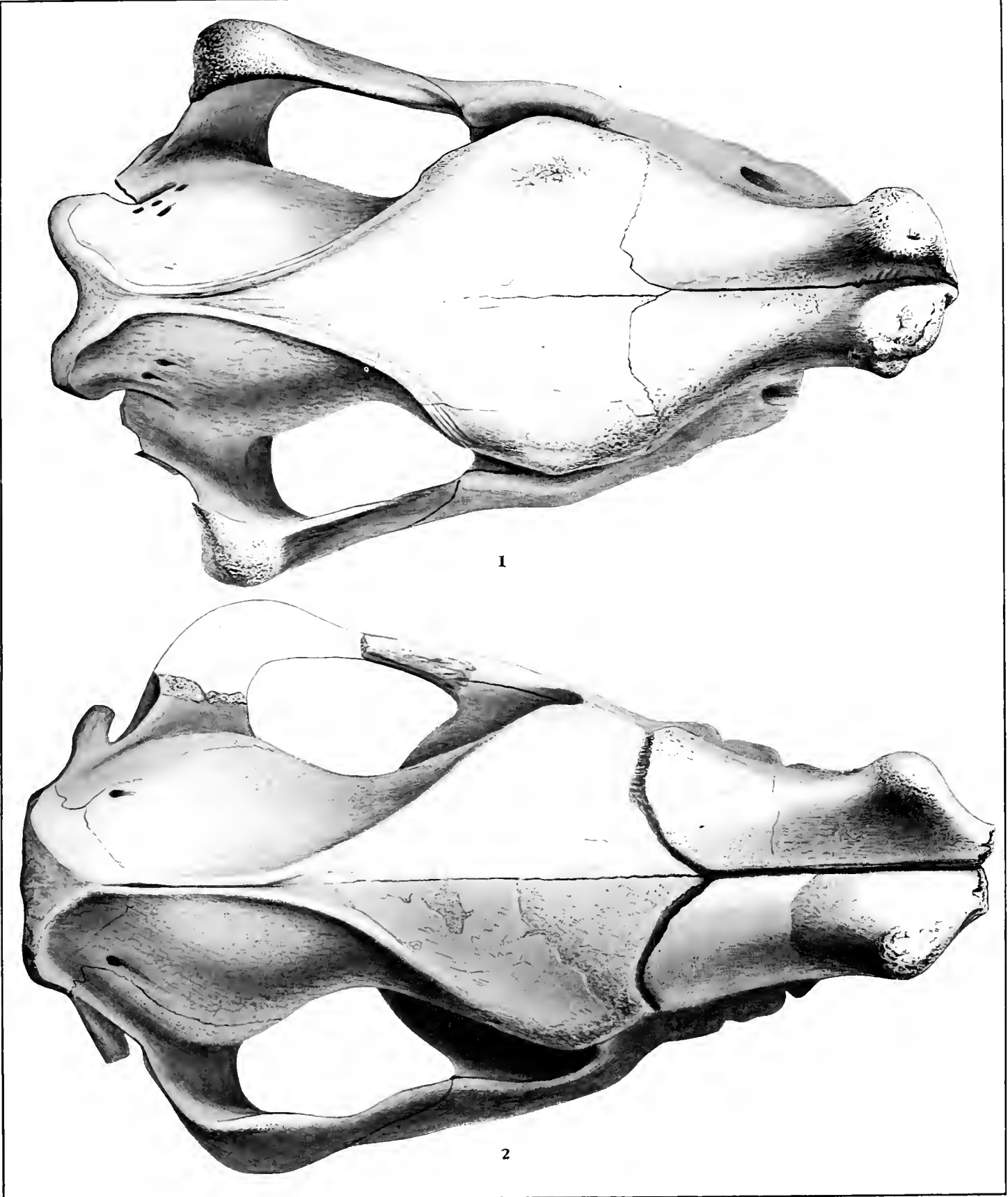
D. cooki PETERSON AND *D. niobrarense* PETERSON.

EXPLANATION OF PLATE LXII.

FIG. 1. *Diceratherium cooki*, type. Carnegie Museum, No. 1572.

FIG. 2. *Diceratherium niobrarense*, type. Carnegie Museum, No. 1271.

Fig. 1, $\frac{1}{2}$ natural size; Fig. 2, $\frac{1}{3}$ natural size.

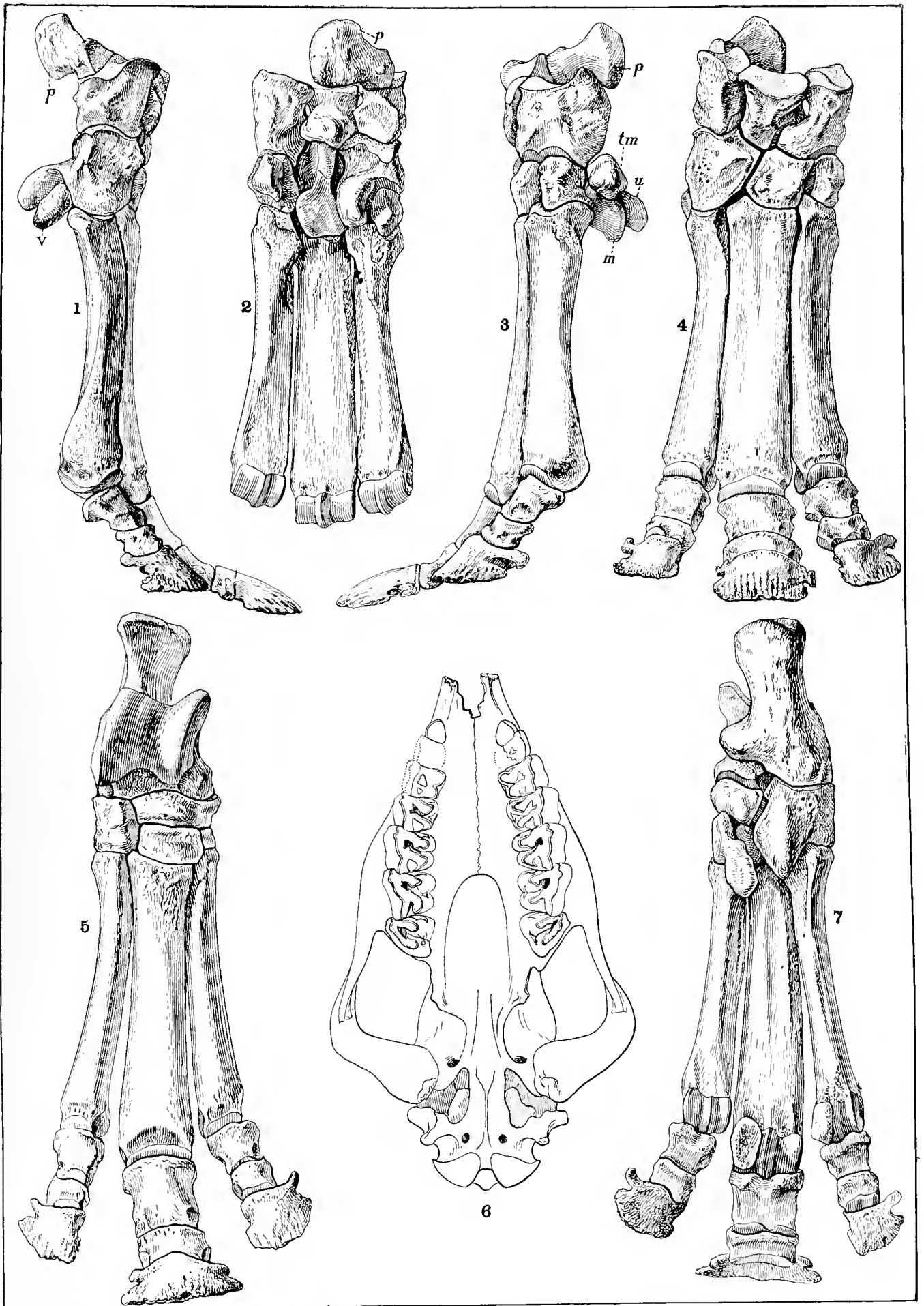


D. cooki PETERSON AND *D. niobrarense* PETERSON.

EXPLANATION OF PLATE LXIII.

- FIG. 1. *Diceratherium cooki*, ulnar view of manus, Carnegie Museum, No. 2473.
FIG. 2. *Diceratherium cooki*, palmar view of manus, Carnegie Museum, No. 2473.
FIG. 3. *Diceratherium cooki*, radial view of manus, Carnegie Museum, No. 2473.
FIG. 4. *Diceratherium cooki*, dorsal view of manus, Carnegie Museum, No. 2473.
FIG. 5. *Diceratherium cooki*, dorsal view of pes, Carnegie Museum, No. 1888.
FIG. 6. *Diceratherium annectens* hypotype, American Museum Natural History, No. 7324, Cope Coll.
FIG. 7. *Diceratherium cooki*, plantar view of pes, Carnegie Museum, No. 1888.

All figures $\frac{1}{2}$ natural size except Fig. 6, which is $\frac{1}{4}$ natural size.



D. cooki PETERSON AND *D. annectens* (MARSH).

EXPLANATION OF PLATE LXIV.

Diceratherium cooki.

Carnegie Museum, No. 1888.

- FIG. 1. Calcaneum, dorsal view.
 FIG. 2. Calcaneum, distal view.
 FIG. 3. Calcaneum, plantar view.
 FIG. 4. Calcaneum, tibial view.
 FIG. 5. Calcaneum, fibular view.
 FIG. 6. Astragalus, tibial view.
 FIG. 7. Ectocuneiform, proximal view.
 FIG. 8. Ectocuneiform, distal view.
 FIG. 9. Ectocuneiform, tibial view.
 FIG. 10. Astragalus, fibular view.
 FIG. 11. Astragalus, plantar view.
 FIG. 12. Astragalus, dorsal view.
 FIG. 13. Cuboid, proximal view.
 FIG. 14. Cuboid, tibial view.
 FIG. 15. Entocuneiform, fibular view.
 FIG. 16. Entocuneiform, distal view.
 FIG. 17. Navicular, distal view.
 FIG. 18. Navicular, posterior view.
 FIG. 19. Navicular, fibular view.
 FIG. 20. Navicular, proximal view.
 FIG. 21. Cuboid, distal view.
 FIG. 22. Mesocuneiform, distal view.
 FIG. 23. Mesocuneiform, fibular view.
 FIG. 24. Mesocuneiform, tibial view.
 FIG. 25. Mesocuneiform, proximal view.
 FIG. 26. Metatarsal III, dorsal view.
 FIG. 27. Metatarsal III, fibular view.
 FIG. 28. Metatarsal II, fibular view.
 FIG. 29. Metatarsal II, tibial view.
 FIG. 30. Metatarsal IV, tibial view.
 FIG. 31. Metatarsal III, tibial view.
 FIG. 32. Metatarsal III, plantar view.

Carnegie Museum, No. 2453.

- FIG. 33. Scaphoid, proximal view.

FIG. 34. Scaphoid, distal view.

FIG. 35. Scaphoid, ulnar view.

Carnegie Museum, No. 2453.

FIG. 36. Lunar, proximal view.

FIG. 37. Lunar, radial view.

FIG. 38. Lunar, distal view.

FIG. 39. Lunar, ulnar view.

FIG. 40. Cuneiform, radial view.

FIG. 41. Cuneiform, distal view.

FIG. 42. Cuneiform, ulnar view.

Carnegie Museum, No. 1853.

FIG. 43. Pisiform, radial view.

FIG. 44. Trapezium, ulnar view.

FIG. 45. Trapezoid, radial view.

Carnegie Museum, No. 2453.

FIG. 46. Trapezoid, ulnar view.

FIG. 47. Trapezoid, distal view.

FIG. 48. Trapezoid, proximal view.

FIG. 49. Magnum, distal view.

FIG. 50. Magnum, ulnar view.

FIG. 51. Magnum, radial view.

FIG. 52. Magnum, proximal view.

FIG. 53. Unciform, radial view.

FIG. 54. Unciform, proximal view.

FIG. 55. Unciform, ulnar view.

FIG. 56. Metacarpal II, radial view.

FIG. 57. Metacarpal II, ulnar view.

FIG. 58. Metacarpal III, radial view.

FIG. 59. Metacarpal III, ulnar view.

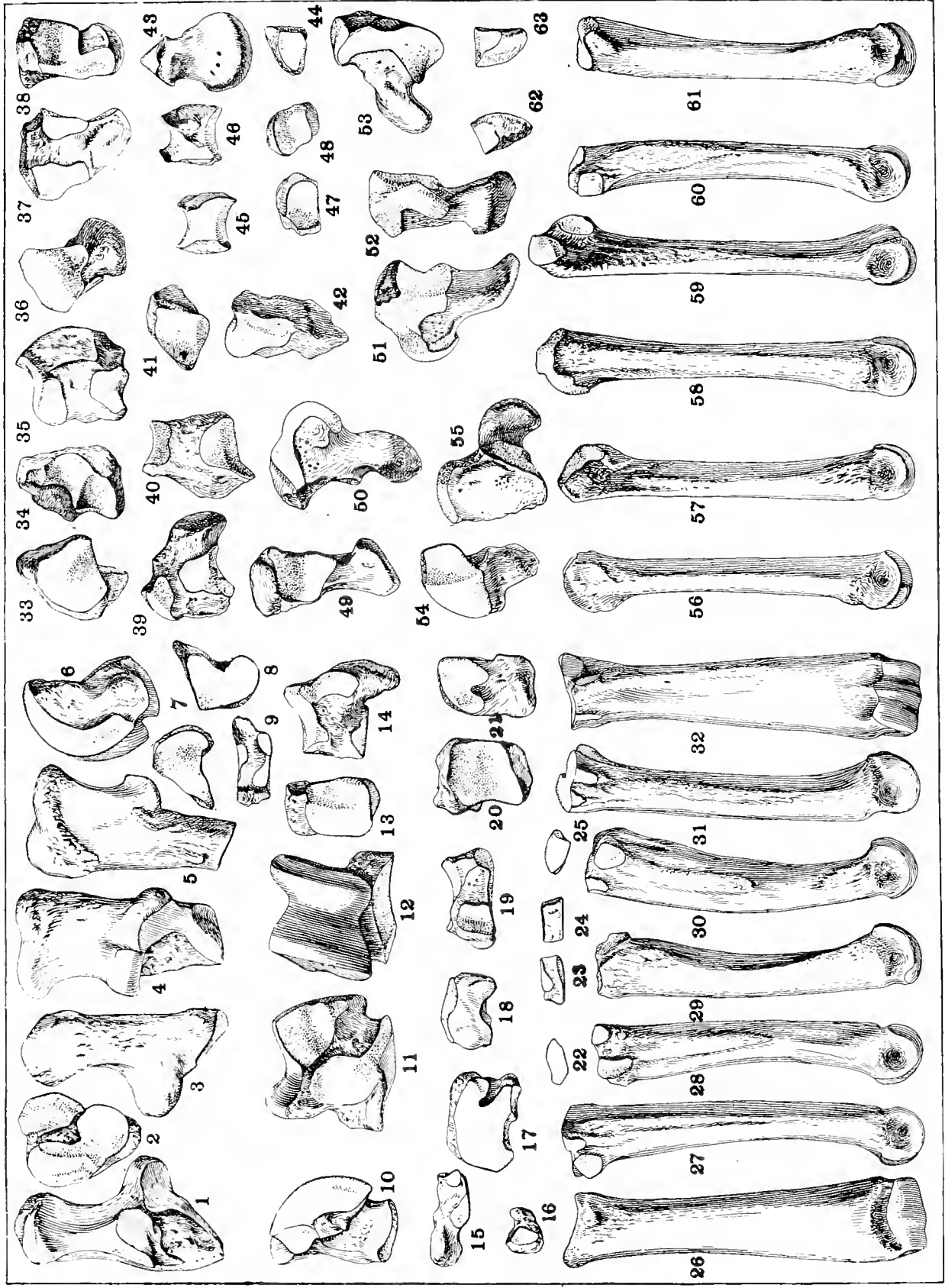
FIG. 60. Metacarpal IV, radial view.

FIG. 61. Metacarpal IV, ulnar view.

FIG. 62. Metacarpal V, radial view.

FIG. 63. Metacarpal V, palmar view.

All figures are $\frac{1}{2}$ natural size.



D. cooki PETERSON.

EXPLANATION OF PLATE LXV.

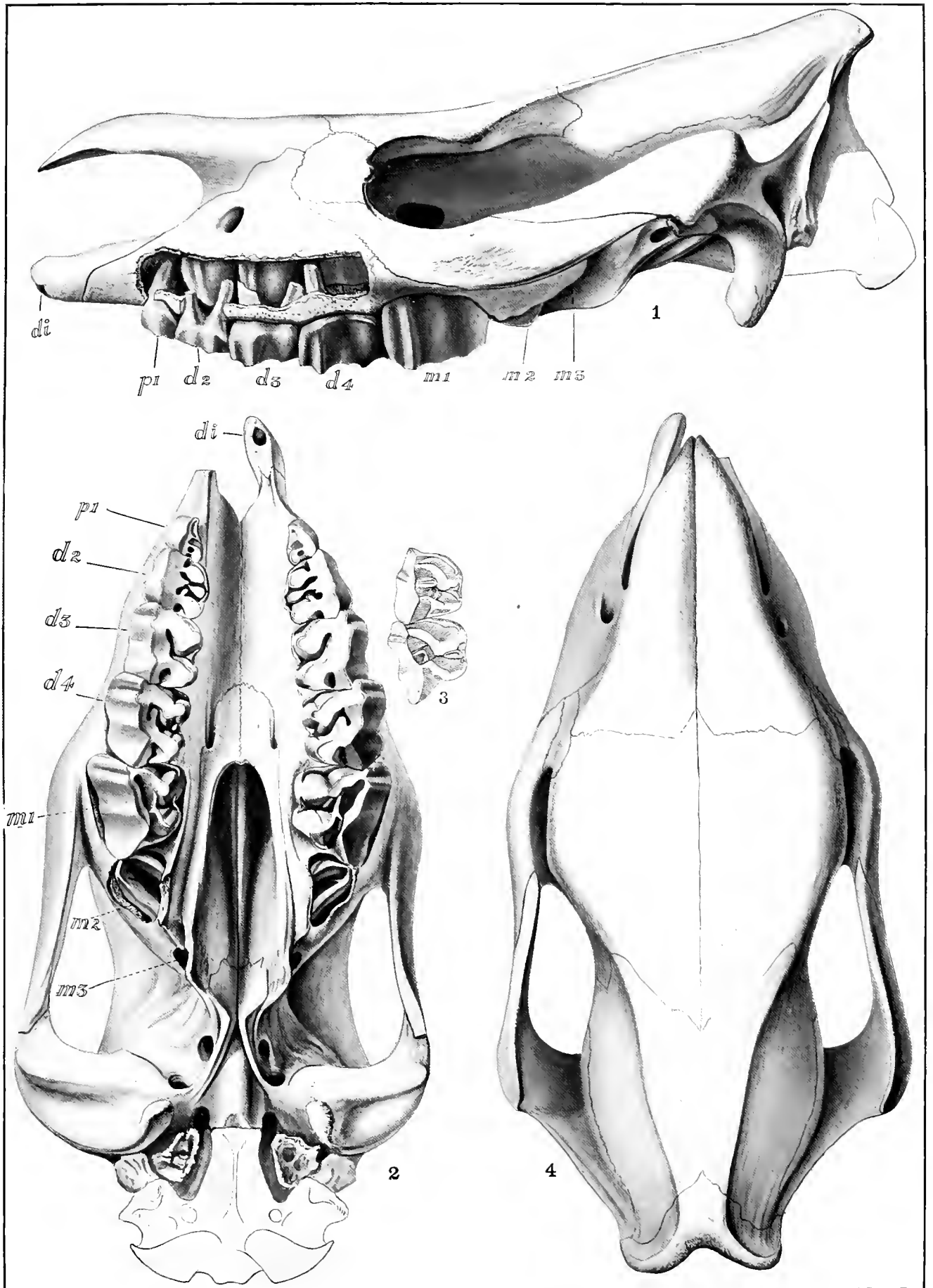
FIG. 1. *Diceratherium cooki*, young male, side view of skull. Carnegie Museum, No. 1848.

FIG. 2. *Diceratherium cooki*, Palatal view same as Fig. 1.

FIG. 3. *Diceratherium? annectens*, deciduous upper teeth, American Museum collection.

FIG. 4. *Diceratherium cooki*, top view of skull, same as Figs. 1 and 2.

All figures $\frac{1}{2}$ natural size.



D. cooki PETERSON AND *D. annectens* (MARSH).

EXPLANATION OF PLATE LXVI.

FIG. 1. *Diceratherium annectens*, hypotype, Side view of skull, American Museum, No. 7324, Cope Coll.

FIG. 2. *Diceratherium cooki*, upper contour of lower jaws and crown view of dentition. Carnegie Museum, No. 2499.

FIG. 3. *Diceratherium cooki*, outer view of mandible in very young stage of development. Carnegie Museum, No. 1820.

FIG. 4. *Diceratherium cooki*, outer view of mandible of fully adult male. Carnegie Museum, No. 2499.

FIG. 5. *Diceratherium cooki*, alveolar border of lower jaw and crown view of dentition. Carnegie Museum, No. 1923a.

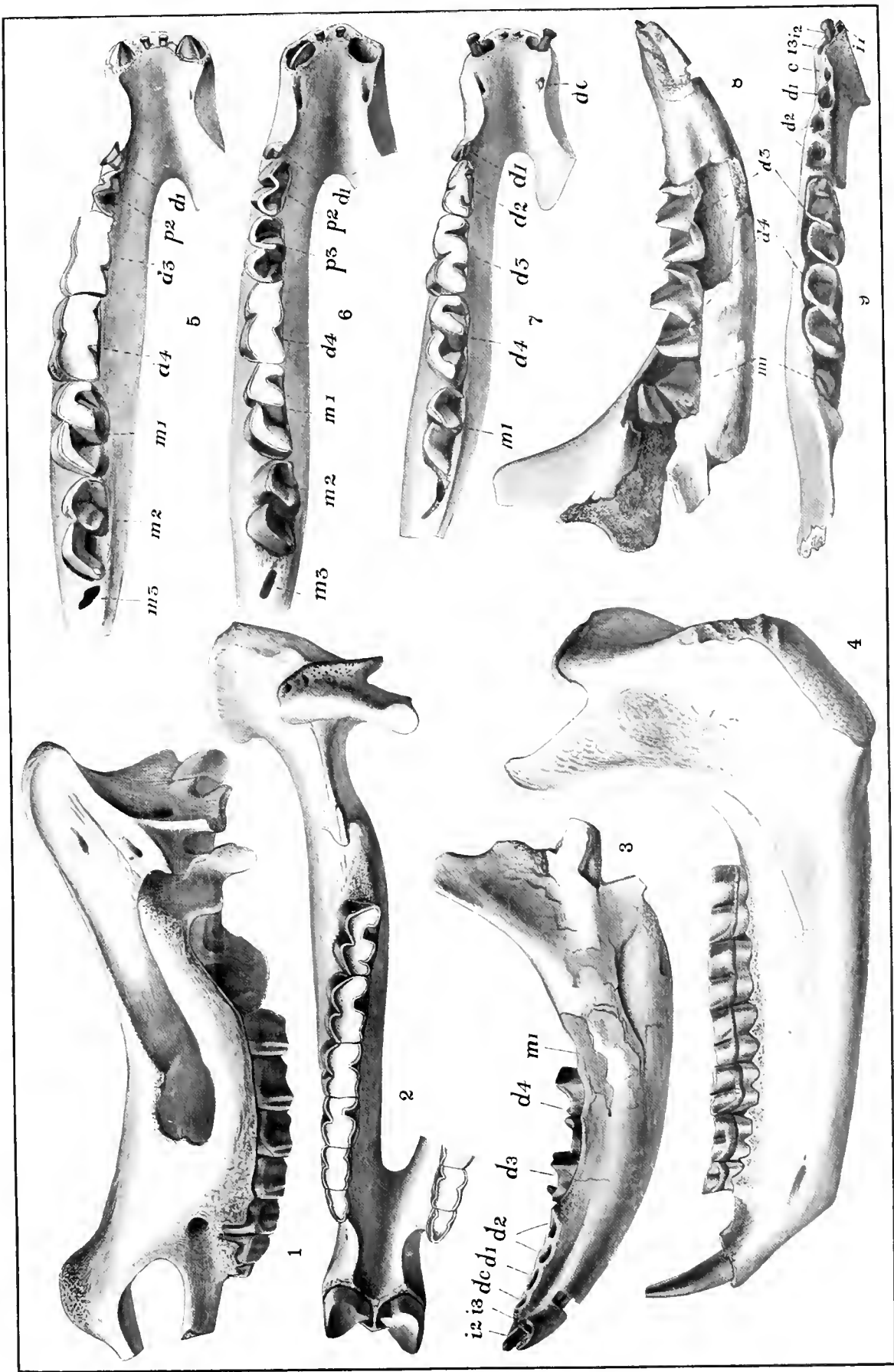
FIG. 6. *Diceratherium cooki*, alveolar border of lower jaw and crown view of dentition. Carnegie Museum, No. 1841.

FIG. 7. *Diceratherium cooki*, alveolar border and crown view of dentition. Carnegie Museum, No. 2476.

FIG. 8. *Diceratherium cooki*, inner view of mandible, very young stage of development, Carnegie Museum, No. 1820.

FIG. 9. *Diceratherium cooki*, upper contour of lower jaw and crown view of dentition, same as Nos. 3 and 8.

Fig. 1 is $\frac{1}{4}$ natural size; Figs. 2 and 4 are $\frac{1}{3}$ natural size; Figs. 3, 5, 6, 7, 8, and 9 are $\frac{1}{2}$ natural size.



D. cooki PETERSON AND *D. amiceus* (MARSHT).

