

Conclusion: Successful surgical intervention is possible in such rare cases arising in wild animals. The etiology behind such cases can vary but in this case one of the important factors was senility so this case presents a ready reference for such cases in future.

Acknowledgement

Special thanks to Mr. A. K. Jha I.F.S., Director, PNHZ Park, Darjeeling for granting permission to undertake the work and Dr. Renuka Sharma, M.V.Sc Scholar (Division of Surgery and Radiology) IVRI, Izatnagar for all the possible required suggestions. Thanks also to Dr. Samir Rai, V.O. SAHC, Darjeeling and my supporting staff for the cooperation in conducting the operation successfully.

References

- O' Connor, J.J. (1980). *Dollar's Veterinary Surgery*; 4th Edition, CBS Publishers and Distributors, India. Pp- 628.
- Tyagi R.P.S & Singh Jit (2002). *Ruminant Surgery*; reprint 2002, CBS Publishers and Distributors, India. Pp- 192-194.

*Veterinary Officer, P.N.H.Z. Park, Darjeeling-734101 Email: darjdeep13@yahoo.com

Uterine Adenocarcinoma in an Indian one-horned Rhinoceros (*Rhinoceros unicornis*)

S.K. Panda¹, I. Nath², P.K. Roy³, A.K. Mishra⁴ and A.K. Pattanaik⁵

The great Indian one-horned rhinoceros is an endangered species. Clearing of natural habitat owing to vast development in the interest of human welfare and poaching for monetary gains has finished up the rhino population from its large distribution range. In most of the zoos there are reports of breeding failure. The male rhinoceros in captivity suffers from low sperm count and females from uterine neoplasms due to sexual inactivity (Sweet, 2004). The present paper describes a case of uterine adenocarcinoma in a one horned rhino.

A 35-year old female Indian one-horned rhinoceros belonging to Nandankanan Zoo had a history of faecal impaction since 2nd week of June 1998. It had recovered with oral laxative, i.e. 2 litres of milk of magnesia administered in feed daily for 7 days. The rhino had chronic intermittent recurrence of loss of appetite and dullness since 2001 which was alleviated by administration of liver tonics and digestive enzymes. In Nov 2004 vaginal bleeding was noted in addition to dyspepsia and constipation. Oral styptochrome tablets 10 nos along with laxative improved the condition. The animal had never conceived during her stay in the zoo. On 20.5.07 the animal was off-feed again. Oral medi-

cation of liv-52 bolus (a herbal liver tonic containing Himsra, Kasani, Arjuna, Kakamachi, Mandura bhasma, Biranjasisha, Jhavuka and Kasamarda, Himalaya Drug Company, Bangalore) and digestive enzyme were offered through feed and ripe banana which she partially accepted. On 26.5.07 she was separated from the male for a better assessment and management. Loss of appetite and constipation continued despite all medication. Parenteral neohepatex (proteolysed liver extract having vitamin B 12 activity, Biological E. Limited, Hyderabad) 10ml was injected through blow pipe. On 27th May the rhino was wallowing in the enclosure but inappetance, dullness, flatulence, tenesmus of anal sphincter and uterine discharge were noticed again, and on 28th May she was found dead (Fig. 1 & 2').

At necropsy, pale lungs with small sized papillomatous growths attached to the border, enlarged heart with endocardial haemorrhage, pale liver with a few necrotic patches, pale kidneys and blood stained fluid in the peritoneal cavity were observed. There were two large growths of about 2 feet diameter on both the uterine horns weighing approximately 25 kg each which occupied most of the abdominal space exerting pressure on the adjacent visceral organs (Fig. 3, 4, 5'). Histologic examination revealed glandular pattern of cuboidal to columnar cells arranged irregularly (Fig. 6'). The mitotic figures were low to moderate. Considering multiple occurrence and highly irregular pattern of the growth it was considered to be an adenocarcinoma.

Reference:

- Sweet, M. (2004). SOS Rhino: In the News: Articles: SOS Rhino Volunteer Report. July-September.

(*See Web supplement for images at www.zoosprint.org)

¹Head, Department of Pathology, ²Associate Professor, Surgery, Orissa Veterinary College, Bhubaneswar, ³Senior veterinary officer, ⁴Assistant Director, ⁵Director, Nandan Kanan Zoological Park, Orissa; E-mail: indravet@yahoo.co.in



Fig. 1



Fig. 2

Fig. 1 & 2. Showing dead Rhinoceros

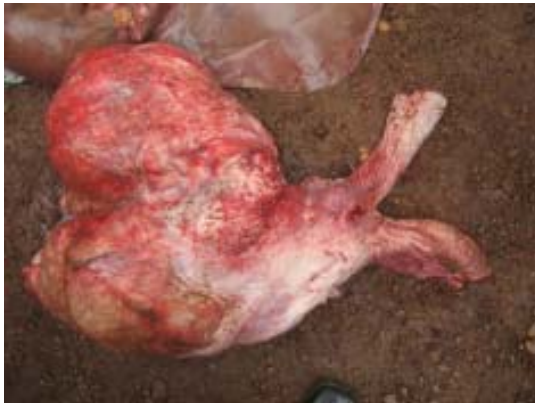

Fig. 3. Showing uterine tumour

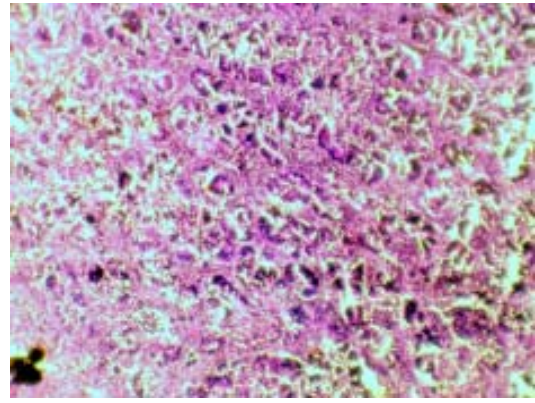


Fig. 6. Photomicrograph of the adenocarcinoma in one horned rhino. Note the glandular pattern of the neoplastic growth H&E 10X

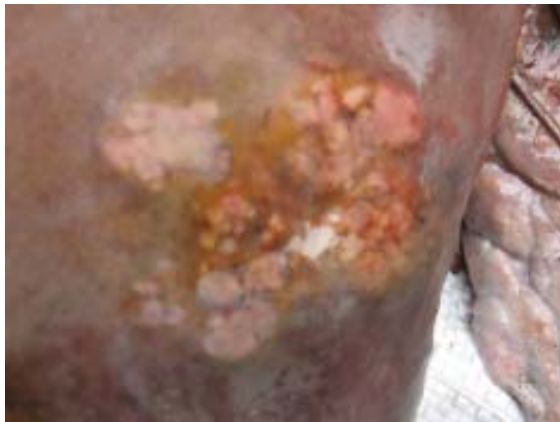

Fig. 4

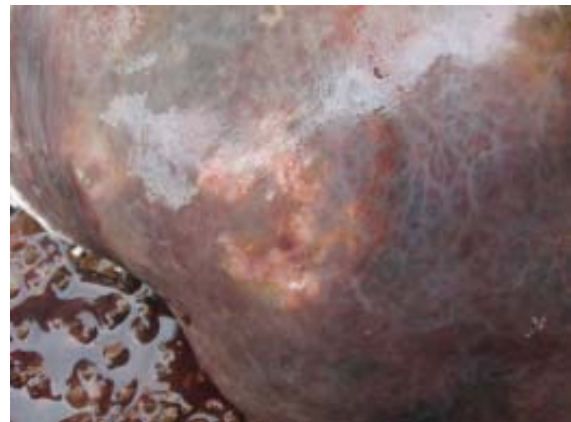

Fig. 5

Fig. 4 & 5. Showing necrotic foci and metastasis in liver