

OBSERVATIONS ON SKIN LESIONS OF THE BLACK RHINOCEROS (*Diceros bicornis* Linn.) IN THE HLUHLUWE GAME RESERVE, ZULULAND.

P. M. HITCHINS and M. E. KEEP

Natal Parks Board.

Introduction

Ulcerative cutaneous lesions containing parasites are commonly observed in the black rhinoceros. Young (1967), quoting Lydekker (1926) and Parsons and Sheldrick (1964), states that these lesions are associated with a state of general debility of the affected individuals. This condition was commonly believed to be of traumatic or glandular origin until Schulz and Kluge (1960) found that a filarial infestation was responsible for these lesions. Investigations were continued in East Africa and the parasite *Stephanofilaria dinniki* was finally isolated and described from the lesions by Round (1964). Tremlett (1964) produced evidence that the pathology of the lesions associated with *Stephanofilaria dinniki* in Kenya resembled those described from Hluhluwe Game Reserve by Schultz and Kluge. Guggisberg (1966) speculated on the exact role of *S. dinniki* in the pathogenesis of the condition and mentioned the possibility that this parasite may only be present as a secondary invader.

Schenkel and Schenkel (1969) postulated that the filarial infection is secondary to wounding by mechanical means, resulting in chronic ulceration.

Field observations on skin lesions have been accumulated from both mature and immature black rhinos in Hluhluwe Game Reserve since 1963.

MACROSCOPICAL OBSERVATIONS

I. Size and locality of lesions.

Skin lesions are found in the regions shown in Fig. 1

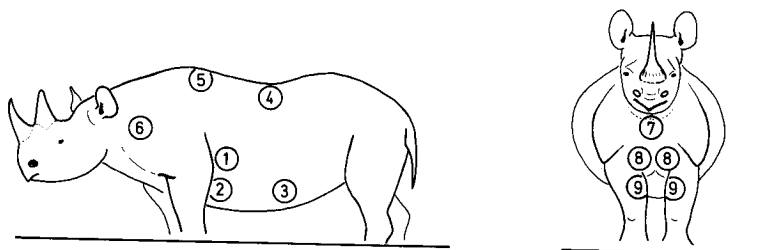


Fig. 1:

Localities of skin lesions on the black rhinoceros.

1. upper side: Most consistent lesion in mature animals, vary in length (measured dorso-ventrally) from 219 to 425 mm. and in breadth (measured antero-posteriorly) from 177 to 330 mm. (Plate 1).
2. lower side: Frequently associated with upper side lesion in mature animals, length 80 to 198 mm. and breadth 47 to 63 mm.
3. abdominal: Rare; a single lesion measured 116 x 132 mm.
4. saddle: Rare in mature animals, length 63 to 104 mm. and breadth 75 to 131 mm. (Plate 2)
5. withers: Common in immature animals, not observed in mature animals, length 121 to 130 mm. and breadth 99 to 110 mm.
6. lateral neck: Occasionally present in mature animals only; single lesion measured 100 x 48 mm.
7. ventral neck: Always present in mature animals, length 132 to 187 mm. and breadth 110 to 432 mm. (Plate 3).
8. chest: Always present in mature animals, length 213 to 245 mm. and breadth 32 to 100 mm. (Plate 3)
9. forelegs: Always present in mature animals, length 234 to 291 mm. and breadth 148 to 229 mm. (Plate 3).

In the text hereafter lesions 1 and 2 are termed side lesions, 4 and 5 back lesions and 7, 8 and 9 front lesions.

2. Appearance.

Three distinct stages of activity of the lesions can be differentiated in the field. The stages and their appearance are as follows:-

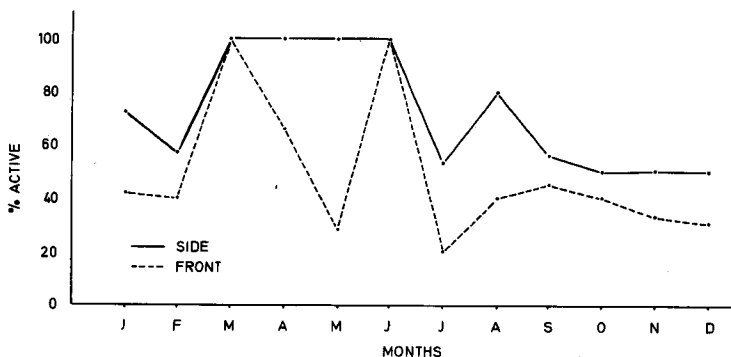
- (a) **active**: characterized by exfoliation, pustule and crust formation, ulceration and haemorrhage. (Plate 4).
- (b) **intermediate**: similar to the active stage but without ulceration and haemorrhage. (Plate 5).
- (c) **dormant**: shows slight crust formation with a roughened mottled appearance due to depigmented areas and scar tissue. In contrast to the surrounding skin al lesion at this stage is much paler in colour. (Plate 6).

3. Seasonal Activity:

Schulz and Kluge (1960) state that skin lesions show seasonal exacerbation; "during the summer they are reddened and accompanied by pruritis and during the winter the lesions recede and become almost unnoticeable."

Taking the population as a whole the plotted observations (Fig. 2) indicate that both side and front lesions in adult animals show activity throughout the year. The data from the period between February and June are probably not a true reflection

due to the low number of animals in the samples. The condition of the lesions shows cyclical changes in specific individuals over a period of time, but this phenomenon does not appear to have any relation to the time of the year.



NO. IN	SIDE	56	7	4	12	8	3	97	34	48	16	6	72
SAMPLE	FRONT	40	5	4	12	7	3	73	12	42	15	6	60

Fig. 2:
Activity of front and side lesions.

4. Development of skin lesions.

Immature black rhinos can be divided into five size classes for each of which age ranges have been established (Hitchins, unpublished). Observations on the incidence of lesions in animals referable to these classes are summarized in Table I.

TABLE I:

Presence of side, back and front skin lesions in immature black rhinos. The figures in parentheses denote number in sample.

Size Class	A	B	C	D	E
Age range of class	0-6 months	6 months-1 year	1-2 years	2-3 years	3-4 years
Front % Lesions	0.0 (16)	22.2 (9)	100.0 (17)	100.0 (18)	100.0 (16)
Side % Lesions	0.0 (16)	0.0 (10)	0.0 (20)	5.6 (18)	37.5 (16)
Back % Lesions	0.0 (16)	0.0 (10)	0.0 (20)	5.6 (18)	62.5 (16)

The front lesions are the first to develop and make their appearance when the animal is between 6 months and 1 year old. At this stage the lesions appear as small depigmented areas on the chest (site 8) and are not noticeable unless studied at close quarters. In animals 1 and 2 years old 58.3% of the lesions were found on the chest, (site 8) 23.5% on forelegs (site 9) and 11.8% on neck (site 7). 5.9% were found on the chest and forelegs simultaneously. From 2 years onwards all three front lesions are present.

The side lesions do not appear until the animal is 2 years old. Between 3 and 4 years old the predominant lesions are those found on the back (62.5%). Of five animals whose ages are known to be between 4½ and 5½ years old all had skin lesions in the normal position behind the point of the elbow. The lesions however were small.

5. External Parasites.

Examination of worms obtained from fresh material from the sites described above proved to be Stephanofilaria dinniki Round. The life cycle of this parasite is unknown, but members of the order to which it belongs require blood-sucking arthropods in order to complete the cycle. Members of the phylum Arthropoda found associated with black rhino skin lesions are flies and ticks. The species positively identified are as follows:-

Flies:

Musca lusoria Wied.
Musca xanthomelas Wied.
Musca cenducens Walk.
Morellia paradoxa Vill.
Rhinomusca dutoiti Zumpt.
Lyperosia thirouxi Roubaud
Haematobia thirouxi Roubaud.

Ticks:

Amblyomma hebraeum Koch
Rhipicephalus maculatus Neumann
R. muhlensi Zumpt
R. appendiculatus Neumann

In addition, two species of birds, the red-billed oxpecker (Buphagus erythrorhynchus) and the pied crow (Corvus albus) have been seen to peck at the lesions. The birds are probably attracted by ticks and loose epithelium, and they are unlikely to be involved in the life cycle of Stephanofilaria.

MICROSCOPICAL OBSERVATIONS

I. Histological Pathology.

Schulz and Kluge (1960) have described the histological appearance of the active, intermediate and dormant stages in detail, and their description will not be repeated here.

Briefly, vascular granulation tissue predominates in the active stage, with engorgement of blood vessels and haemorrhage near the surface epithelium. In the intermediate stage there is a hyperplasia and hypertrophy of the epithelium with crust formation. An increased number of long branching rete pegs extends from the epithelial lining. In the dormant stage there is a reduction in cell content with collagen fibres more prominent. Various degrees of inflammation occur in the underlying dermis.

2. Organisms Present

A. *Stephanofilaria*. Schulz and Kluge (1960) found only larval microfilariae in sections prepared at the active stage, and only mature filariae at the intermediate stage. They also found a few filariae, but no microfilariae in dormant sections.

In our studies Filariae were extracted from fresh lesions (intermediate stage) by soaking the lesion in a normal physiological saline solution for 24 hours. The lesion was then sprayed with a jet of water and the liquid (including saline solution) was examined for the presence of filaria. In all the lesions examined from sites 1, 2, 6, 7, 8, and 9, *Stephanofilaria dinniki* was present.

Samples were taken from five different sites. They were as follows:-

- (a) What was considered to be normal skin from the flank over the last rib. No lesions have been recorded from this site.
- (b) A typical site where side lesions would normally be found, but where no macroscopical sign of lesion formation could be detected.
- (c) A typical side lesion in the intermediate stage.
- (d) A typical chest lesion at the same stage.
- (e) A back lesion in the intermediate stage, three inches lateral to the midline and at the level of the last thoracic vertebra.

Histologically the tissues at sites (a) and (b) were similar and no sign of filariae or microfilariae were found. None of the cellular changes seen at the various stages of lesion development or regression were apparent.

The appearance at sites (c), (d) and (e) was similar in each case, and typical of the intermediate stage. Adult filariae were found at all three sites, principally female worms with their uterine tubes containing either embryonated eggs or developed microfilaria. This showed that the lesions are essentially the same regardless of the site.

B. Bacteria. Smears were taken from sites at various stages. These were stained by Gram's Method and examined. In addition, swabs were taken from the same sites and the bacteria cultured.

Haemolytic and non-haemolytic streptococci and staphylococci were identified as well as small gram negative bacilli. An attempt was made to culture bacteria anaerobically without success.

It is thought that these bacteria are purely a secondary infection, following the primary filarial invasion. The bacterial infection was much heavier in lesions at the intermediate stage than at the active one.

DISCUSSION

Lydekker (1926) and Parsons and Sheldrick (1964) were of the opinion that the cutaneous lesions on black rhinos might be associated with debility of the individual. We have not found this to be the case, since every adult rhino in Hluhluwe Game Reserve, regardless of its physical condition, shows lesions at one stage of activity or another.

Regarding sites 1 to 6, the first lesions to be seen are usually back lesions in positions 4 or 5 (Fig. 1). As the animal matures these become dormant and may finally become unnoticeable. By this time the well-known side lesions in positions 1 and/or 2 have developed. They do not appear to migrate by coalescing and thus bridging the skin areas between back and side lesions.

A black rhino calf was caught at about one year of age, separated from direct contact with all members of its species, and cared for in a boma, within an area inhabited by a population of black rhinos possessing the usual skin lesions. At about 1½ years of age it was moved to a paddock in the company of two square-lipped rhinos. This latter species never shows typical skin lesions, associated with *S. dinniki*. The paddock was situated over one hundred miles from the nearest black rhino. At five and a half years of age the experimental rhino has shown no sign whatsoever of developing skin lesions; on the other hand every animal of this age known to us in Hluhluwe Game Reserve possesses both side and front lesions. It is considered that there were no intermediate host arthropods carrying filarial parasites present to infect this captive animal, and so no lesions have developed. It follows that the filariae are the primary cause of lesion formation. The filariae, and microfilariae which develop, cause a pruritis followed by rubbing and haemorrhage. This attracts blood sucking arthropods to continue the cycle and also produces an excellent site for secondary bacterial invasion. Why the parasite should have a predilection for specific sites is quite unknown, but it is interesting to note that another member of the genus *Stephanofilaria*, *S. dedoesi*, occurring in Celebes and Sumatra causes skin lesions in cattle on the sides of the neck, the withers, dewlap and shoulders. (Mönnig 1947).

SUMMARY

The positions of the various sites at which skin lesions are found on Zululand black rhinos in Zululand are described. Their size, shape and appearance at different stages of development and regression are shown. The development of lesions upon



Plate: 1:

Mature black rhino showing the upper side lesion.



Plate: 2:

Immature black rhino (approx. 5 years old) with the upper side and saddle lesions.

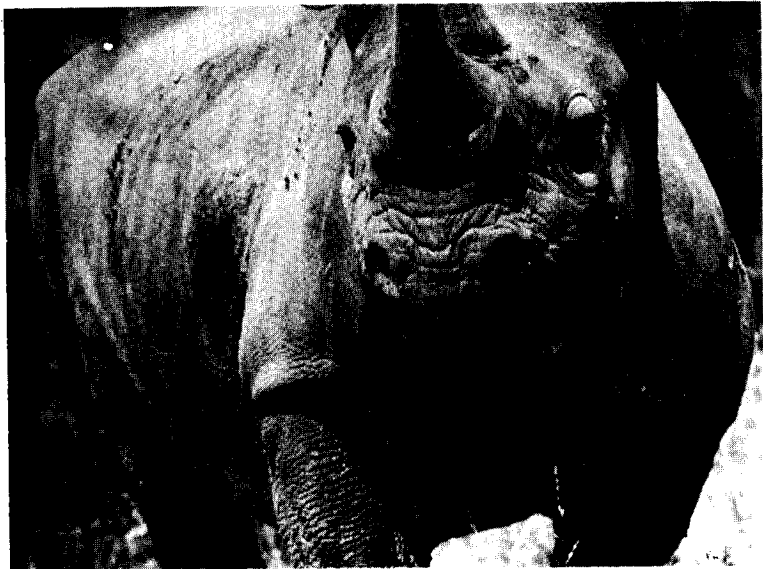

Plate: 3:

Mature black rhino showing positions of ventral neck, chest and foreleg lesions.



Plate: 4:

Lesion at active stage, note haemorrhaging. Flies on lesion are Rhinomusca dutoiti Zumpt.

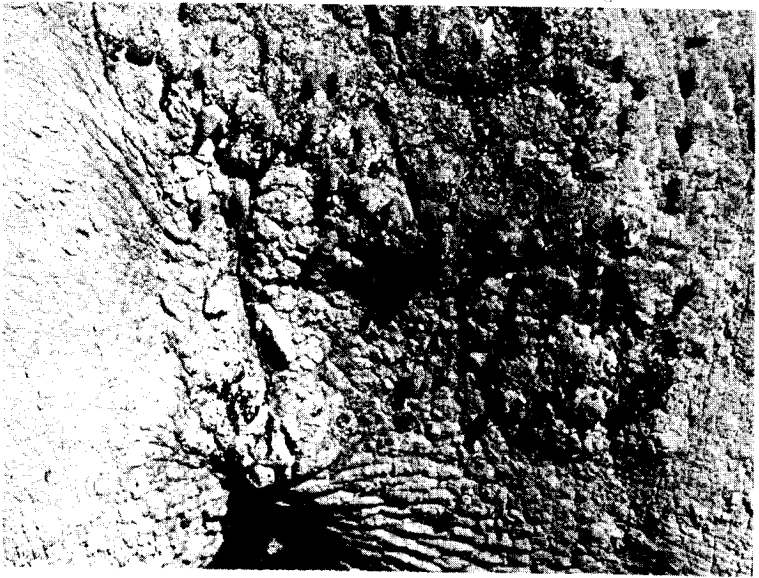


Plate: 5:

Lesion at intermediate stage, note Rhinomusca dutoiti Zumpt on lesion and surrounding skin.

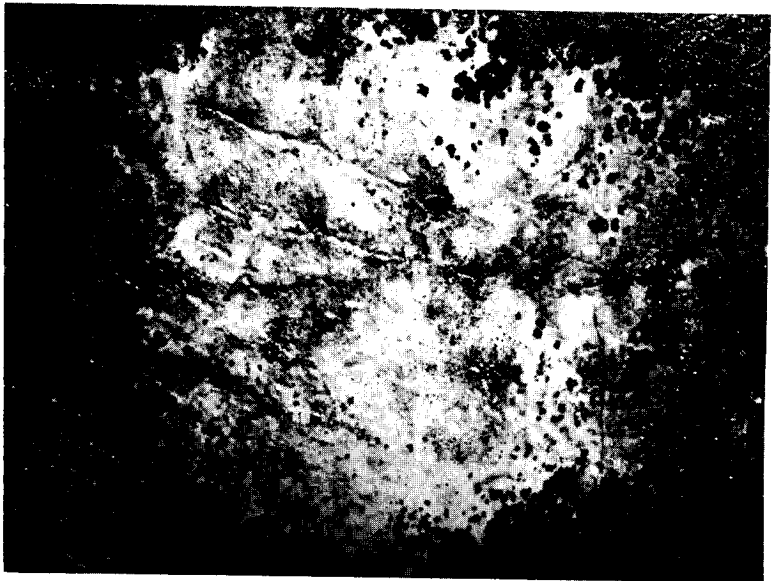

Plate: 6 :

Lesion in dormant stage; showing depigmented areas.

rhinos of various age groups, as well as their seasonal activity, is discussed.

A brief description of the external and internal parasites involved is given, as well as the pathological changes.

ACKNOWLEDGEMENTS

The authors wish to thank the following for their help in making the publication of this paper possible: Miss A. Verster, Department of Parasitology, Onderstepoort Veterinary Research Institute, for confirming the identification of the Stephanofilaria; Miss M. Baker, Allerton Veterinary Laboratory, for the identification of the ticks; Dr. J. H. Mason and Dr. F. Zumpt, both of the S.A. Institute for Medical Research, for bacterial investigation and fly identification respectively; also Major R.M. McCully and Dr. P. A. Basson, Department of Pathology, Onderstepoort Veterinary Research Institute for, histological examination of sections from the lesions, and Mr. J. Vincent, Natal Parks Board for his helpful suggestions and criticisms when reading the manuscript.

REFERENCES

1. Guggisberg, C.A.W. (1966) S.O.S. Rhino. London, Andre Deutch Ltd.
2. Hitchins, P. M. (1970) Field criteria for ageing immature black rhino (Diceros bicornis L.) Lammergeyer, 12.
3. Lydekker, R. (1926) The game animals of Africa. London. Rowland Ward Ltd.
4. Mönning, H. O. (1947) Veterinary Helminthology and Entomology. Bailliere, Tindall and Cox. London.
5. Parsons, B. T. and Sheldrick, D.L.W. (1964) Some observations on biting flies (Diptera, Muscidae, sub-fam. Stomoxydinae) associated with the black rhinoceros (Diceros bicornis L.) E. Afr. Wildl. J. 2: 78-85.
6. Round, M.C. (1964) A new species of Stephanofilaria in skin lesions from the black rhinoceros (Diceros bicornis L.) in Kenya. Journ. Helminth 38: 87-96.
7. Schenkel, R and Schenkel-Hulliger, L. (1969) Ecology and behaviour of the black rhinoceros (Diceros Bicornis L.), A field study. Mammalia depicta; Paul Parey.
8. Schulz, K. C. A. and Kluge, E. B. (1960) Dermatitis in the black rhinoceros (Diceros bicornis) due to filariasis. J.S.A.V.M.A. 31 (2): 265 - 269.
9. Tremlett, J.G. (1964) Observations on the pathology of lesions associated with Stephanofilaria dinniki; Round, 1964, from the black rhinoceros (Diceros bicornis) Journ. Helminth 38: 171-174.
10. Young (1967) The black rhinoceros (A literature survey) Unpublished seminar. University of Pretoria Mimeo.